

# Posterior Shoulder Dislocation Associated With Fracture Of The Acromion - A Case Report And Review Of Literature

M Zertalis, D Shukla, R Botchu

## Citation

M Zertalis, D Shukla, R Botchu. *Posterior Shoulder Dislocation Associated With Fracture Of The Acromion - A Case Report And Review Of Literature*. The Internet Journal of Radiology. 2014 Volume 17 Number 1.

## Abstract

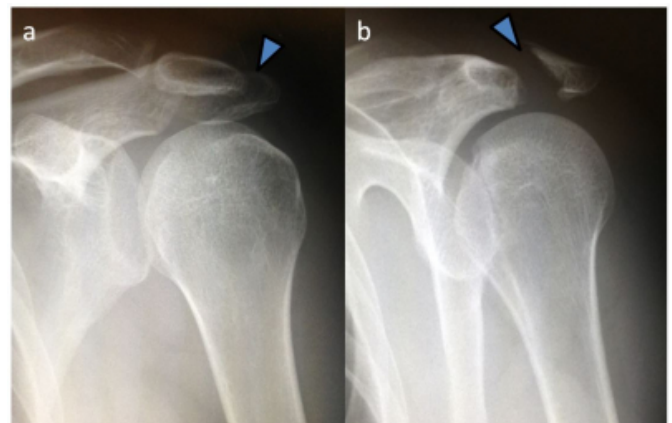
Posterior shoulder dislocation associated with fracture of the acromion is a rare injury with only three cases published in literature. Up to 79% of posterior shoulder dislocations can be missed with 65% of patients having associated complications. We present a case of posterior shoulder dislocation associated with fracture of the acromion and describe the mechanism of injury, diagnosis, and management.

## CASE REPORT

28-year-old male presented to the Emergency Department intoxicated, with pain localised over the left shoulder following a fall. The patient had sustained a direct impact to the anterior aspect of the left shoulder. On clinical examination, there was generalised tenderness over the left shoulder with reduced range of movement. Antero-posterior radiographs revealed a displaced transverse acromion fracture and a posterior shoulder dislocation that was not initially detected by the Emergency Department physician. (Figure 1). The patient was referred the on call orthopaedic team and the dislocation was reduced under sedation in the Emergency Department. He was investigated further with cross-sectional imaging and MR revealed a glenohumeral hemarthrosis, and reverse Hill Sach's lesion with a reverse Bankart's lesion. The rotator cuff was intact. There was a displaced fracture of acromion with marked osseous and soft tissue oedema (Figures 2 & 3). The patient was initially managed conservatively with sling immobilisation and physiotherapy for four weeks. Unfortunately, the patient was lost to follow-up.

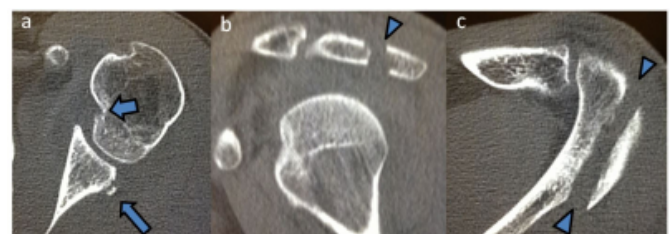## Figure 1

AP and oblique radiographs of shoulder demonstrating posterior dislocation of shoulder and displaced fracture of acromion (arrow head).



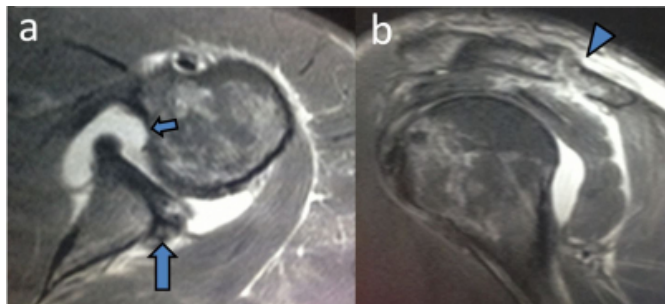
## Figure 2

Axial (a), Sagittal (b) and axial (c) CT showing reverse Hill Sach's lesion (arrow), reverse Bankart's lesion and displaced fracture of acromion (arrow head).



**Figure 3**

PDFS(Proton density fat suppressed) axial(a) and sagittal(b) showing reverse Hill Sach's lesion (small arrow), reverse Bankart's lesion ( long arrow) and fracture of acromion( arrow head).



**DISCUSSION**

Posterior shoulder dislocations account for 2-5% of shoulder dislocations and in up to 79% of cases the diagnosis is missed with detrimental consequences to a patient's functional outcome<sup>1-4</sup>. The three most common causes of posterior shoulder dislocation include a fall on the outstretched arm, a direct blow to the anterior aspect of the shoulder during an epileptic seizure, electrocution or ECT (electroconvulsive therapy <sup>1-6</sup>. Posterior dislocation of the shoulder is four times more common in males with up to 65% of patients having associated injuries which include fractures of the humeral neck (18.5%), lesser (14.3%) and greater (7.8%) tuberosities. Reverse Hill-Sachs lesion (29%) and rotator cuff tear (2%) are also noted in some cases<sup>1</sup>.

Acromion fractures account for 9% of all scapula fractures, comprising less than 1% of all adult fractures<sup>7, 8</sup>. Kuhn described three types of acromion fractures based on the degree of displacement and reduction of the subacromial space<sup>7</sup>. Type I fractures are non-displaced or minimally displaced. Type II fractures are displaced but do not compromise the subacromial space, and Type III fractures are displaced with reduction in the subacromial space<sup>7</sup>.

Posterior shoulder dislocation associated with fracture of the acromion is a rare injury with only three case reports published to date<sup>2-4</sup>. One case described involved a 31 year-old pedestrian who was hit by a car and fell on the ground sustaining a direct blow to the anterior aspect of his shoulder<sup>2</sup>. The posterior dislocation was initially missed. The acromion fracture was undisplaced and the patient was managed conservatively with no complications.

In a similar case, a 14 year-old boy fell from a motorcycle directly on to his left shoulder. As with the previous case,

the undisplaced acromion fracture was managed conservatively with good results<sup>3</sup>. In the third case, a 37 year-old male fell from his bicycle on to his outstretched hand subsequently landing on to his left shoulder. The posterior dislocation was missed and the displaced acromion fracture was managed with open reduction and internal fixation using a low-profile AO-type calcaneal plate. Although the patient achieved full range of movement and returned to work, radiographic union was not evident at three months.

In the first two cases, the proposed mechanism of injury, which also applies in our case, is a direct blow to the anterior aspect of the shoulder resulting in a posterior dislocation of the humerus, followed by movement of the humeral head posterior-superiorly and subsequent impact with the acromion causing a fracture. In the third case, the posterior dislocation was the result of a fall on the outstretched hand with the subsequent direct impact on the shoulder causing the acromion fracture. Isolated acromion fractures are uncommon. Associated injuries include proximal humeral fractures, rib fractures, pneumothorax, head injury, pelvic fractures, brachial plexus injuries and facial fractures<sup>7</sup>.

**CONCLUSION**

Posterior shoulder dislocation associated with fracture of the acromion is a rare injury. We present this case report to emphasise the high index of suspicion necessary for identifying posterior shoulder dislocations in a patient with a history of high energy force to the anterior aspect of the internally rotated, adducted shoulder, as well as to highlight the high incidence of their associated complications<sup>1, 2, and 9</sup>. The aforementioned concomitant injuries may distract the Emergency Department physician leading to a misdiagnosis of posterior shoulder dislocation. In addition to the antero-posterior view, scapular Y and axillary views are necessary, and where the diagnosis remains in doubt a computed tomography (CT) scan is indicated<sup>1, 2</sup>.

**References**

1. Rouleau DM, and Hebert-Davies J. Incidence of Associated Injury in Posterior Shoulder Dislocation: Systematic Review of the Literature J Orthop Trauma 2012;26:246–251
2. Reddy VRM. Posterior shoulder dislocation associated with acromion fracture. Eur J Orthop Surg Traumatol (2009) 19:333–336
3. Nakae H, Endo S (1996) Traumatic posterior dislocation of the shoulder with fracture of the acromion in a child. Arch Orthop Trauma Surg 115(3–4):238–239
4. Goodrich JA, Crosland E, Pye J (1998) Acromion fracture associated with posterior shoulder dislocation. J Orthop

## **Posterior Shoulder Dislocation Associated With Fracture Of The Acromion - A Case Report And Review Of Literature**

---

Trauma 12(7):521–523

5. Perron AD, Jones RL (2000) Posterior shoulder dislocation: avoiding a missed diagnosis. *Am J Emerg Med* 18(2):189–191

6. Galanakis IA, Kontakis GM, Steriopoulos KA (1997) Posterior dislocation of the shoulder associated with fracture of humeral anatomic neck. *J Trauma* 42(6):1176–1178

7. Kuhn JE, Blasler RB, Carpenter JE. Fractures of the

acromion process: a proposed classification system. *J Orthop Trauma* 1994; 8: 6-13

8. Ada JR, Miller ME. Scapular fractures. Analysis of 113 cases. *Clin Orthop Relat Res.* 1991;(269):174-80.

9. Kowalsky MS, Levine WN. Traumatic posterior glenohumeral dislocation: classification, pathoanatomy, diagnosis, and treatment. *Orthop Clin North Am.* 2008;39:519–533, viii.

**Author Information**

**Marios Zertalis, BMedSci (Hons); MBBS (Hons) Senior House Officer**

Department of Trauma & Orthopaedics Kettering General Hospital

Kettering, Northamptonshire, UK

Marios.zertalis@doctors.org.uk

**Divyang Shukla, MS, DNB MCh, FRCS Consultant Trauma & Orthopaedics**

Department of Trauma & Orthopaedics Kettering General Hospital

Kettering, Northamptonshire, UK

**Rajesh Botchu, MBBS, MS (Orth), MRCSEd, MRCSI, FRCR Consultant Radiologist**

Department of Radiology Kettering General Hospital

Kettering, Northamptonshire, UK

drrajeshb@gmail.com