

Malignant Melanoma Presenting As Inguinal Nodal Metastasis With Unknown Primary: A Rare Presentation

Suhani, K Meena, S Ali, L Aggarwal, S Thomas

Citation

Suhani, K Meena, S Ali, L Aggarwal, S Thomas. *Malignant Melanoma Presenting As Inguinal Nodal Metastasis With Unknown Primary: A Rare Presentation*. The Internet Journal of Surgery. 2013 Volume 30 Number 2.

Abstract

Melanoma with unknown primary (MUP) accounts for approximately 1% to 8% of all melanomas and was described first in 1952. We report a case of a middle aged lady with a painless, progressively increasing swelling of the inguinal region, which on investigations came out to be malignant melanoma metastatic to inguinal nodes, without clinical or radiological evidence of a known primary. The patient was treated with a radical ilioinguinal lymph node dissection followed by postoperative chemoradiation. The importance of presenting this paper is to highlight the rare presence of malignant melanoma metastatic to lymph nodes with an unknown primary, and the need to aggressively treat these patients as they have a prognosis comparable to stage III disease.

INTRODUCTION

Melanoma with unknown primary (MUP) accounts for approximately 1% to 8% of all melanomas and was described first in 1952.¹ Contemporary criteria for the diagnosis include 1) metastatic melanoma confirmed clinically, histologically, and immune-histochemically; 2) the absence of a previous cutaneous tumor, pigmented or not, destroyed or excised without histologic examination; and 3) exclusion of unusual primary sites, including urogenital, otolaryngologic, or ophthalmologic sites.² The relatively favorable long-term survival of patients with MUP in previously conducted studies have suggested that patients with MUP have a natural history that is similar to (if not better than) the survival of many patients with stage III disease. Therefore, patients with MUP should be treated with an aggressive surgical approach with curative intent and should be considered for stage III adjuvant therapy protocols.

CASE REPORT

We report the case of a middle-aged lady who presented with a painless progressively increasing swelling in her left inguinal region for the past two years. There was no history of any cutaneous lesion, previous skin biopsy, urinary or bowel complaints, visual disturbances, chronic headache or seizures. She was on treatment for hypertension, hypothyroidism and anxiety disorder for the past eight years. On examination, there was a 10 x 8cm lump in the left

inguinal region. It had bosselated surface with bluish hue and limited side to side mobility (fig. 1). The rest of the examination including proctoscopy, colposcopy, otorhinological and ophthalmologic examinations was unremarkable. CECT of the abdomen revealed a 95 x 90 x 75mm necrotic lymph nodal mass having solid and cystic areas in the left inguinal region in front of the left external iliac and femoral vessels (fig. 2). FNAC from the mass revealed it to be a malignant melanoma. Whole body PET CT scan revealed FDG avidity in the left inguinal region only. A diagnosis of malignant melanoma of the left inguinal lymph nodal region with an unknown primary was made and the patient was taken up for excision of tumour mass with complete ilioinguinal lymph node dissection. Intraoperatively, there was a lymph nodal mass measuring 8 x 8cm in the left superficial inguinal lymph nodal basin with multiple lymph nodes along the external iliac artery up to the common iliac bifurcation (fig. 3). Postoperatively, the patient had an unremarkable recovery except for persistent lymphorrhea in the drain, which was managed conservatively. The HPE revealed it to be malignant melanoma (HMB 45 positive) metastatic to inguinal and pelvic lymph nodes. Postoperatively, the patient had an uneventful recovery and was started on dacarbazine, vincristine and cisplatin based chemotherapy along with radiotherapy to the regional nodal basin.

Figure 1

Clinical picture: Bosselated lump in the inguinal region

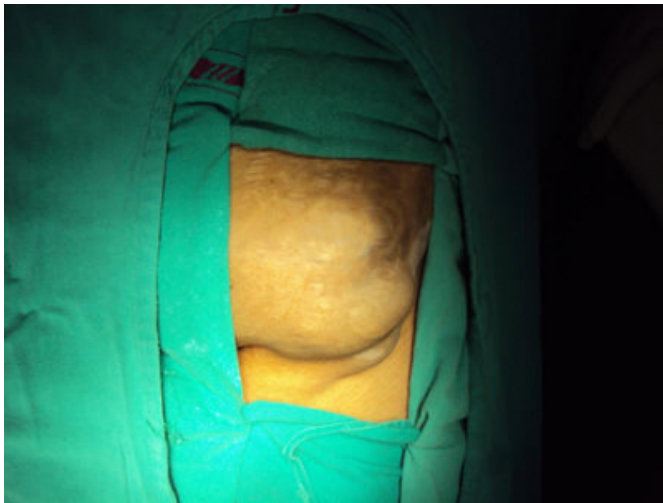


Figure 2

CECT showing an inguinal mass anterior to the iliac vessels.

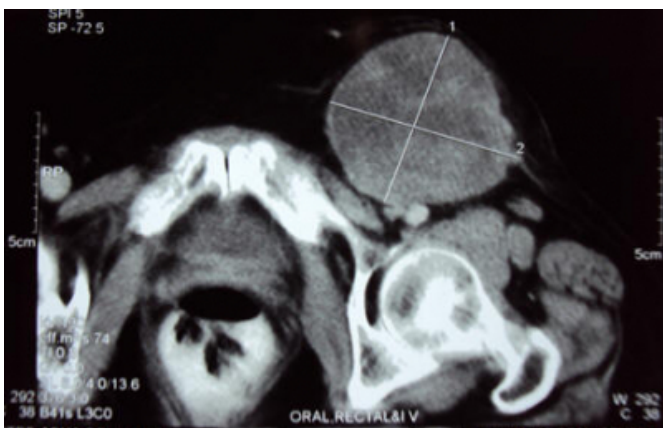
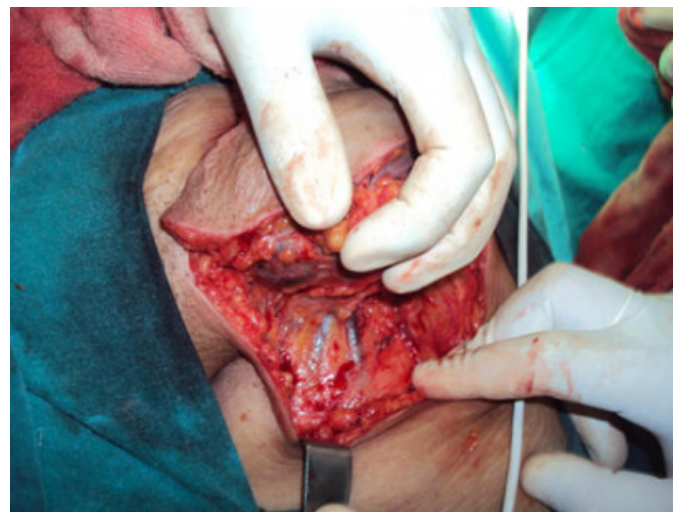
Figure 3

Intraoperative picture during ilioinguinal lymph node dissection showing superficial lymphadenectomy



DISCUSSION

Metastatic unknown primary occurs in less than 8% of all melanomas, with the axillary lymph nodal basin most commonly involved. Although the true etiology of an MUP is unknown, several explanations have been suggested and include 1) a concurrent, unrecognized melanoma; 2) a previously excised melanoma that was misdiagnosed either clinically or pathologically; 3) an antecedent, unrecognized, spontaneously regressed primary melanoma; and 4) the de novo malignant transformation of an aberrant melanocyte within a lymph node.³ The previously noted clinical and histologic observations made during the previous three decades support the disappearance of a primary lesion as a result of spontaneous regression, which still remains a plausible explanation for MUP.⁴ In accordance with this explanation, it has been suggested that the immunologic response that results in primary tumor regression somehow may contribute to the more favorable outcomes seen in patients with MUP.⁵ The improved outcomes associated with MUP also support the premise that MUP may represent a primary process originating from an aberrant melanocyte within a lymph node (locally advanced disease) rather than a regionally metastatic process. Metastatic melanoma should be considered in the differential diagnosis of all patients who present with a malignancy of unknown origin, particularly when lymph nodes are the primary presenting site. Fine-needle aspiration or core biopsy of the lymph node lesion usually is adequate for tissue diagnosis, but immunohistochemical studies (i.e., immunoreactivity for S-100, vimentin, and HMB-45) and electron microscopy

studies looking for melanosomes or premelanosomes also may be obtained in the event of equivocal findings.⁶ Current recommendations for the evaluation of these patients include a review of previous skin biopsy specimens, full skin evaluation, brain imaging (CT or MRI), and CT imaging of the chest/abdomen and pelvis to rule out distant metastatic disease. Additional recommendations include otorhinolaryngologic examinations to look for metastases to the head and neck region and proctoscopy and gynecologic examinations for patients with inguinal lymph node metastases.⁷ Ophthalmologic examinations should be reserved for patients who have MUP with visceral metastases, primarily of the liver. The relatively favorable long-term survival of patients with MUP supports the belief that, in the context of regional lymph node disease, MUP constitutes a manifestation of stage III disease rather than stage IV (M1a) distant lymph node disease. Therefore, patients who have metastatic melanoma in a regional node in the absence of a known primary site should undergo completion lymph node dissection. These patients also should be considered for adjuvant treatment trials that were designed for patients with stage III disease.⁸

CONCLUSION

Malignant melanoma with unknown primary is a rare entity that should be considered in the differential diagnosis of all patients presenting with malignant lymphadenopathy with an

unknown primary. Since prognostically such tumours (stage III) fare better than similar tumors with a known primary site (stage IV), an aggressive management with complete locoregional lymphadenectomy followed by adjuvant chemotherapy is warranted.

References

- 1) Pack GT, Gerber DM, Scharnagel IM: End results in the treatment of malignant melanoma; a report of 1190 cases. *Ann Surg*; 1952; 136: 905-911.
- 2) DasGupta T, Bowden L, Berg JW: Malignant melanoma of unknown primary origin. *Surg Gynecol Obstet*; 1963; 117: 341-345.
- 3) Anbari KK, Schuchter LM, Bucky LP, et al.: Melanoma of unknown primary site: presentation, treatment, and prognosis — A single institution study. *Cancer*; 1997; 79: 1816-1821.
- 4) Smith JL Jr., Stehlin JS Jr.: Spontaneous regression of primary malignant melanomas with regional metastases. *Cancer*; 1965; 18: 1399-415.
- 5) Baab GH, McBride CM: Malignant melanoma: the patient with an unknown site of primary origin. *Arch Surg*; 1975; 110: 896-900.
- 6) Chorost MI, Lee MC, Yeoh CB, et al.: Unknown primary. *J Surg Oncol*; 2004; 87: 191-203.
- 7) Schlagenhauff B, Stroebel W, Ellwanger U, et al.: Metastatic melanoma of unknown primary origin shows prognostic similarities to regional metastatic melanoma: recommendations for initial staging examinations. *Cancer*; 1997; 80: 60-65.
- 8) Cormier JN, Xing Y, Feng L, Huang X, Davidson L, Gershenwald JE, Lee JE, Mansfield PF, Ross MI: Metastatic melanoma to lymph nodes in patients with unknown primary sites. *Cancer*; 2006; 106: 2012-2020.

Author Information

Suhani, Senior Resident

Lady Hardinge Medical College (LHMC)

New Delhi, India

drsuhani@gmail.com

Kusum Meena, Assistant Professor of Surgery

Lady Hardinge Medical College (LHMC)

New Delhi, India

Shadan Ali, Assistant Professor of Surgery

Lady Hardinge Medical College (LHMC)

New Delhi, India

Lalit Aggarwal, Assistant Professor of Surgery

Lady Hardinge Medical College (LHMC)

New Delhi, India

Shaji Thomas, Director Professor & Surgical Unit Head

Lady Hardinge Medical College (LHMC)

New Delhi, India