

A rare post-ERCP complication: a case report of pneumoperitoneum, pneumo-retroperitoneum, and surgical emphysema following unsuccessful ERCP.

H SAMEI, R ABDEL BAKY, A AI DOWAIS

Citation

H SAMEI, R ABDEL BAKY, A AI DOWAIS. *A rare post-ERCP complication: a case report of pneumoperitoneum, pneumo-retroperitoneum, and surgical emphysema following unsuccessful ERCP.*. The Internet Journal of Surgery. 2008 Volume 21 Number 1.

Abstract

Endoscopic retrograde cholangiopancreatography (ERCP) is an invasive procedure performed to diagnose and treat pancreatic and biliary diseases. In about 5%-10% of patients it causes adverse events. Pancreatitis is the most common complication; duodenal perforation, hemorrhage and cholangitis are less frequent. Duodenal perforation is an infrequent complication of ERCP, usually associated with sphincterotomy; it may be asymptomatic, passing un-noticed, or causing abdominal symptoms. The management of symptomatic perforation should be initially conservative including bowel rest, nasogastric suction, hydration and antibiotics. These patients must be carefully observed, because 20%-40% may require surgical treatment. Surgery is recommended in patients with persistent biliary obstruction, cholangitis, a septic status and those whose symptoms do not improve after a brief period of non-operative management. Here we present a case of post-ERCP pneumoperitoneum, pneumo-retroperitoneum, and surgical emphysema treated successfully with operative intervention but with non-visualized perforation.

INTRODUCTION

Endoscopic retrograde cholangiopancreatography (ERCP) and sphincterotomy are increasingly used in the diagnosis and management of patients with pancreatico-biliary diseases, carrying a lower morbidity and mortality rate than surgery[1]. This invasive procedure has been proven to be a safe and effective method for diagnosis and treatment of biliary and pancreatic disorders, with a very low rate of complications even in the very old (> 80 years old) patients, despite the higher prevalence of co-morbidities[2,3].

Major complications of ERCP include pancreatitis, hemorrhage, cholangitis, and duodenal perforation[4,5]. Pneumoperitoneum occurring after ERCP is usually a sinister sign of bowel or ductal perforation [6, 7].

Here we present a rare case of post ERCP pneumoperitoneum, pneumo-retroperitoneum and surgical emphysema which was treated successfully with surgical intervention.

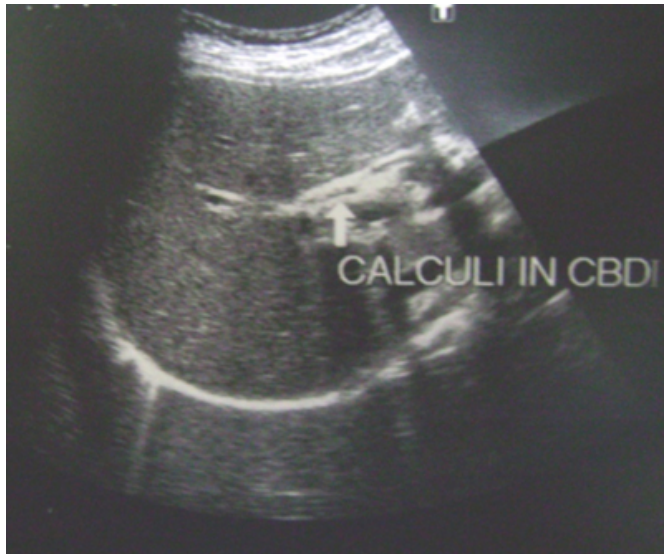
CASE REPORT

A 32-year-old lady with calculous obstructive jaundice was admitted through ER to King Khalid Hospital in Najran, Saudi Arabia. She complained of recurrent right

hypochondrial pain, diagnosed as gall stone disease and was prepared for elective laparoscopic cholecystectomy but she came with a severe attack of pain accompanied by jaundice before the planned date of surgery. Laboratory investigations showed elevated bilirubin levels, both total and direct, 58umol/L and 39.8umol/L, respectively (normal levels 0.0-18.8 and 0.0-4.3), ALP 163 IU/L (normal: 32-92), AST 687 IU/L (normal: 7-45), ALT 717 IU/L (normal: 0-40) and GGT 250 (normal: 7-64). US showed an obstructive stone in a non-dilated CBD and multiple small gall stones (Fig. 1).

Figure 1

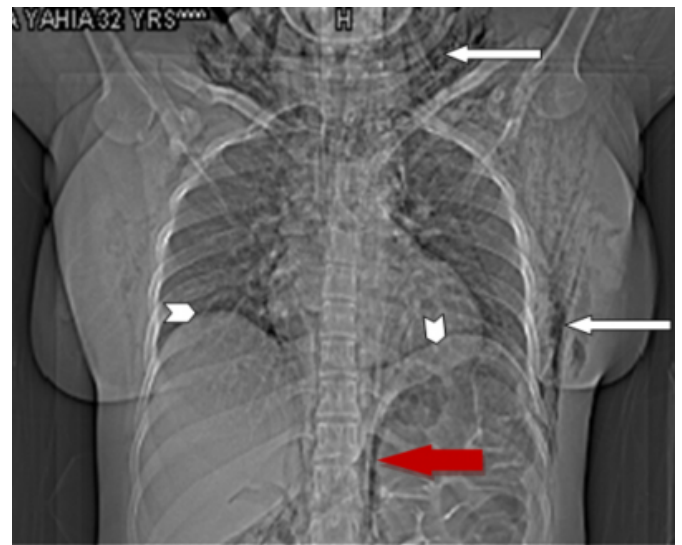
Fig. 1: US showing CBD stone



The patient was prepared for ERCP which was difficult with repeated cannulation of pancreatic duct and pre-cut papillotomy tried with failure of cannulation of CBD. So the procedure ended. Next day, the patient developed surgical emphysema extending to the neck with upper abdominal pain and self-limited pancreatitis with an amylase level of 2375, reduced to normal value (365) after 3 days. Urgent CT was done and revealed free air under the diaphragm, para-spinal air, and surgical emphysema of upper abdomen and chest with extension to the neck but no leak of contrast from the duodenum and no intra-abdominal fluid collection (Fig.2).

Figure 2

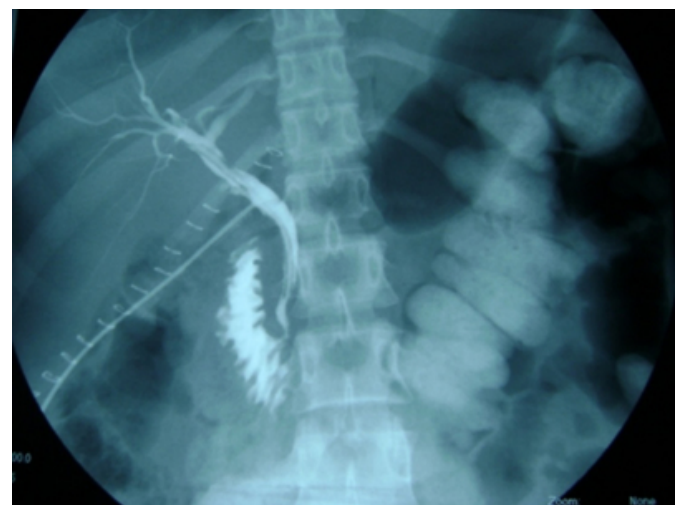
Fig. 2: Surgical emphysema (arrows), free air under the diaphragm (arrow heads) and para-spinal air (red arrow)



The diagnosis of duodenal or ductal perforation was assumed and no definite perforation was seen during laparotomy. Cholecystectomy was done after cholangiography, the CBD was explored, cleared of stones and a T-tube was inserted with a tube drain in Morrison's pouch. The postoperative course was uneventful; surgical emphysema resolved gradually. T-tube cholangiography was done on the 7th postoperative day and the CBD was clear with free flow of dye to the duodenum (Fig. 3).

Figure 3

Fig. 3: T-tube cholangioram showing clear CBD & free flow of dye into the duodenum



The T-tube was clamped overnight with no complaint and then removed next morning, and the patient was discharged home on the 10th postoperative day in a good condition.

DISCUSSION

Major complications of ERCP include pancreatitis, hemorrhage, cholangitis, and duodenal perforation[4,5]. The occurrence of free air in the peritoneal cavity post ERCP is usually the result of duodenal or ductal perforation related to therapeutic ERCP and sphincterotomy[4,6-8]. Given that the overall incidence of duodenal and common bile duct perforations is about 1% and most of these cases (80%) have retroperitoneal perforations causing pneumoretroperitoneum, it becomes apparent that post-ERCP pneumoperitoneum is a very rare complication[4].

The prognosis depends on early recognition and treatment of the perforation and the patient's comorbidities. Overall mortality is around 7%-16%, although in more recent series a decrease in mortality has been described[9]. Retroduodenal perforation is determined by the radiologic evidence of air or contrast in the retroperitoneal space; therefore, CT is the most sensitive test[10]. The amount of air does not correlate with the severity of the complication or with the necessity of surgical treatment, because this only reflects the degree of manipulation after the perforation occurred. Up to 29% of asymptomatic patients can have retroperitoneal air revealed on a CT scan performed 24 hours after ERCP, presumably related to air insufflation during endoscopy, suggesting that presence of retroperitoneal air in the absence of symptoms is not indicative of perforation; in such cases only observation is required[11]. The management of perforation should be conservative initially and should include bowel rest, nasogastric suction, hydration and antibiotics. These patients must be carefully observed, because 20%-40% may require surgical treatment. Surgery is recommended in patients with persistent biliary obstruction (as in our patient with failure of removal of the CBD stone), cholangitis, a septic status and those whose symptoms do not improve after a brief period of non-operative management

CONCLUSION

Pneumoperitoneum, pneumo-retroperitoneum and surgical

emphysema are rare complications of ERCP that can occur due to minute duodenal perforation after pre-cut papillotomy that could be managed conservatively initially, with careful observation. Surgical treatment should not be delayed in cases of persistent biliary obstruction or in septic states.

References

1. Carr-Locke DL. Therapeutic role of ERCP in the management of suspected common bile duct stones. *Gastrointest Endosc* 2002; 56: S170-S174
2. Koklu S, Parlak E, Yuksel O, Sahin B. Endoscopic retrograde cholangiopancreatography in the elderly: a prospective and comparative study. *Age Ageing* 2005; 34: 572-577
3. Thomopoulos KC, Vagenas K, Assimakopoulos SF, Giannikoulis C, Arvaniti V, Pagoni N, Nikolopoulou VN. Endoscopic retrograde cholangiopancreatography is a safe and effective method for diagnosis and treatment of biliary and pancreatic disorders in octogenarians. *Acta Gastroenterol Belg* 2007; 70: 199-202
4. Loperfido S, Angelini G, Benedetti G, Chilovi F, Costan F, De Berardinis F, De Bernardin M, Ederle A, Fina P, Fratton A. Major early complications from diagnostic and therapeutic ERCP: a prospective multicenter study. *Gastrointest Endosc* 1998; 48: 1-10
5. Salminen P, Laine S, Gullichsen R. Severe and fatal complications after ERCP: Analysis of 2555 procedures in a single experienced center. *Surg Endosc* 2007; Epub head of print
6. Baron TH. Complications of endoscopic biliary sphincterotomy: the first cut is the deepest. *Clin Gastroenterol Hepatol* 2004; 2: 968-970
7. Menuck L, Siemers PT. Pneumoperitoneum: importance of right upper quadrant features. *AJR Am J Roentgenol* 1976; 127: 753-756
8. Pannu HK, Fishman EK. Complications of endoscopic retrograde cholangio-pancreatography: spectrum of abnormalities demonstrated with CT. *Radiographics* 2001; 21: 1441-1453
9. Jaime Ruiz-Tovar, Eduardo Lobo, Alfonso Sanjuanbenito, Enrique Martínez-Molina. Pneumoretroperitoneum secondary to duodenal perforation after endoscopic retrograde cholangiopancreatography. *Can J Surg* 2009; 52: 68-9.
10. Petersen S, Henke G, Freitag M, et al. Management of hemorrhage and perforation following endoscopic sphincterotomy. *Zentralbl Chir* 2001; 126: 805-9.
11. Genzlinger JL, MacPhee MS, Fisher JK, et al. Significance of retroperitoneal air after endoscopic retrograde sphincterotomy. *Am J Gastroenterol* 1999; 94: 1267-70.

Author Information

HAMADA SAMEI, MD,MRCS

RAOUF ABDEL BAKY, FRCS

ALI M AI DOWAIS, MD