

Perioperative Management Of Huge Goiter With Compromized Airway

A El-Dawlatly, M Takrouri, A Elbakry, M Ashour, K Kattan, W Hajjar, A Obaid

Citation

A El-Dawlatly, M Takrouri, A Elbakry, M Ashour, K Kattan, W Hajjar, A Obaid. *Perioperative Management Of Huge Goiter With Compromized Airway*. The Internet Journal of Anesthesiology. 2002 Volume 7 Number 2.

Abstract

Goiter is a known risk factor for difficult airway management. We report the anesthetic management of a case of huge multinodular goiter with compromised airway. When thyroid enlargement is accompanied by airway deformity, it presents an aggravating factor for difficult direct laryngoscopy and difficult tracheal intubation. Under similar situations where the trachea is compressed and markedly shifted to one side, and whenever possible, airway access under local anesthesia constitutes better alternative to failed fiberoptic intubation.

CASE REPORT

A 46-year-old male patient who was not known to have any medical illness, presented with history of diffuse neck swelling noted 6 yr ago. The swelling was increasing gradually in size and was associated with dyspnea especially with neck flexion. There was no history of dysphagia, pain, change of voice or any history suggestive of hyper or hypothyroidism. The patient was fully investigated in another hospital and the diagnosis of huge multinodular goiter was established for which he was taken to the operating theater for thyroidectomy. The procedure was aborted due to unsuccessful tracheal intubation. The patient was referred to our hospital for further management. On examination, he looked well, not in distress or sweating. His body weight 107 kg, heart rate 80 beats/min and blood pressure 130/80 mmHg. Neck examination showed a huge swelling about 10x11 cm, moving with swallowing, firm in consistency, nodular surface, not tender with normal overlying skin (Fig 1). Plain neck x-ray showed huge mass involving the pretracheal and prevertebral areas (Fig 2). Percussion note was dull over the upper sternum with no systolic bruit over the lump. Trachea was displaced to the right side. No neck veins engorgement or cervical lymphadenopathy.

Figure 1

Figure 1: Huge goiter 10x11cm

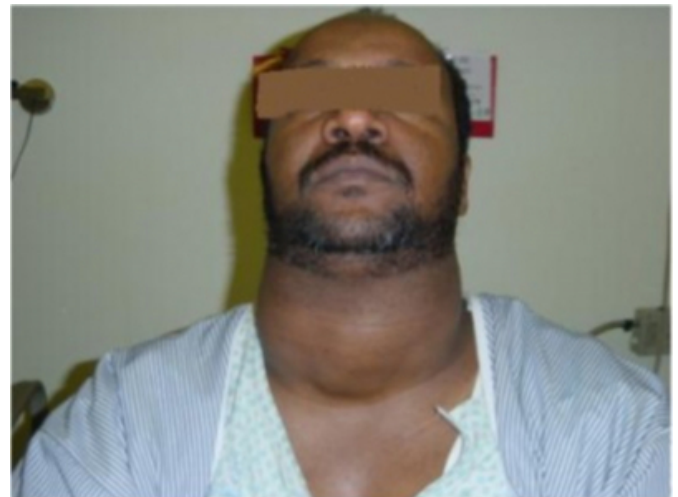
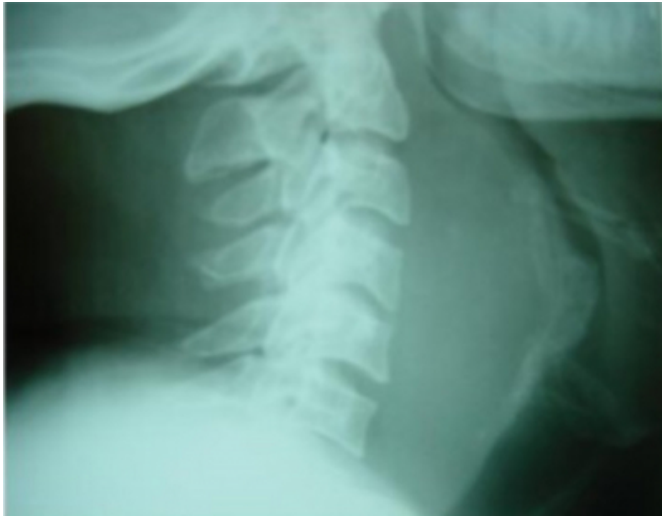
Figure 2

Figure 2: Lateral neck x-ray shows goiter extension to pretracheal and prevertebral areas.



Cardiovascular system examination revealed no added sounds or murmurs. Chest examination showed bilateral good air entry with no added sounds. Chest x-ray showed huge goiter with markedly shifted trachea to the right side (Fig 3). Abdominal examination showed soft and lax abdomen with audible bowel sounds. Laboratory investigations including thyroid function tests were within normal ranges. An ultrasound was done which was suggestive of multinodular goiter. CT scan showed 10x11 cm huge mass involving the pretracheal and prevertebral areas extending to the superior mediastinum with small retrosternal extension (Fig 4). There was no tracheal erosion or infiltration. Fine needle biopsy showed multinodular goiter. Indirect laryngoscopy was difficult to perform. However, fiberoptic laryngoscopy was done and revealed normal vocal cords. Duplex examination was done that showed bilateral normal extracranial carotid arteries with no evidence of compression caused by the goiter. The patient was scheduled to undergo total thyroidectomy under general anesthesia. Airway assessment revealed Mallampati IV with limited neck movement. The plan was to use awake fiberoptic bronchoscopy (FOB) to facilitate endotracheal intubation.

Figure 3

Figure 3: Chest x-ray shows huge goiter with right sided tracheal deviation.

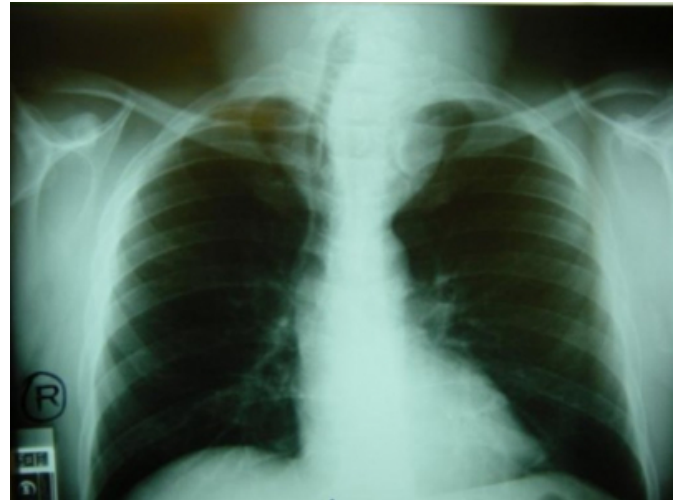
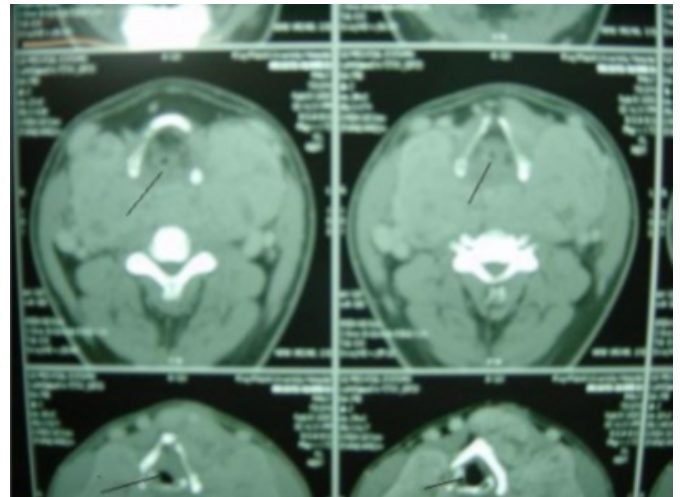


Figure 4

Figure 4: CT scan shows compressed pharyngeal inlet with black line pointed at the pin point pharyngeal inlet.



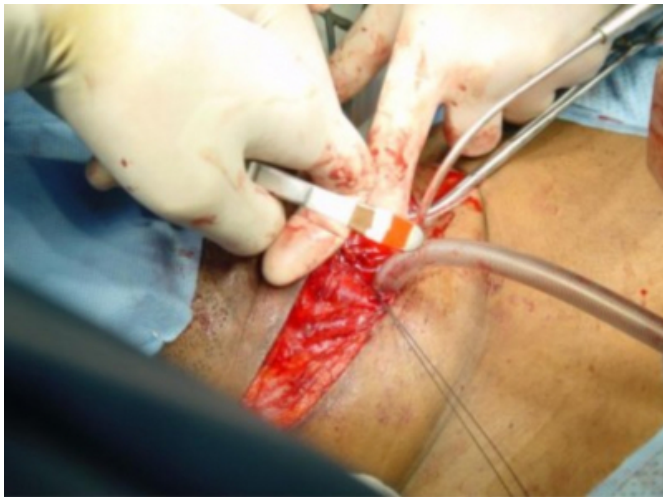Premedication was achieved with oral lorazepam 2mg one night before surgery and 2 mg 2 hours prior to surgery in addition to i.m atropine 0.6 mg 30 minutes before surgery. In the operation theater, the patient was connected to routine monitoring. An i.v line was established and intermittent boluses of midazolam and fentanyl were given.

The pharyngolaryngeal structures were sprayed with 2% lignocaine. The trachea could not be palpated, therefore transtracheal injection of lignocaine was impossible. Repeated attempts of FOB failed and at one stage the patient became hypoxic where the procedure was abandoned and laryngeal mask airway (LMA) was inserted to secure the airway. The operation was postponed. Few days later, a plan

was made to access the airway under local infiltration anesthesia followed by total thyroidectomy. The patient was informed and in the operation theater and under local infiltration with lignocaine 0.5% (100ml), the trachea was accessed and reinforced armored tube was inserted and connected to the ventilator (Fig 5).

Figure 5

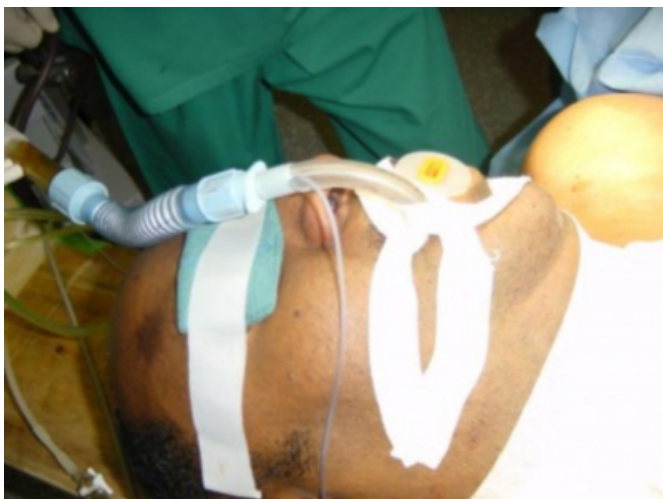Figure 5: Airway access with armored tube.



Propofol 200 mg and fentanyl 100 mcg were given followed by atracurium 40 mg i.v. After total thyroidectomy, direct laryngoscopy and vocal cords visualization was possible and the trachea was intubated using 7.5mm armored endotracheal tube (ETT) with simultaneous removal of the ETT at the tracheostomy stoma (TS) (Fig 6). The TS was then closed and upon completion of surgery and i.v atropine/neostigmine for reversal of muscle relaxant, the trachea was extubated.

Figure 6

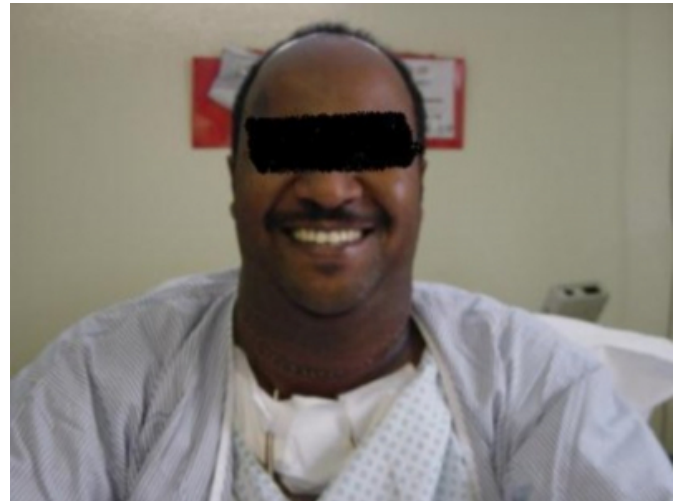Figure 6: Endotracheal intubation with armored tube.



Postoperatively the patient made an uneventful recovery (Fig 7).

Figure 7

Figure 7: Patient at the postoperative period.



DISCUSSION

Airway crisis is an ever-present risk of general anesthesia in goiter with compromised airway. However, the role of an enlarged thyroid in complicating airway management remains controversial (1). Goiter as risk factor for difficult airway is not widely studied. In one study it was found that when thyroid enlargement is accompanied by airway deformity, it constitutes an aggravating factor in difficulty in direct laryngoscopy (2). In the present report fiberoptic intubation has failed to accomplish ETT. However, in other reports awake FOB intubation was successful in patients with massive multinodular goiter (3, 4).

In a report of two cases of difficult airway, it was suggested that the use of intubating LMA can facilitate blind tracheal intubation when fiberoptic intubation is unsuccessful (5). In our case the LMA has made ventilation easy when failed in FOB was experienced during the first attempts. It was recommended that the LMA is useful in the management of stridor (6). Emergency intubation with Combitube was successfully used in two cases of difficult airway management (7). In the present report, securing the airway was of prime importance before doing the surgery. The trachea was compressed and markedly pushed to one side which has contemplated to the difficulty in intubating the trachea and at one stage to difficult ventilation. We don't think that the use of Combitube would have solved the problem in this case due to marked shift of the trachea to one side. Moreover, the use of LMA though at one stage has

made ventilation possible but it was difficult to maintain patent airway using it especially with prolonged surgery and manipulations on the trachea. We believe that airway access under local anesthesia in the present case was highly indicated.

CONCLUSION

In conclusion, when thyroid enlargement is accompanied by airway deformity, it presents an aggravating factor for difficult direct laryngoscopy and difficult tracheal intubation. Under similar situations and whenever possible airway access under local anesthesia constitutes better alternative to failed fiberoptic intubation.

CORRESPONDENCE TO

Abdelazeem El-Dawlatly dawlatly@ksu.edu.sa

References

1. Murrin KR. Intubation procedure and causes of difficult intubation. In: Latta IP, Rosen M, eds. Difficulties in tracheal intubation. London: Bailliere Tindal, 1985: 75-89.
2. Voyagis GS and Kyriakis KP. The effect of goiter on endotracheal intubation. *Anesth Analg* 1997; 84:611-2.
3. Chakera A, van Heerden PV and van der Schaaf A. Elective awake intubation in a patient with massive multinodular goiter presenting for radioiodine treatment. *Anaesth Intensive Care* 2002; 30(2):236-9.
4. Hariprasad M and Smurthwaite GJ. Management of a known difficult airway in a morbidly obese patient with gross supraglottic oedema secondary to thyroid disease. *Br J Anaesth* 2002; 89(6):927-30.
5. Watson NC, Hokanson M, Maltby JR and Todesco JM. The intubating laryngeal mask airway in failed fiberoptic intubation. *Can J Anaesth* 1999; 46(4):376-8.
6. Brimacombe J. The laryngeal mask airway-use in the management of stridor. *Anaesth Intensive Care* 1992; 20(1):117-8.
7. Staudinger T, Tesinsky P, Klappacher G, Brugger S, Rintelen C, Locker G, Weiss K and Frass M. Emergency intubation with the Combitube in two cases of difficult airway management. *Eur J Anaesthesiol* 1995; 12(2):189-93.

Author Information

Abdelazeem A. El-Dawlatly, M.D.

Associate Professor, Department of Anesthesia, College of Medicine, King Saud University

Mohamed S. Takrouri, FFARCSI

Professor of Anesthesia, College of Medicine, King Saud University

Abdulkareem Elbakry, FRCS

Associate Professor, Department of Surgery, College of Medicine, King Saud University

Mahmoud Ashour, FRCS

Professor, Department of Surgery (Division of Thoracic Surgery), College of Medicine, King Saud University

Khalid Kattan, FRCS

Professor, Department of Surgery (Division of Thoracic Surgery), College of Medicine, King Saud University

Waseem Hajjar

Senior Registrar, Department of Surgery (Division of Thoracic Surgery), King Khalid University Hospital

Abdulhakeem Al Obaid

Resident in General Surgery, King Khalid University Hospital