

# An Audit of Percutaneous Gastrostomy in The Cayman Islands

S Cawich, A Mathew, S Mohanty, W Huizinga

## Citation

S Cawich, A Mathew, S Mohanty, W Huizinga. *An Audit of Percutaneous Gastrostomy in The Cayman Islands*. The Internet Journal of Gastroenterology. 2007 Volume 6 Number 2.

## Abstract

Gastrostomy tube placement by the percutaneous endoscopic (PEG) technique is the current method of placing gastrostomy tubes. The technique has been used at the Cayman Islands Hospital for approximately five years. There have been no prior reports on the outcomes of PEG tube placement in this setting since its introduction.

An audit of PEG placement was performed at the Cayman Islands Hospital to determine the outcomes in this setting. The hospital records of all patients who had PEG tube placements were retrospectively examined over 44 months from January 2004 to September 2007.

There were 35 PEG tubes placed in 28 patients during the study period. Three patients experienced PEG specific complications (8.57%), including bleeding (1 patient), aspiration (1 patient) and PEG dislodgment (1 patient). There were no reports of wound infection, perforation, intra-abdominal sepsis or fistula formation. No early mortality was recorded within the post-operative hospitalization period that averaged 3.25 days.

The case volume has increased since the procedure was introduced. Currently, 18 PEG tubes are placed per year with good success and acceptable rates of PEG-specific morbidity.

## INTRODUCTION

The PEG technique was introduced to clinical practice in 1980 (1). PEG has now surpassed the traditional open technique of gastrostomy tube placement because it is accompanied by less morbidity and can be performed without general anaesthesia (2,3,4).

The technique is becoming popular in many Caribbean territories. There have been no prior reports on PEG placement from the Cayman Islands since the first procedure was performed approximately five years ago. We carried out an audit to document the experience with PEG at the Cayman Islands Hospital.

## MATERIALS AND METHODS

The Cayman Islands Hospital is located on the island of Grand Cayman and serves a population of approximately 40,000 persons. At this institution, PEG tubes were usually placed in an operating theatre under intra-venous sedation.

The procedures were all performed by one of four qualified surgeons during this time. The PEG tubes were placed by the standard "pull technique" using commercially available PEG placement kits (Cook® PEG Kit; Wilson-Cook Medical Inc,

North Carolina, USA).

A single dose of intravenous second or third generation cephalosporin was routinely used prior to PEG placement as prophylaxis against infectious morbidity. After complete gastro-duodenoscopy, the stomach was fully insufflated. The ideal entry point on the abdominal wall was selected using endoscopic vision while palpating the abdominal wall. Local anaesthetic was infiltrated at the selected site and a needle and cannula were then inserted into the stomach. The guide wire was threaded through the cannula into the stomach and grasped with endoscopic forceps. The guide wire was pulled into the mouth and the gastrostomy tube was attached to it. The tube was pulled into place by traction on the guidewire across the abdominal wall. After tube position was confirmed endoscopically, the external bumper was sutured to the abdominal wall. The PEG tubes were utilized three hours after the procedure.

The operative log was examined over the period from January 2004 to September 2007 to identify all patients who had PEG tubes placed at the Cayman Islands Hospital. The hospital records were retrieved and data were extracted from the records. The data collected included patient

demographics, indications, complications and mortality.

**RESULTS**

All procedures were performed in the Operating Theatre under intravenous sedation by one of four surgeons. There were 35 PEG tubes placed in 28 patients during the study period. Hospital records were retrieved for all the patients for detailed analysis.

There were 13 males and 20 females, with ages ranging from 49 to 92 years (Mean +/-SD: 77+/-14.4). The operations were performed electively in 32 cases and as emergencies in 3 cases. The indications for PEG placement are outlined in Table 1.

**Figure 1**

Table 1: Indications for PEG at the Cayman Islands Hospital

Indication	Number	Percentage
Cerebro-vascular accidents	16	45.7%
Chronic neurologic disorders	14	40%
• Parkinsons disease	1	
• Alzheimer’s disease	3	
• Multiple Sclerosis	2	
• Multi infarct dementia	2	
• Pseudo-bulbar palsy	4	
• Amyotrophic Lateral Sclerosis	1	
• Mental Retardation	1	
Head and Neck Neoplasms	2	5.7%
• Oesophageal carcinoma with tracheo-oesophageal fistula	1	
• Pharyngeal carcinoma	1	
Anoxic brain injury	2	5.7%
Recurrent aspiration pneumonia	1	2.9%

All attempts at PEG placement were successful. The average operating time was 24 minutes for first time PEG placements and 14 minutes for tube changes. After PEG tube placement, three patients (8.57%) experienced PEG-related morbidity as outlined in Table II.

**Figure 2**

Table 2: Complications of PEG Tube Placement at the Cayman Islands Hospital

	Total n (%)
Total Number of Cases	35
PEG-specific Morbidity	3 (8.6%)
• Aspiration	1 (2.9%)
• PEG Dislodgement	1 (2.9%)
• Bleeding	1 (2.9%)
• Wound Infection	0
• Perforation / Peritonitis	0
• Gastro-Enteric Fistula	0
Mortality at 1 Week	0

One patient with a malignant tracheo-esophageal fistula aspirated during a technically difficult procedure. The patient developed a pneumonia that was successfully treated with antibiotics.

There was one patient with bleeding from the gastric entry point after repeated passes of the PEG needle. The bleeding was controlled with adrenaline injections into the gastric wall under endoscopic vision. There was no significant bleeding post-operatively and the PEG tube was utilized uneventfully.

One patient had inadvertent tube dislodgment at day 10 before the PEG tract was matured. This was detected early and PEG tube was successfully replaced.

There were no deaths recorded during the post-operative hospitalization period. Long term data were not readily available because most patients were discharged from hospital to nursing homes for continued care.

**DISCUSSION**

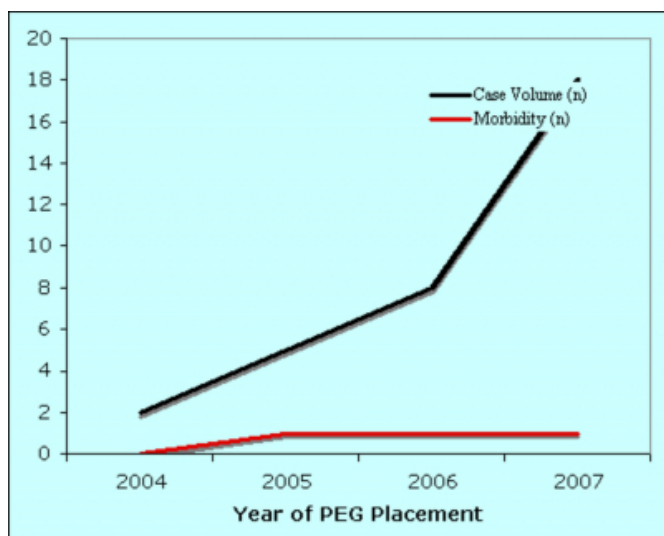
The PEG procedure has been widely embraced by endoscopists because it is easy to perform without the need for general anaesthesia. Additionally, there is less morbidity accompanying PEG than the traditional open gastrostomy (2,3,4).

PEG tubes are commonly used to deliver prolonged enteral nutrition in patients with neurologic dysphagia (5,6,7). Compared to nasogastric tubes, PEG tubes provide superior nutritional efficacy with less complications and lower aspiration rates (6,7,8). Prospective clinical studies have also demonstrated that enteral nutrition via a PEG tube significantly improves the quality of life of these patients (9).

It is estimated that over 200,000 PEG tubes are placed annually in the United States (2). Although it has been in clinical use for almost three decades, the only published report on PEG placement from the English speaking Caribbean originated in Trinidad and Tobago in 2003 (10). In this small series, Bartholomew et al. reported on ten PEG tubes placed over a period of four years (10). During our initial experience with PEG, similar case volumes were encountered. Our case volume has now increased to 18 cases per year during the last year of this audit as outlined in figure 1.

### Figure 3

Figure 1



Most PEG tubes were placed in patients with dysphagia due to cerebro-vascular accidents (46%) and chronic neurologic diseases (40%). Our overall success with PEG placement compares well to the outcomes reported from large volume centres (2,11,12,13,14).

After PEG placement, between 4% and 30% of patients are reported to experience a complication related to the procedure (2,11,12,13,14). The outcomes in this audit were comparable, where 8.6% of patients experienced PEG-specific morbidity. This is reassuring because the patients who require PEG are usually debilitated and cannot tolerate any adverse events.

One patient (2.9%) aspirated during a technically difficult endoscopy due to an underlying oesophageal carcinoma with a tracheo-oesophageal fistula. We recognize that this is higher than the reported rates of aspiration that range between 0.3% and 1.0% of cases (2,11), but these patients are recognized to be at unusually high risk for aspiration

because the fistula does not allow them to protect their airway adequately. And the normal preventative measures, such as minimizing insufflation and completely aspirating gastric contents, would not adequately protect these patients from aspiration.

One patient (2.9%) had bleeding from the gastric entry point after repeated passes of the PEG needle. The bleeding was controlled with adrenaline injections into the gastric wall under endoscopic vision. This is in keeping with reports from larger centres where acute bleeding reportedly occurs in 1-2.5% (2,11,12,13,14) of cases, with less than 0.5% of patients requiring transfusion or laparotomy (2).

We have not encountered any cases of intra-abdominal sepsis or gastro-enteric fistulae which are reported to occur in 0.5-1.3% of cases (2,11). However, we recognize that PEG is still performed at low volumes at this institution, and we remain vigilant for these complications since they may be accompanied by disastrous complications when they do occur.

The principle of antibiotic prophylaxis prior to PEG placement is an accepted practice that is supported by the results of several prospective trials (15,16,17,18). The practice is condoned the European Society of Gastrointestinal Endoscopy (19) and the American Society of Gastrointestinal Endoscopy (20). In keeping with this, we routinely utilized antibiotic prophylaxis with a second or third generation cephalosporin. As a result wound infections were uncommon in our series. Large volume centres report peri-stomal wound infections occurring in 5-30% of patients who have undergone PEG, with less than 1.6% of cases infections requiring aggressive medical and/or surgical treatment (2,11,15,16,17,18).

One patient (2.9%) in our series had accidental tube dislodgment during turning to meet his hygienic needs. Dislodgement is reported to occur in 1.6-4.4% of patients from larger reports (2,11). This is an important complication to look out for because free leak into the peritoneum before the tract matures may lead to intra-abdominal sepsis. Simple maneuvers to reduce the chance of accidental removal include proper fixation to the abdominal wall, restraints or the use of low profile PEG buttons that lay flush with the skin (2,21,22).

The patients who require PEG are usually debilitated and have poor tolerance to the slightest adverse events. The patients' underlying poor medical conditions usually

translate into high mortality shortly after PEG placement. Large reports document 0-2% early mortality shortly after PEG procedures (3,5,14). No early deaths have been reported in this institution, although long-term outcomes were difficult to determine due to inconsistent follow-up data.

## CONCLUSIONS

PEG tubes have been widely embraced by endoscopists. The simplicity, safety and good tolerance of the procedure has prompted a change toward earlier decisions to PEG placement in a large variety of patients with several underlying disorders. A similar trend is occurring in the Cayman Islands where our case volume is steadily increasing.

This report adds to the Caribbean literature regarding this operation. At this institution, PEG tubes are being placed with good success and acceptable rates of morbidity and mortality.

## References

1. Gauderer MWL, Ponsky JL, Izant RJ. Gastrostomy without laparotomy: a percutaneous endoscopic technique. *J Paediatr Surg.* 1980;15:872-5.
2. Lynch CR, Fang JC. Prevention and Management of Complications of Percutaneous Endoscopic Gastrostomy Tubes. *Practical Gastroenterol.* 2004;22:66-76.
3. Grant JP. Comparison of percutaneous endoscopic gastrostomy with Stamm gastrostomy. *Ann Surg.* 1988;207:598-603.
4. Tanker MS, Scheinfeldt BD, Steerman PH, Goldstein M, Robinson G, Levine GM. A prospective randomized study comparing surgical gastrostomy and percutaneous endoscopic gastrostomy. *Gastrointest Endosc.* 1986;32:144.
5. Lo'sera C, Aschlb G, Hebuterne X, et al. ESPEN guidelines on artificial enteral nutrition by percutaneous endoscopic gastrostomy. *Clinical Nutrition.* 2005;24:848-861.
6. Norton B, Homer-Ward M, Donnelly MT, Long RG, Holmes KT. A randomised prospective comparison of percutaneous endoscopic gastrostomy and nasogastric tube feeding after acute dysphagic stroke. *BMJ.* 1996;312:13-16.
7. Park RH, Allison MC, Lang J, Spence E, Morris AJ, Danesh BJ, et al. Randomised comparison of percutaneous endoscopic gastrostomy and nasogastric tube feeding in patients with persisting neurological dysphagia. *BMJ.* 1992;304:1406-9.
8. Mekhail TM, Adelstein DJ, Rybicki LA, Larto MA, Saxton JP, Lavertu P. Enteral nutrition during the treatment of head and neck carcinoma: is a PEG tube preferable to a nasogastric tube? *Cancer.* 2001;91:1785-90.
9. Bannerman E, Pendlebury J, Phillips F, Ghosh S. A cross sectional and longitudinal study of health-related quality of life after PEG. *Eur J Gastroenterol Hepatol.* 2000;12:1101-9.
10. Bartholomew MM, Mohammed SL, Williams DH. Percutaneous Endoscopic Gastrostomy in Trinidad and Tobago. *West Ind Med J.* 2003;52(4):278-280.
11. Larson DE, Burton DD, Schroeder KW, DiMagno EP. Percutaneous endoscopic gastrostomy. Indications, success, complications, and mortality in 314 consecutive patients. *Gastroenterol.* 1987;93:48-52.
12. Lockett MA, Templeton ML, Byrne TK, Norcross ED. Percutaneous endoscopic gastrostomy complications in a tertiary-care center. *Am Surg.* 2002;68:117-120.
13. Mathus-Vliegen LMH, Koning H. PEG and gastrojejunostomy: a critical reappraisal of patient selection, tube function and the feasibility of nutritional support during extended follow-up. *Gastrointest Endosc.* 1999;50:746-54.
14. Abuksis G, Mor M, Segal N, Shemesh I, Plout S, Sulkes J, et al. PEG: high Mortality rates in hospitalized patients. *Am J Gastroenterol.* 2000;95:128-32.
15. Dormann AJ, Wiggingshaus B, Risius H, Kleimann F, Kloppenborg A, Grunewald T, et al. A single dose of ceftriaxone 30 minutes before PEG significantly reduces local and systemic infective complications. *Am J Gastroenterol.* 1999;94:3220-4.
16. Ahmad A, Mouncher A, Abdoolah R, Stenson R, Wright J, Daniels A, et al. Antibiotic prophylaxis for PEG: a prospective, randomised, double-blind trial. *Aliment Pharmacol Ther.* 2003;18:209-15.
17. Prelik G, Grune S, Leser HG, Leubers J, Heldwein W, Machka K, et al. Prospective, randomised, double blind trial of prophylaxis with single dose of co-amoxiclav before PEG. *BMJ.* 1999;319:881-4.
18. Sharma VK, Howden SW. Meta-analysis of randomized, controlled trials of antibiotic prophylaxis for PEG. *Am. J. Gastroenterol.* 2000;95:3133-6.
19. Rey JR, Axon A, Budzyska A, Kruse A, Nowak A. Guidelines of the European Society of Gastrointestinal Endoscopy (E.S.G.E.) antibiotic prophylaxis for gastrointestinal endoscopy. *Endoscopy* 1998;30:318-24.
20. Snyder J, Bratton B. Antimicrobial prophylaxis for gastrointestinal procedures; current practices in North American academic programs. *J Pediatr Gastroenterol Nutr.* 2002;35:564-9.
21. Fouth PG, Talbert GA, Gaines JA, Sanowski RA. The gastrostomy button: a prospective assessment of safety, success, and spectrum of use. *Gastrointest Endosc.* 1989;35:41-4.
22. Gorman RC, Morris JB, Metz CA, Mullen JL, et al. The button jejunostomy for long-term jejunal feeding: results of a prospective randomized trial. *J Parenter Enteral Nutr.* 1993;17:428-31.

**Author Information**

**Shamir O. Cawich, M.B.B.S, D.M.**

Department of Basic Medical Sciences, The University of the West Indies

**Ajit T. Mathew, M.B.B.S., M.S., F.R.C.S.**

The Department of Surgery, Cayman Islands Hospital

**Sanjib K. Mohanty, M.B.B.S.,F.R.C.S.**

The Department of Surgery, Cayman Islands Hospital

**William K.J. Huizinga, M.D., F.R.C.S. (Ed)**

The Department of Surgery, Cayman Islands Hospital