

A new approach for the quantification of asymmetry parameters and shape irregularity of skin tumors

M Messadi, A Bessaid, A Taleb-Ahmed

Citation

M Messadi, A Bessaid, A Taleb-Ahmed. *A new approach for the quantification of asymmetry parameters and shape irregularity of skin tumors*. The Internet Journal of Bioengineering. 2008 Volume 3 Number 2.

Abstract

Malignant melanoma is the most serious of skin tumors. The difficulty encountered in analyzing the images of black skin tumors is in the interpretation of the type of tumor. Several authors have suggested techniques to detect melanomas at an early stage. Most of these methods use one of these attributes (A, B, C, D), which does not allow an accurate evaluation in order to differentiate benign lesions from malignant tumors. In this work, we present a new characterization methodology for tumors using the two attributes (A, B) to provide a better classification. The characterization methodology we developed is validated on real images, and the obtained results are compared to the ones found in literature.

INTRODUCTION

Melanoma has become one of the most dangerous diseases in the world. It is the cancer whose incidence increases mainly in the cutaneous zone, arising from melanocytes, cells that are responsible of pigmentation [C. Serruys 2002]. This disease affects mainly western countries such as Australia (40-60 cases for 100 000), European countries with an average of 10-12 cases for 100 000 inhabitants [C. Serruys 2002]. In this work we are treated most specifically concerned with the necessity to extract specific attributes in order to develop a characterization methodology that enables specialists to take the best possible diagnosis. Our approach relies largely on visual observation of the tumor while dealing with characteristics such as color, texture or form.

Many works have been presented in this field in order to improve the early detection of melanomas. Most of these studies have suggested attributes that do not admit an accurate evaluation to differentiate benign lesions from malignant tumors. Note that Lee [T. Lee et al, 2000] considers only the contour irregularity; such a parameter is a very important factor in the evaluation of a malignant lesion. This algorithm starts with a segmentation method, followed by a smoothing operation done by a fixed grain Gaussian filter and a growing standard deviation. Asymmetry is the second parameter used to differentiate benign lesions from malignant tumors, but the unique utilization of this parameter does not give an accurate evaluation. We must also note that in the work of K.M. Clawson [K.M. Clawson,

et al, 2007], the author uses Fourier descriptors to get the main symmetry axis. However in the work of K.M. Clawson [K.M. Clawson, et al, 2007], the author uses the radial distribution of pigments along the contours to evaluate the asymmetry parameter.

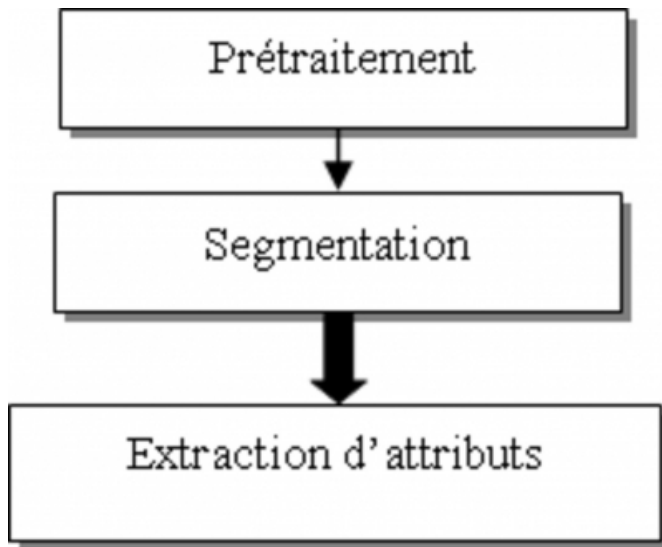
In the first part of this work, we started with a pretreatment sequence applied to different images in order to eliminate the hairs surrounding the tumor as well as a large part of the residual noise. In the second stage, we apply an automatic segmentation, based on Otsu's algorithm, to the filtered image [T.Taouil, et al 2006]. This is an essential phase if we need, to characterize the contour information and, also to, locate the tumor so we can analyze it.

Our contribution is in the stage of "attributes extraction". This stage is most particularly concerned with the necessity to extract specific attributes, and the requirement to set a system capable of detecting the various specific signs to and in melanomas diagnosis. For the characterization, we intend to extract two attributes: The Asymmetry (A) and the shape irregularities of skin tumors (B). In order to characterize these two attributes, we use a hybrid approach which consists in generating a circle whose shape is indicative of pixel distribution inside the lesion. The algorithm we developed is validated on real images, and the obtained results are compared to those found in literature.

The proposed method is illustrated in the following diagram:

Figure 1

Figure 1:Block diagram



PRETREATMENT

Before extracting the specific attributes, it is required to start with a pretreatment stage in order to eliminate hairs and other residual noises. We started by applying a median filter to a color image noise. The latter allows eliminating high frequency noise, it will still remain some noise due to the form of hair traces [H.Hadzli 2005]. Then, we applied the Dull-razor technique [TIM LEE et al, 1997] to images to eliminate these artifacts (hairs). This algorithm is very efficient for images containing hairs. However, it tends to erase the image details and makes the pigmented network blurry.

SEGMENTATION

The quality of interpretation of a color image depends largely on the quality of segmentation which plays a dominant role in image processing and in computer vision. This is an essential phase if we want to characterize the contour information of the lesion, on one side, and locate the tumor in order to analyze it, on the other side. For segmentation, we used the method suggested in the works of T.Taouil [T.Taouil, et al 2006] on a filtered image. The method proposed in this article is based on automatic thresholding (Otsu) and mathematical morphology.

Figure 2

Figure 2: Segmentation results



ATTRIBUTES EXTRACTION

Melanoma tumors are very dangerous lesions. The difficulty in this work is to choose robust parameters describing the lesions to ensure the separation between melanoma and benign lesions. In this case, an early diagnosis of melanomas and mostly the auto-diagnosis is very important. The method used by dermatologists is based on observation criteria such as color, symmetry, etc. The list of attributes generally used for an automatic classification of lesions is related to the ABCD rule [Stolz, et al 1994]. This characterization phase is essential if we want, on one hand, to create a system that allows visualizing and analyzing the tumors and, on the other hand, to simplify the characterization operation of attributes. In this paper we two parameters (A, B) are extracted in order to improve the early detection of melanomas. Therefore these criteria try to get information about:

Asymmetry (A): according to dermatologists, melanomas grow in an anarchic way (asymmetric tumor) while benign tumors are symmetrical.

Irregular boundaries (B): benign lesions are usually defined by clear boundaries, while melanomas are defined by irregular contours.

THE PROPOSED METHODOLOGY

The proposed approach requires extracting specific attributes to the information we wish to code, mainly with respect to existing works in literature. The specification of this methodology is the combination of the smoothing technique using a Gaussian filter and the notion of pixel distribution in the lesion in order to improve the early detection of melanomas and decrease the calculation time.

As a first step, the segmented image is convoluted with a Gaussian filter with various standard deviations. We noticed that the ripples are erased and the image contour becomes smooth. The example of figure 3 illustrates a classical image along with the ones obtained after the smoothing operation. In order to calculate the irregularity index, it suffice to calculate the ratio between the initial image contour and the

resulting image contour. The problem we encountered was to know when the smoothing operation should be finished (stopping criterion). In order to remedy this problem, the idea was to generate a new contour whose shape is indicative of the pixel distribution in the lesion. This new contour will be a circle shaped. The average of pixels along this path is defined by the following equation:

Figure 3

$$Av_i = \frac{\sum_{k=1}^N I_{ik}}{N_i} \dots\dots\dots(1)$$

Where I_{ik} : the value of pixels along the radial path corresponding to boundary point i.

Therefore, the normalized distance is given by the following equation:

Figure 4


$$NC = \frac{\sum_{i=1}^N Av_i}{N} \dots\dots\dots(2)$$

Where N is the number of pixels on the contour of the segmented image.

Figure 3 illustres the results we obtained after the execution of an algorithm. For each iteration, we calculated the difference between the tumor compactness and the compactness of the circle we got. We noticed that after the fourth smoothing, the two compactnesses are almost identical.

Figure 5

Figure 3: Smoothing operation (after the fourth smoothing (), Irr= 77.45%



As a second step, in order to improve the decision, we added the asymmetry criterion to give a better presentation of lesions. In this case, we determined the center symmetry through a 180° angle of rotation (1st iteration of segmented image). Let $I(x,y)$ be the initial surface (1st iteration segmented image) and $J(x, y)$ the surface we obtained after symmetry. The ratio between the intersection of $I(x, y)$

surfaces and $J(x, y)$ surfaces and their merging, quantifies the recovery rate of the two surfaces and therefore the degree of symmetry. The calculation of this index is illustrated in figure 4, where the region in blue refers to the intersection of the surfaces and the external line defines their merging. The more the index approaches 1, the more the lesion will be considered as symmetrical.

Figure 6

Figure 4: Example of a mask overlaid on its symmetrical (180° center rotation)



So, ultimately our algorithm is as follows:

For $i=1 : N_L$ (number of smoothings)

- Smoothing ($I(x,y)$)
- Calculation of the average along the path

Figure 7

$$Av_i = \frac{\sum_{k=1}^N I_{ik}}{N_i} \quad \text{and} \quad NC = \frac{\sum_{i=1}^N Av_i}{N}$$

- Generate a new contour with a radius NC
- Test operation
 - Calculate and draw a circle for each smoothed contour (using operations 1 and 2)
 - Calculate the tumor and circle compactnesses (C_{tumor} , C_{circle})
 - Define a stopping criterion S_i { ($C_{tumor} - C_{circle} < \epsilon$) } (ϵ : the smallest possible difference)

Therefore

Figure 8

$$I_R = \frac{\text{Contour}(C_{\text{tumeur}} \approx C_{\text{cercle}})}{\text{Contour initial}}$$

Take the first contour

Center symmetrical rotation about the center of gravity

The recovery rate of the two surfaces

Figure 9

$$Asy = \left(1 - \frac{\Delta d}{S}\right) \times 100$$

(Δd is the difference between I and J; and S the merging between I and J)

RESULTS AND INTERPRETATION

In this article, we used four pigmented lesions selected among images of Lee's data base [T. Lee et al, 2000]. These selected images represent melanocytic lesions. The images used are in color with a 512 pixel x 486 pixel format and a spatial resolution equal to 0,033 x 0,025mm. Each tumor of the selected image is located at the center and surrounded by the skin color. These lesions vary in size, shape, color, saturation and in most cases, the margin between the lesion and the surrounding skin is poorly defined clinically, and this introduces sometimes some error decisions. To validate these results, twenty experienced dermatologists have been invited to visually assess these images. The assessment has been assessed on a 1 to 4 scale. The small value "1" refers to most of benign lesions and the large value "4" refers to the most serious ones with a high probability to be a melanoma. The following table shows the results of our algorithm. The 2nd and 3rd columns contain respectively the average and the decision of the clinical evaluation of dermatologists. We considered that if the average of the clinical evaluation of dermatologists is higher than 3 (CE >3), then it is a malignant tumor. The results we found depend on two pertinent parameters to increase the decision and give a better presentation of lesions. According to the interpretation of dermatologists, we considered that if one of the two parameters we found is greater than 50%, then it is a malignant tumor. According to these two considerations, we

evaluated our algorithm, and the final results are shown in the 4th column and compared with the clinical evaluation (CE) and Lee's works [T. Lee et al, 2000] (5th column). It is clearly shown, that these results are interesting except for one case where we found that the 18th test has been classified as a non-melanoma case. This is due to the segmentation method we used which does not provide a good contour characterization and also, the margin between the lesion and the skin which is poorly defined. This introduces sometimes a certain decision error. But in the case of the image that is studied, our algorithm gives very important values ($\approx 50\%$). The interpretation should be left to the dermatologists to decide, whether it is a malignant tumor or a benign lesion.

Figure 10

Image	C.E	C.E>3 (3votes)	Our methodology	Results of LEE
1	1,55	/	/	/
2	1,9	/	/	/
3	2,85	/	/	/
4	3,9	mélanome	mélanome	mélanome
5	1,05	/	/	/
6	1,55	/	/	mélanome
7	3,15	mélanome	mélanome	/
8	1,2	/	/	/
9	2,25	/	/	/
10	3,6	mélanome	mélanome	/
11	1,75	/	/	/
12	1,4	/	/	/
13	1,7	/	/	/
14	2,6	/	mélanome	/
15	1,25	/	/	/
16	1,45	/	/	/
17	1,2	/	/	/
18	3,6	mélanome	/	/
19	3,85	mélanome	mélanome	/
20	3,25	mélanome	mélanome	/
21	3,35	mélanome	mélanome	/
22	1,85	/	/	/
23	2,6	/	/	/
24	2,15	/	/	/
25	1,65	/	/	/
26	1,7	/	/	/
27	1,2	/	/	/
28	4	mélanome	mélanome	mélanome
29	1,05	/	/	/
30	1,75	/	/	/
31	1,45	/	/	/
32	2,3	/	/	mélanome
33	2,35	/	/	/
34	2,85	/	/	/
35	1,6	/	/	/
36	1,6	/	/	/
37	1,1	/	/	/
38	4	mélanome	mélanome	/
39	2,55	/	/	/
40	1,25	/	/	/

CONCLUSION

The approach we proposed is capable of testing and evaluating the discriminating efficiency of two attributes (Asymmetry and contour irregularity) as a function of the considered sign. We showed the feasibility of this approach

by the development of prototypes capable of recognizing the malignancy sign. In this work, we saw how to diagnose a skin melanoma using image processing techniques. We started in a first step with a pretreatment based on a median filter and on Dull-razor technique for its capacity to eliminate noise. In the second step, the segmentation approach was presented in order to localize the tumor and to extract the contour. Then, a series of transformations were applied to the lesion to extract the various attributes that describe the lesions. We presented the feasibility of our methodology compared to other attributes in order to improve the early detection of melanomas.

References

r-0. [C. Serruys et al 2002] Camille Serruys et al (2002.) " Classification automatique des tumeurs noires de la peau par des techniques numériques d'analyse d'images fondées sur des méthodes d'apprentissage par l'exemple : Aide au dépistage des mélanomes " thèse de doctorat, l'université Paris V, 2002.

r-1. [K.M. Clawson, et al, 2007] K.M. Clawson, et al, "Determination Of Optimal Axes For Skin Lesion Asymmetry Quantification", 1-4244-1437-7/07/2007 IEEE, 2007.

r-2. [K.M. Clawson, et al, 2007] K.M. Clawson, et al, " Computerised Skin Lesion Surface Analysis for Pigment Asymmetry Quantification ", 0-7695-2887-2/2007, DOI 10.1109/IMVIP.2007.34

r-3. [C. Serruys et al, 2002] Camille Serruys et al (2002.) " Classification automatique des tumeurs noires de la peau par des techniques numériques d'analyse d'images fondées sur des méthodes d'apprentissage par l'exemple : Aide au dépistage des mélanomes " thèse de doctorat, l'université Paris V, 2002.

r-4. [H.Hadzli, et al 2005] " Skin Lesions Color Analysis Based on RGB Reflectance Indices ", Faculty Electrical Engineering, 0-7803-9370-8/05/2005 IEEE.

r-5. [T.Taouil, et al 2006] "Automatic Segmentation and classification of Skin Lesion Images ", Sciences and Technologies of Image and Telecommunications Higher Institute of Biotechnology, Sfax, 1 -4244-0)409-6/06/2006

r-6. [M. Talibi-Alaoui et al 2004] M. Talibi-Alaoui, R. Touahni et A. Sbihi " Classification des Images Couleurs par association des Transformations Morphologiques aux Cartes de Kohonen ". Article, L. I et R. F, Kénitra, Maroc 2004.

r-7. [P. Bertolino 1995] Pascal Bertolino " contribution des pyramides irrégulières en segmentation d'images multirésolution " thèse, institut IMA Grenoble, 1995.

r-8. [T. Lee et al, 2000] Lee, T. and S. Atkins (2000). A new approach to measure border irregularity for melanocytic lesions. Spie 2000 Medical Imaging, San Diego.

r-9. [TIM LEE et al, 1997] TIM LEE, Dullrazor: A Software Approach To Hair Removal From Images, Cancer Control Research, British Columbia Cancer Agency, Vancouver, Canada, Vol. 21, No. 6, pp. 533-543, 1997, (Received 26 November 1996; revised 25 March 1997).

r-10. [Stolz, et al, 1994] Stolz, W., A. Riemann, et al. (1994). "ABCD rule of dermatoscopy: A new practical method for early recognition of malignant melanoma." Eur J Dermatol 4(7): 521-527.

Author Information

M. Messadi

Biomedical Engineering Laboratory, Department of Biomedical Electronics, Sciences Engineering Faculty, Abou Bekr Belkaid University

A. Bessaid

Biomedical Engineering Laboratory, Department of Biomedical Electronics, Sciences Engineering Faculty, Abou Bekr Belkaid University

A. Taleb-Ahmed

LAMIH UMR CNRS 8530 Laboratory