

Left axillary vein thrombosis accompanying hematoma developed after coronary angiography performed at upper arm region

U YETKIN, K ERGUNES, S BAYRAK, I YUREKLI, A GURBUZ

Citation

U YETKIN, K ERGUNES, S BAYRAK, I YUREKLI, A GURBUZ. *Left axillary vein thrombosis accompanying hematoma developed after coronary angiography performed at upper arm region*. The Internet Journal of Cardiology. 2009 Volume 8 Number 2.

Abstract

Vascular complications such as hematoma after coronary interventional procedures are responsible for considerable morbidity. For upper extremity deep vein thrombosis (UEDVT), low-molecular-weight heparin should be regarded as the treatment of choice. In this study we present a case of left axillary vein thrombosis accompanying hematoma developed after coronary angiography performed at upper arm region.

INTRODUCTION

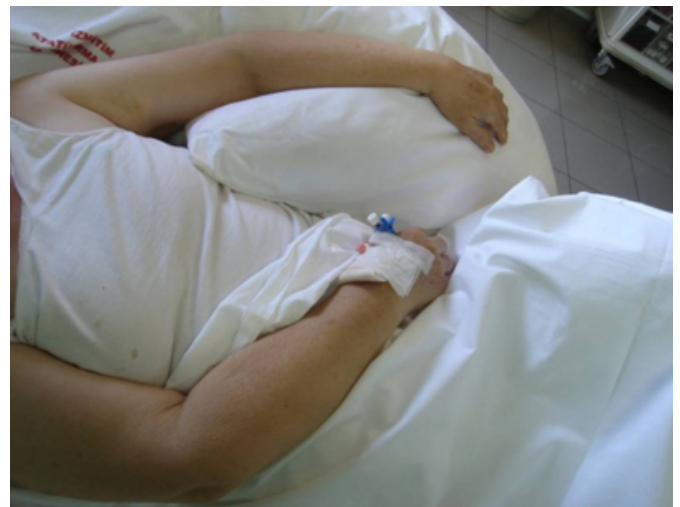Vascular complications continue to be a significant problem after cardiac catheterization, especially when coronary angioplasty is performed. Periodic review of these complications may identify factors that might be modified to reduce complications (1). Prognosis of overwhelming complications is good, as long as patients are treated timely and appropriately(2).

CASE PRESENTATION

Our case was a 67-year-old female. Two weeks before her admission, she underwent a coronary angiography performed at her left upper arm in another institution. Her past medical history was significant for hypertension and type II diabetes mellitus. She was suffering from pain in her left upper arm region, decrease in range of motion of her mentioned extremity and a minimal increase in diameter (Figure 1).

Figure 1

Figure 1



Her physical examination showed that all the distal pulses were palpable and in similar amplitudes. A minimal increase in diameter of the left upper arm, compared to the opposite side, and decrease in range of motion were evident. Color Doppler ultrasound revealed a hematoma of 5 cm next to the puncture site. No flow within the left axillary vein was detected and the lumen was filled with thrombus material. Flow of the remaining segments was maintained by the collaterals. Arterial structures were patent and so were the remaining segments of the left brachial vein (Figures 2,3&4).

Figure 2

Figure 2

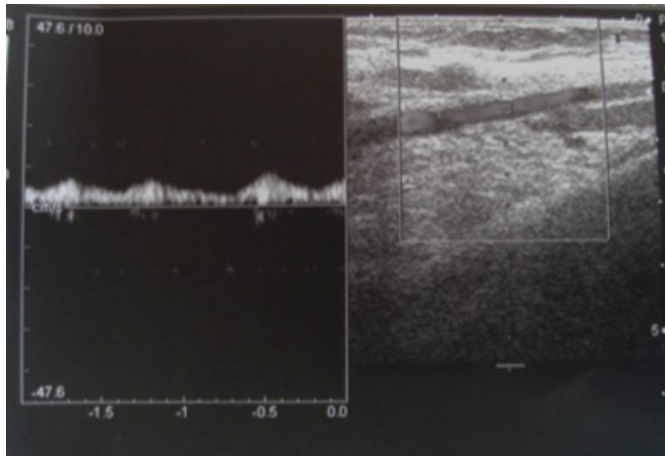


Figure 3

Figure 3

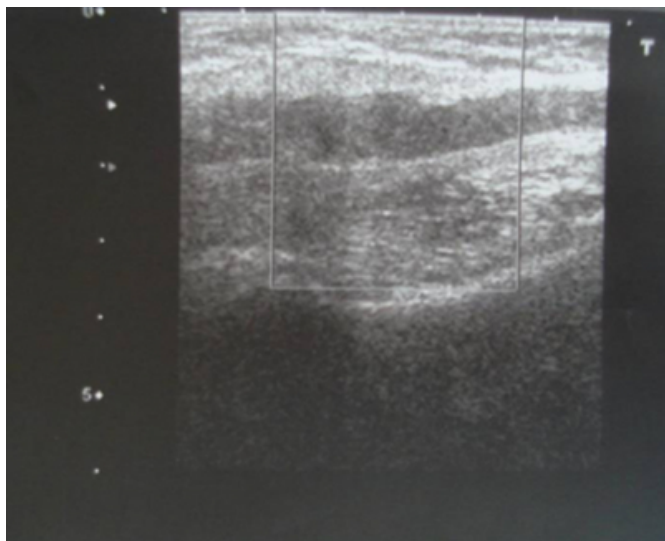
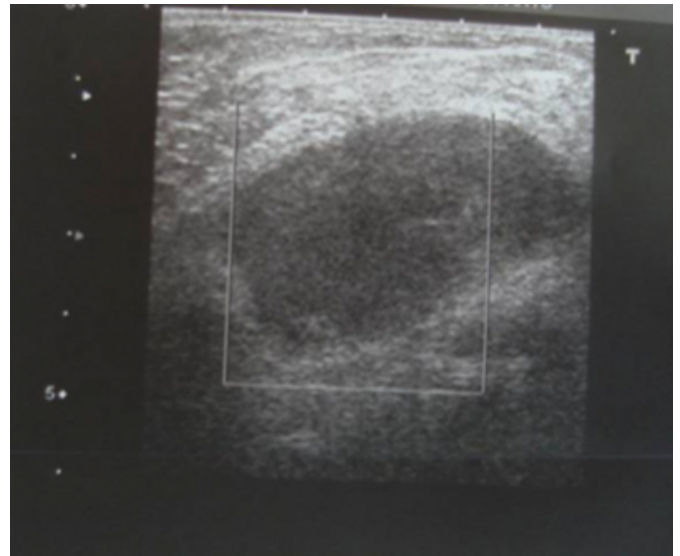


Figure 4

Figure 4



It was thought that axillary vein thrombosis of this case was developed secondary to the compression of the hematoma following the catheterization. Moreover; advanced age over 60 years, hypertensive state and hyperglycemia were considered to be the predisposing factors. She was hospitalized planning a medical and conservative treatment strategy. A low molecular weight heparin preparation, namely tinzaparin sodium of 12,000 IU (0,6 ml) SC, was initiated regarding her weight of 67 kilograms. Tinzaparin was chosen due to its ability to get neutralized easily by protamin sulphate since there was a localized hematoma. Moreover, her affected arm was elevated. Complementary medical treatment included an oral preparation of “Diosmin 450 mg + Hesperidin 50 mg”(2 tablets each morning), enteric coated tablet of 100 mg acetylsalicylic acid per day, heparinoid(luitpold) 445 mg/100 g gel 2x1 US and a non-steroidal anti-inflammatory drug preparation orally. She has been hospitalized for 5 days. She was investigated for a history of malignancies, thoracic outlet syndrome and protein C/S deficiency. After all these investigations, it was decided that this episode of DVT was due to the compression of hematoma that localized at axillary region in etiology. She was kept under low molecular weight heparin SC therapy for 3 months. Additionally, compressive clothing manufactured specific to her left upper extremity was recommended. She is asymptomatic and her control color Doppler ultrasound showed complete recanalization and no recurrence or post-thrombotic sequelae.

DISCUSSION

Upper limb deep vein thrombosis has been an under-recognized disease; however, physicians' awareness of it as a cause of arm pain and edema is increasing(3). Peripheral vascular complications following coronary interventional procedures include hematomas, pseudoaneurysms, arteriovenous fistulae, acute arterial occlusions, cholesterol emboli, and infections that occur with an overall incidence of 1.5-9% (4).

In the study of Zhou et al.; peripheral vascular complications were analyzed after cardiac catheterization. Of the 4,531 patients, 122 (2.7%) had peripheral vascular complications, including local hematoma (86 cases, 1.90%) (2).

Significantly more complications occurred in patients who were older than 60 years of age or female. In addition, the likelihood of a vascular injury after coronary angioplasty was significantly higher than after angiography alone (1).

For patients with objectively confirmed deep vein thrombosis (DVT) Kearon et al. recommend anticoagulant therapy with subcutaneous (SC) low-molecular-weight heparin (LMWH)(Grade 1A). And they recommend at least 3 months of treatment with LMWH for patients with VTE risk and after proximal DVT, they recommend use of an elastic compression stocking (Grade 1A) (5).

The clinical picture of upper extremity deep vein thrombosis (UEDVT) is characterized by swelling, pain, and functional impairment, but may also be completely asymptomatic, especially in carriers of central venous lines (6,7).

Objective testing is mandatory prior to instituting anticoagulation because the prevalence of UEDVT is less than 50% in symptomatic subjects, and compression ultrasound or color Doppler represents the preferred

diagnostic methods (6).

Many of these complications result in considerable increases in hospital stays and in the costs associated with the procedures (8). Anticipation and early recognition of possible peripheral vascular following coronary interventional procedures may translate into fewer vascular complications as well as into shorter and less costly hospital stays (4). Up to one third of the patients develop pulmonary embolism that may be fatal; postthrombotic syndrome and recurrent thromboembolism are also frequent complications. UEDVT should no longer be regarded as a rare and benign disease, as reported previously (7).

References

1. Ricci MA, Trevisani GT, Pilcher DB. Vascular complications of cardiac catheterization. *Am J Surg* 1994;167(4):375-8.
2. Zhou T, Zhou SH, Shen XQ, Qi SS, Liu QM, Fang ZF, Hu XQ, Li XP. Peripheral vascular complications after the cardiac catheterization. *Zhong Nan Da Xue Xue Bao Yi Xue Ban* 2007 ;32(1):156-9.
3. Shah MK, Black-Schaffer RM. Treatment of upper limb deep vein thrombosis with low molecular weight heparin. *Am J Phys Med Rehabil* 2003;82(5):415-7.
4. Nasser TK, Mohler ER 3rd, Wilensky RL, Hathaway DR. Peripheral vascular complications following coronary interventional procedures. *Clin Cardiol* 1995;18(11):609-14.
5. Kearon C, Kahn SR, Agnelli G, Goldhaber S, Raskob GE, Comerota AJ; American College of Chest Physicians. Antithrombotic therapy for venous thromboembolic disease: American College of Chest Physicians Evidence-Based Clinical Practice Guidelines (8th Edition). *Chest* 2008;133(6 Suppl):454S-545S.
6. Bernardi E, Piccioli A, Marchiori A, Girolami B, Prandoni P. Upper extremity deep vein thrombosis: risk factors, diagnosis, and management. *Semin Vasc Med* 2001;1(1):105-10.
7. Bernardi E, Pesavento R, Prandoni P. Upper extremity deep venous thrombosis. *Semin Thromb Hemost* 2006;32(7):729-36.
8. Davis C, VanRiper S, Longstreet J, Moscucci M. Vascular complications of coronary interventions. *Heart Lung* 1997;26(2):118-27.

Author Information

Ufuk YETKIN

Clinical Deputy Chief, Assoc. Prof. in CVS, Department of Cardiovascular Surgery(CVS), Izmir Ataturk Training and Research Hospital

Kazim ERGUNES

Specialist in CVS, Department of Cardiovascular Surgery(CVS), Izmir Ataturk Training and Research Hospital

Serdar BAYRAK

Specialist in CVS, Department of Cardiovascular Surgery(CVS), Izmir Ataturk Training and Research Hospital

Ismail YUREKLI

Specialist in CVS, Department of Cardiovascular Surgery(CVS), Izmir Ataturk Training and Research Hospital

Ali GURBUZ

Clinic Chief, Assoc. Prof. in CVS, Department of Cardiovascular Surgery(CVS), Izmir Ataturk Training and Research Hospital