

Papillary Cystic And Solid Tumour Of The Pancreas: Report Of A Rare Case

S Kumar Sahu, S Raghuvanshi, P Srivastava, P Singh, P Sachan, D Bahl

Citation

S Kumar Sahu, S Raghuvanshi, P Srivastava, P Singh, P Sachan, D Bahl. *Papillary Cystic And Solid Tumour Of The Pancreas: Report Of A Rare Case*. The Internet Journal of Surgery. 2006 Volume 10 Number 2.

Abstract

A 15-year-old female presented with a progressively increasing right hypochondrial mass since 3 months. CECT of the abdomen showed a large, well-defined, heterogeneous lesion with specks of calcification and areas of cystic degeneration in the region of head of pancreas. Successful enucleation of the tumour from the head of pancreas was achieved. Histopathology confirmed solid cystic papillary epithelial cystadenoma of pancreas.

Papillary cystic and solid tumours of pancreas are a rare, low-grade malignant tumour, typically found in young women. The etiology and cell of origin of this tumour are still not clear. It is important to differentiate this tumour from other pancreatic tumours, as this tumour is amenable to cure after complete surgical resection.

INTRODUCTION

Papillary cystic and solid tumours of pancreas (PCSTP), also known as solid-cystic epithelial tumour, solid-pseudopapillary or papillary-cystic tumour was first reported by Frantz in 1959.¹ It mostly affects young females at the mean age of 25 years and makes up about 0.2 - 2.7 % of all pancreatic tumours.^{2,3}

CASE REPORT

A 15-year-old female presented with pain in the right hypochondrium and a progressively increasing right hypochondrial mass since 3 months. There was no history of jaundice and vomiting. On examination, there was a firm mass in the right hypochondrium, which did not move with respiration.

Hematological investigation revealed: Haemoglobin 11.2gm/dl, Total Leukocyte Count 10,800/cumm, serum Amylase 200 IU/L and serum Lipase 50 U/L.

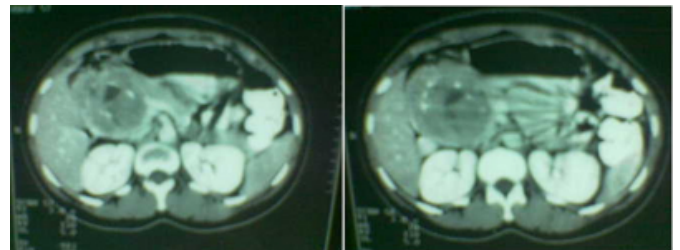
Imaging in the form of ultrasonography revealed a large complex mass in the right retroperitoneum, suggesting a neurogenic mass.

Contrast-enhanced CT scan showed a large well-defined heterogeneous concentric hypodense lesion with specks of calcification and areas of cystic degeneration in the right anterior pararenal space in the region of the head of the pancreas suggesting solid papillary or mucinous

cystadenoma (FIG-1).

Figure 1

Figure 1: Contrast-enhanced CT scan of the abdomen showing a large, well-defined heterogeneous concentric hypodense lesion with specks of calcification and areas of cystic degeneration in the right anterior pararenal space in the region of the head of the pancreas.



Ultrasound guided fine needle aspiration cytology from the mass suggested ganglioneuroblastoma.

On exploration, a large vascular lesion was present in the head of the pancreas displacing the duodenum posteriorly and the gall bladder anteriorly.

Enucleation of the tumour was done, followed by omentopexy of the residual cavity.

Postoperative recovery was uneventful.

Histopathology confirmed solid-cystic papillary epithelial cystadenoma of the pancreas.

DISCUSSION

Papillary cystic and solid tumours commonly arise in the tail and the body of the pancreas and very rarely involve the head.⁴ These tumours have also been reported in ectopic pancreas.²

The origin and histogenesis of papillary cystic and solid tumours of pancreas is controversial, with the tumour expressing epithelial as well as mesenchymal markers.^{4,6}

The tumour is usually encapsulated with a cut surface revealing lobulated light-brown solid areas admixed with zones of hemorrhage and necrosis as well as cystic spaces filled with necrotic debris.⁶

Although criteria of malignancy have not been clearly established in the literature for papillary cystic and solid tumours of the pancreas, perineural invasion or angioinvasion, with or without deep invasion into the surrounding tissue, are the criteria considered to indicate its malignant behavior.⁶

The presenting features of papillary cystic and solid tumours of the pancreas are relatively non-specific with large tumours presenting with symptoms related to the compression of adjacent structures and a palpable mass and the smaller tumours as abdominal discomfort or pain.^{4,5} Jaundice is reported to be rare, even in tumours originating from the head of the pancreas.⁵

Ultrasonography usually reveals a sharply demarcated, well circumscribed, variable, solid and cystic mass without any internal septations.⁷

CT scan shows a sharply circumscribed, well encapsulated heterogeneous and hypodense lesion.⁸ Endoscopic ultrasonography provides an accurate diagnosis of papillary cystic and solid tumours of the pancreas < 2cm.⁹

MRI shows good visualization of hemorrhagic areas in the sharply demarcated lesions.

FNAC is avoided due to the potential risk of tumour spillage and furthermore, it may not differentiate between pancreatoblastoma and papillary cystic and solid tumour.²

Complete resection is the treatment of choice and should involve complete removal of the tumour, the associated lymph nodes, the involved pancreas and any adjacent organs.

With tumours involving the head of pancreas, a pylorus preserving pancreaticoduodenectomy is recommended.¹¹

Central pancreatectomy and reimplantation of the pancreatic remnant into the stomach has been reported with the tumour involving the neck or body of the pancreas.¹¹ When the tumour is located at the pancreatic tail, distal pancreatectomy with splenectomy has been recommended.⁴ Splenic conservation following distal pancreatectomy has also been tried.¹¹

Conservative resections such as lumpectomy, enucleation, evolution, central pancreatectomy and partial resection of the head of the pancreas have also been reported as effective due to the low-grade malignant potential of papillary cystic and solid tumour.^{4,12}

There is no clear established role of chemo-radiation therapy in the management of papillary cystic and solid tumour.¹³

More than 95% of patients are reported to be cured by complete surgical excision only.⁵

Papillary cystic and solid tumour is an uncommon primary pancreatic neoplasm of unknown etiology with a low malignant potential and should be considered in the differential diagnosis of any pancreatic mass, especially in young women.

CORRESPONDENCE TO

Dr. Shantanu Kumar Sahu Assistant Professor, Department of General Surgery Himalayan Institute of Medical Sciences Swami Rama Nagar Post- Doiwala Dehradun Uttaranchal Mob- 0-9412933868 Email- Intshantanu@yahoo.co.in

References

1. Frantz VK: Tumour of the pancreas. In Atlas of tumour pathology, Section VII, Fascicles 27 and 28. Washington, DC: Armed Forces Institute of Pathology; 1959:32-33.
2. Nadler EP, Novikov A, Landzberg BR, Pochapin MB, Centeno B, Fahey TJ, Spigland N: The use of endoscopic ultrasound in diagnosis of solid pseudopapillary tumours of pancreas in children. *J Pediatr Surg* 2002, 37:1370-1373.
3. Lee WJ, Park YT, Choi JS, Chi HS, Kim BR: Solid and papillary neoplasm of the pancreas. *Yonsei Med J* 1996, 37:131-141.
4. Abdul Kasem, Zainab Ali, Joseph Ellul: Papillary cystic and solid tumour of the pancreas: Report of a case and literature review. *World Journal of Surgical Oncology* 2005, 3:62.
5. Grant LD, Lauwers GY, Meloni AM, Stone JF, Betz JL, Vogel S: Unbalanced chromosomal translocation, der(17)t(13;17)(q14;p11) in a solid and cystic papillary epithelial neoplasm of the pancreas. *Am J Surg Pathol* 1996, 20:339-345.
6. Lee DH, Yi BH, Lim JW, Ko YT: Sonographic findings of solid and papillary epithelial neoplasm of the pancreas. *J Ultrasound Med* 2001, 20:1229-1232.
7. Dong PR, Lu DS, Degregario F, Fell SC, Au A, Kadell BM: Solid and papillary neoplasm of the pancreas:

Radiological-pathological study of five cases and review of the literature. *Clin Radiol* 1996, 51:702-705.

8. Koito K, Namieno T, Nagakawa T, Shyonai T, Hirokawa N, Morita K: Solitary cystic tumour of the pancreas: EUS-pathologic correlation. *Gastrointest Endosc* 1997, 45:268-276.

9. Yang YJ, Chen JS, Chen CJ, Lin PW, Chang KC, Tzeng CC: Papillary cystic tumour of the pancreas in children. *Scand J Gastroenterol* 1996, 31:1223-1227.

10. Panieri E, Krige JE, Bornman PC, Graham SM, Terblanche J, Cruse JP: Operative management of papillary cystic neoplasm of the pancreas. *J Am Coll Surg* 1998, 186:319-324.

11. Iacono C, Bortolasi L, Serio G: Is there a place for central pancreatectomy in pancreatic surgery. *J Gastrointest Surg* 1998, 2:509-516.

12. Schwartz DC, Campos MA: A woman with recurrent abdominal pain. *Am J Med Sci* 2001, 321:352-354.

Author Information

Shantanu Kumar Sahu

Assistant Professor, Surgery, Department of General Surgery, Himalayan Institute of Medical Sciences

Shailendra Raghuvanshi

Assistant professor, Radiology, Himalayan Institute of Medical Sciences

Puneet Srivastava

Senior resident, general surgery, Department of General Surgery, Himalayan Institute of Medical Sciences

Parvesh Singh

Postgraduate Student, general surgery, Department of General Surgery, Himalayan Institute of Medical Sciences

P. K. Sachan

Professor, Surgery, Department of General Surgery, Himalayan Institute of Medical Sciences

Dig Vijai Bahl

Professor and Head, Department of General Surgery, Himalayan Institute of Medical Sciences