

'Mysterious' Bone in Abdominal wall: An Interesting Bone Scan

J Hephzibah, B Theodore, R Oommen

Citation

J Hephzibah, B Theodore, R Oommen. 'Mysterious' Bone in Abdominal wall: An Interesting Bone Scan. The Internet Journal of Nuclear Medicine. 2006 Volume 3 Number 2.

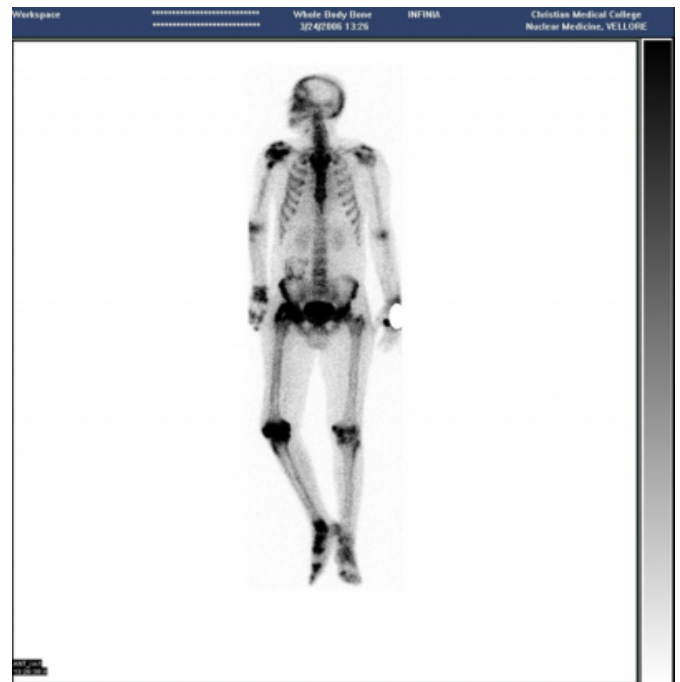Abstract

A 40 year old gentleman with a history of right hemiplegia following superior sagittal sinus thrombosis was evaluated for stiffness in right hip joint. Plain radiography of pelvis revealed soft tissue calcification around right hip joint, suggestive of heterotopic ossification.

For further evaluation of heterotopic ossification, a bone scintigraphy was asked for, which revealed irregular and increased tracer accumulation in soft tissues around right hip joint and in right knee joint. Another finding in bone scintigraphy was an irregular ring – like area of abnormal tracer accumulation in right lumbar area which was not conforming with any bone structure (Fig. 1).

Figure 1

Figure 1: Bone scintigraphy shows evidence of abnormal tracer accumulation in the soft tissues around left hip joint, suggestive of heterotopic ossification. There is an irregular rim of abnormal tracer uptake in the right lumbar region.

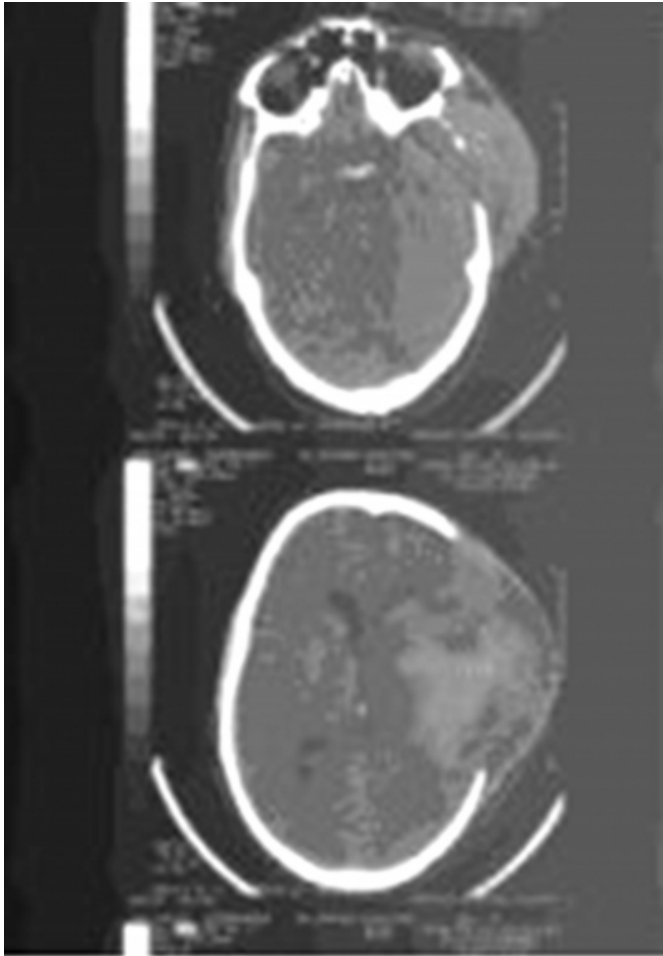


It was puzzling since no reason for such a finding could be thought of. On further interrogation of the patient, the reason was disclosed; the patient had undergone craniectomy (Fig. 2) in the past and the vault flap was safely deposited in the abdominal wall ('safe locker') for future replacement.

Figure 2

Figure 2: CT scan showing evidence of left frontotemporal craniectomy.

References



Author Information

Julia Hephzibah, Lecturer

Department of Nuclear Medicine, Christian Medical College

Bernice Theodore

Registrar, Department of Nuclear Medicine, Christian Medical College

Regi Oommen

Professor and Head, Department of Nuclear Medicine, Christian Medical College