

Adenomyosis in a noncommunicating rudimentary horn of unicornuate uterus - a diagnostic dilemma

S Ray, A Halder, M Gangopadhyay

Citation

S Ray, A Halder, M Gangopadhyay. *Adenomyosis in a noncommunicating rudimentary horn of unicornuate uterus - a diagnostic dilemma*. The Internet Journal of Gynecology and Obstetrics. 2008 Volume 11 Number 2.

Abstract

The prevalence of congenital uterine malformations is about 0.5%. Unicornuate uterus is a rare anomaly of the female internal genitalia (2.5-13%) [

1

]. Partial development of one of the mullerian ducts may result in anomalies in various combinations whereby one of the horns may remain rudimentary with or without any communication with its fellow [

1

]. Complications related to this condition are related to its presentation during different phases of life of a woman. We present a case of adenomyosis in the noncommunicating laterally displaced rudimentary horn which gave us a primary impression of solid ovarian tumor.

CASE REPORT

A 45 year old woman, Para 2, presented with a lump in her lower abdomen which had increased in size since past 18 months. She had regular menstrual cycles but felt pain in the lower abdomen as well as in the low back region during menses. There was no significant loss of weight or alteration of bladder or bowel habits. She had borne three children vaginally. In her first pregnancy she had pregnancy induced hypertension and delivered breech vaginally. Her second pregnancy was uneventful but she had an intrauterine fetal death (IUFD) at term in her third pregnancy.

She is a short statured woman (4ft 9 in) and clinical examination revealed a large and firm smooth surfaced, non-tender lump of about 16 weeks gravid uterine size arising from the pelvis without any restriction in mobility. The lower pole could be delineated with ease. There was no evidence of free fluid in the peritoneal cavity. Vaginal examination revealed uterus and left adnexa normal, and on the right a firm mobile mass consistent with the abdominal examination. USG of whole abdomen revealed a mass on the right side with normal uterus and left ovary. Right ovary could not be seen and the final impression was either a subserous fibroid or an ovarian tumor. There was no abnormality in renal tract.

Laparotomy was performed through Pfannenstiel incision. A

mass (about 12 x 15cm.) was seen attached to the horn of the unicornuate uterus on left side. Round ligament, tube and ovary was attached to the left side. Right ovary and tube was seen separately connected to the solid mass but the round ligament on this side was obscured probably due to stretch. Both tubes and ovaries looked healthy. Total abdominal hysterectomy with bilateral salpingo-oophorectomy was performed. The specimen was thoroughly studied postoperatively [Fig 1, Fig 2] and cut open to identify the cavity in both the mass and the uterus. The cut surface of the mass showed scattered areas of tiny hemorrhagic spots [Fig 3].

Figure 1

Fig 1. Anterior view showing vicryl tied to the right round ligament & separate attachment of tubes to the mass and left semi uterus.

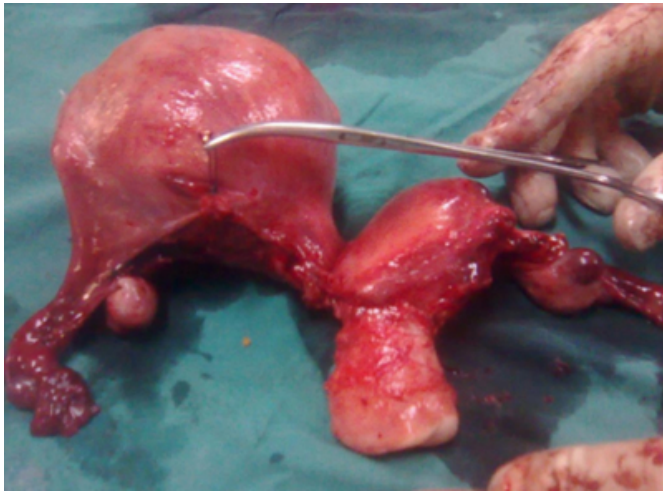


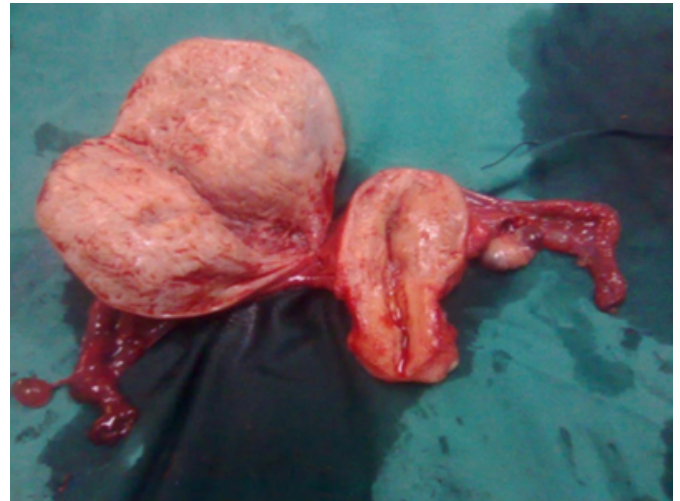
Figure 2

Fig 2. Posterior view showing separate attachment of tubes and ligament of ovaries to the mass and left semi uterus

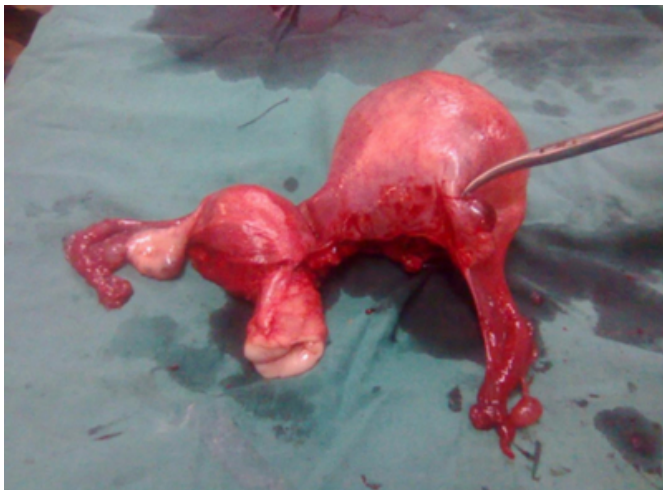

Figure 3

Fig 3. Specimen cut opened anteriorly shows cavity in the semi uterus and the cut surface of the mass showing scattered areas of tiny hemorrhagic spots.



Histopathology confirmed the mass to be adenomyosis with islands of endometrium in the mass but the uterus, both tubes and ovaries were normal. There was no connective tissue between the two horns.

DISCUSSION

A unicornuate uterus may lead to various gynecological or obstetric complications and diagnoses are often difficult and delayed to the fertile period or to pregnancy [1]. It may present as pregnancy in the semi-uterus or rarely in the rudimentary horn and it is difficult to estimate the true incidence of these complications [2]. According to Buttram & Gibbons unicornuate uterus has seven subtypes based on their anatomy [3]. In the present case we found a laterally displaced rudimentary horn which according to the above classification falls under 'b' variant of class II. This constitutes about 7.7 to 42.9% of cases of unicornuate uterus with rudimentary horn [4]. Evaluation of renal tract is necessary owing to its frequent association with this type of malformations [1]. The case in discussion presented with mass in her abdomen and dysmenorrhea. In one study the incidence of endometriosis was as high as 20% [5]. About 50% patients presenting with endometriosis with unicornuate uterus and a cavitary rudimentary horn have communication between the endometrial cavity in the rudimentary horn and tubal lumen [4]. Ultrasonography can pick up anomalies of uterus with reasonable accuracy. MRI & CT scan are other tools for diagnosis [6]. Classically, it has been assumed that uterine malformations are associated with late miscarriages and preterm deliveries and high incidence

of early pregnancy losses also [2]. Pregnancy in a noncommunicating cavitory rudimentary horn is a rare and life threatening condition and can only be possible by transperitoneal migration of sperms. Our patient was fortunate enough that she did not have any pregnancy related complications. Strikingly our patient had a very successful obstetric history and there was no renal tract anomaly either. In unicornuate uterus with a rudimentary horn excision of the rudimentary horn is the usual treatment [4]. In the present case, as her family was complete and she was 45 yrs aged, we performed abdominal hysterectomy with removal of tubes, ovaries and the adenomyotic rudimentary horn which gave an earlier clinical impression of a solid ovarian SOL. Unicornuate uterus with a cavitated noncommunicating rudimentary horn may also be misdiagnosed as sub-mucous fibroid [1]. Our patient is free from any problem one month following operation. Every effort should be made to diagnose this condition before pregnancy occurs owing to its fatal complications. The rudimentary horn should be excised

whenever diagnosed.

References

1. Katrin S, Annette K, Luigi R, Hermann B, Michael D M. The non-communicating rudimentary horn: diagnostic and therapeutic challenges. *Gynecol Surg* (2007) 4:207–211.
2. Francisco R, Celia B, Jose R, Fernando B M, Carlos S, Antonio P. Reproductive impact of congenital Mullerian anomalies. *Human Reproduction* (1997)12; 10:2277–2281.
3. Buttram VC, Gibbons WE. Mullerian anomalies: a proposed classification (an analysis of 144 cases). *Fertil Steril* 1979; 32:40-46.
4. Ken-ichi S, Wataru T, Fumikazu K, Unicornuate uterus with a noncommunicating cavitory, laterally dislocated rudimentary horn presenting with adenomyosis, associated with ipsilateral renal agenesis. *Arch Gynecol Obstet* (2000)264:88–89.
5. Heinonen PK. Clinical implications of the unicornuate uterus with rudimentary horn. *Int J Gynecol Obstet* 1983;21:145-50.
6. Goel P, Aggarwal A, Devi K, Takkar N, Saha PK, Huria A. Unicornuate uterus with non-communicating rudimentary horn– different clinical presentations. *J Obstet Gynecol India* (2005)55; 2: 155-158

Author Information

Sailes Ray, DGO, MS

RMO cum Clinical Tutor, Department of Gynecology & Obstetrics, North Bengal Medical College & Hospital

Atin Halder, DGO, MD

Assistant Professor, Department of Gynecology & Obstetrics, North Bengal Medical College & Hospital

Mimi Gangopadhyay, MD(Pathology)

Assistant Professor, Dept. of Pathology, North Bengal Medical College & Hospital