

# Efficacy of Gelclair oral gel in the treatment of oral mucositis in patients with head and neck tumours treated with chemotherapy and /or radiotherapy

N Kantardži?, V Smajlbegovi?, N Kazic, A Cardzic

## Citation

N Kantardži?, V Smajlbegovi?, N Kazic, A Cardzic. *Efficacy of Gelclair oral gel in the treatment of oral mucositis in patients with head and neck tumours treated with chemotherapy and /or radiotherapy*. The Internet Journal of Oncology. 2008 Volume 6 Number 2.

## Abstract

Background: During radiotherapy or chemotherapy of head and neck tumours patients commonly suffer from oral mucositis. Symptoms of oral mucositis are pain; discomfort or inability to tolerate food and fluid. Mucositis can be severe and limit the patient's ability to tolerate chemotherapy or radiotherapy, cause delay and limit the effectiveness of cancer therapy. Aim: To examine effectiveness of gelclair oral gel in the treatment of oral mucositis in patients with head and neck tumours during radiotherapy or/and chemotherapy. Material and method: This is nonrandomized, prospective study. We included 15 patients treated with radiotherapy and/or chemotherapy and proven head and neck tumours. During their oncology therapy they were treated with gelclear oral gel and checked every day for severity of their symptoms. Results: In the 13 patients significant improvement in the management of pain was observed, and 11 patients had improvement in food and fluid intakes. There were no delays in treatment, caused by severity of oral mucositis. Conclusion: Gelclear oral gel is safe and efficient agent in the treatment of oral mucositis, one of most common complication of radiotherapy and/or chemotherapy in patients with head and neck tumours.

This study was supported by Pharma Swiss – department Sarajevo, Bosnia and Herzegovina.

## INTRODUCTION

Malignant head and neck tumours represent about 4% of all malignancies. Squamous cancers of the upper aero digestive tract constitute approximately 6% of new cancer cases in men and 2% in female at all sites, except the salivary glands; there is a significant preponderance of cases in men<sup>1</sup>. It is most common between 45 to 70 years<sup>2</sup>.

In the time of diagnosis about 70 % of patients are in III or IV stage of disease<sup>3</sup>.

Treatment options include surgery, radiotherapy and chemotherapy, before, during or after radiotherapy.

If the patients are treated with radio and/or chemotherapy one of the most common side effects is oral mucositis. It occurs in 20-40% of patients treated with chemotherapy alone and up to 50% of patients receiving combination radiation and chemotherapy, especially those with head and

neck tumors.

Main symptoms of oral mucositis are: erythema, taste loss, pain, and a sore or dry mouth, swallowing and eating difficulty<sup>4</sup>. Tooth and gum disease further complicate the problem. Reduction of caloric intake can lead to weight loss, loss in muscle mass strength and other complications, including a decrease in immunity. Patients with damaged oral mucosa and reduced immunity are prone to opportunistic mouth infections.<sup>5</sup>

The potential impact of morbidity and mortality with oral mucositis should not be underestimated and requires active treatment.

The consequences of mucositis can be mild requiring little intervention to severe that may result in fatal complications.

If oral mucositis is not treated it can cause delays in chemotherapy and/or radiotherapy treatment, or even stopping of specific oncology treatments and compromise survival.<sup>6</sup>

Many different treatment options can be used to prevent and treat oral mucositis. Oral care protocols including dental work before starting therapy and oral cleaning during the therapy.

Mouth wash products, antiseptic, antibacterial, antifungal, antiviral, and many other products were used. It is obvious that many interventions used in clinical practice have never been rigorously evaluated. There is no standard evidence based 1 protocol for treatment of oral mucositis during radio and/or chemotherapy.<sup>7</sup>

Gel clear oral gel was approved in 2001 by FDA, for treatment of oral mucositis. This product still is not on the positive list of medication for patients in Bosnia and Herzegovina.

## PATIENTS AND METHODS

In the period from January to Jul 2008 15 patients were included in this study.

They had pathologically proven head and neck tumor, 13 were males and 2 females.

Surgery was performed in 14 patients, and all 14 had adjuvant radiotherapy, among them 9 were treated with radio and chemo therapy. One patient had just radio and chemo therapy, and 5 just adjuvant radiotherapy after surgery.

Radiotherapy of the tumor and neck with two opposite field, and one anterior supraclavicular field was used technique in 14 patients; one was irradiated with two small opposed fields on larynges. Two to three cycles of chemotherapy with cisplatin 100 mg and 5 fluorouracil 1000 mg was given prior to radiotherapy in 9 patients, and in 5 patients cisplatin was given alone on the day 1, 21 and 42 of radiotherapy treatment.

During their oncology therapy we evaluated grade of oral mucositis by WHO scale.

In the second week of radiotherapy they started with gel clear oral gel standard treatment for oral mucositis.

### Figure 1

Table 1. WHO scale of oral mucositis

Grade WHO	0	1	2	3	4
	none	Soreness +/- erythema	Erythema, ulcers, and patient can swallow solid food	Ulcers, with extensive erythema and patient cannot swallow solid food	Mucositis to the extent that alimentation is not possible

### Figure 2

Table 2. Patients by the age

age patient	20-29	30-39	40-49	50-59	60-69	70-79
	1	0	1	2	8	3

The most of patients were 60 and older, average age 61 (26-76 years)

### Figure 3

Table 3 . Patients by the diagnosis

diagnosis	ca laryngis	ca hypopharyngis	ca oropharyngis	ca maxillae and mandibulae	ca metastaticum colli
Stage I	0	0	0	0	0
Stage II	1	0	0	0	0
Stage III	1	0	2	1	0
Stage IV	3	1	3	2	1

The most of patients were diagnosed as carcinoma of laryngis and carcinoma of oropharyngis, and with advanced disease.

### Figure 4

Table 5. Patients by the treatment

treatment patients	surgery	radiotherapy	radiotherapy + chemotherapy
	14	5	10

The most of patients had combined therapy.

## RESULTS

### Figure 5

Table 6. treatment of pain

oral mukositis patients	pain before geklear oral gel	pain after geklear oral gel
	15	2

Pain was reduced in 86.7% of patients after the treatment with gelclear oral gel.

### Figure 6

Table 7. Treatment of swallowing difficulties

oral mukositis patients	swallowing difficulties before geklear oral gel	swallowing difficulties after geklear oral gel
	15	4

Swallowing difficulties were reduced in 73% of patients with gelclear oral gel.

### Figure 7

Table 8. Scale of oral mucositis before and after treatment

oral mukositis	before geklear oral gel	after geklear oral gel
G1	2	7
G2	5	2
G3	4	5
G4	4	0
G0	0	1

After the treatment with gelclear oral gel all patients experienced improvement in oral mucositis.

**Figure 8**

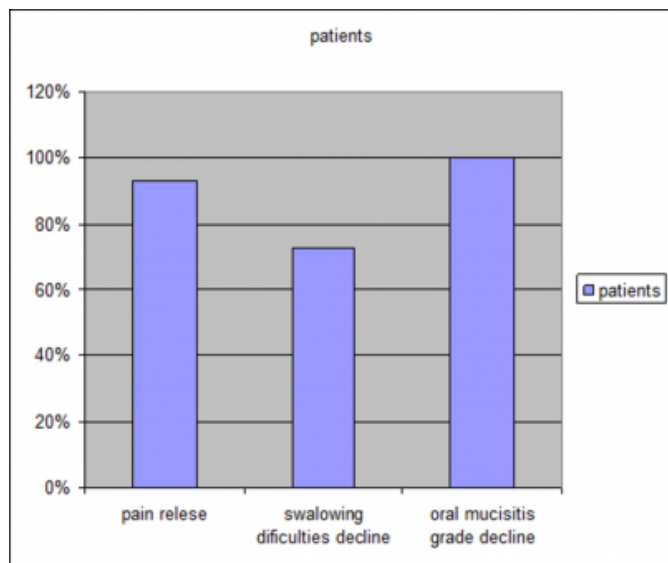
Table 9. Duration of treatment

week number	1	2	3	4
	1	9	4	1

The most of patients needed two weeks of treatment for optimal results.

**Figure 9**

Graf icon 1. Efficacy of gelclear oral gel in treatment of oral mucositis



Many of symptoms of oral mucositis were resolved with gelclear oral gel.

## DISCUSSION

Side effects of treatments in oncology can be very severe and can deteriorate quality of life, delay end of therapy, or alter survival of patients.

Mucositis induced by antineoplastic drugs is an important, dose-limiting, and costly side effect of cancer therapy. The ulcerative lesions produced by mucotoxic chemoradiotherapy are painful, restrict oral intake and, importantly, act as sites of secondary infection and portals of entry for the endogenous oral flora.<sup>8</sup> The overall frequency of mucositis varies and is influenced by the patient's diagnosis, age, level of oral health, and type, dose, and frequency of drug administration. Some degree of mucositis occurs in approximately 40% of patients who receive cancer chemotherapy. Approximately one-half of those individuals develop lesions of such severity as to require modification of their cancer treatment and/or parenteral analgesia. The condition's incidence is consistently higher among patients undergoing conditioning therapy for bone marrow/peripheral

blood progenitor cell transplantation, continuous infusion therapy for breast and colon cancer, and therapy for tumors of the head and neck associating concomitant chemotherapy and radiotherapy. Among patients in the high-risk protocols, severe mucositis occurs with a frequency in excess of 60%.

Concomitant with mucositis is often a chemotherapy-induced myelosuppression. The neutropenia that results puts the patient with oral mucositis at significant risk for systemic infection. Patients with mucositis and neutropenia have a relative risk of septicemia that is greater than four times that of individuals without mucositis

The morbidity of all mucositis can be profound. It is estimated that approximately 15% of patients treated with radical radiotherapy to the oral cavity and oral pharynx will require hospitalization for treatment-related complications. In addition, severe oral mucositis may interfere with the ability to deliver the intended course of therapy, leading to significant interruptions in treatment, and possibly impacting on local tumor control and patient survival. It is also not unusual for mucositis to necessitate delays in cancer chemotherapy particularly with those agents that are known to be mucotoxic, including 5-fluorouracil with or without folinic acid, methotrexate, doxorubicin, etoposide, melphalan, cytosine arabinoside and cyclophosphamide.

Seto in one and Blijlevens in another work introduced problem of oral mucositis not only in head and neck tumour undergoing radiotherapy and chemotherapy, but also in patients undergoing bone marrow transplantation.<sup>9, 10</sup>

In addition to pain and decreased quality of life, recent studies have begun to more accurately measure the specific medical complications and consequences of mucositis. Rapoport et al<sup>11</sup> showed that severe mucositis was correlated with an increased incidence of bacteremia and mortality, and overall higher costs, and The results of a recent study by Horowitz et al<sup>12</sup> showed similar clinical correlates to severity of mucositis, and strongly suggested a high economic price caused by severe mucositis.

These and additional data from Ruescher et al<sup>13</sup> validate the hypothesis that serious infection can result from severe mucositis and cause an increase in systemic infections, hospital days, and costs.

The last report that granulocyte-macrophage colony-stimulating factor (GM-CSF), given as an oral rinse, neither reduces the frequency or duration of severe oral mucositis

induced by high-dose chemotherapy given to recipients of an autologous peripheral blood haematopoietic stem cell transplant to treat solid tumours. The study meets the modern standards for evidence-based medicine as the drug was allocated randomly in a double-blind fashion to a large enough population to detect a difference of at least 25% between the placebo and the active treatment with a power of 90%. Spielberger<sup>14</sup> and co-authors presented good results of Palifermin in treatment of oral mucositis.

Sonis<sup>15</sup> in his work discussed importance of dental work prior to chemo or radiotherapy in cancer patients, for preventing oral mucositis.

In summary, the management of established mucositis can be difficult for both the patient and the provider. General approaches include effective oral care, dietary modifications and topical mucosal protectants. In addition, appropriate use of topical anesthetics and systemic analgesics remain the cornerstone of therapy. Promising agents that accelerate mucosal healing and alter the course of the biologic process of mucositis are under investigation.

Gelclear oral gel showed good results in treatment of oral mucositis as Innocenti M<sup>16</sup>, and Hita-Iglesias P<sup>17</sup> both showed in their studies.

Gel clear oral gel was approved by FDA in the 2001 year. It became available in Bosnia and Herzegovina last year. Reports showing that this is good product for treatment of oral mucositis, but it is not on the positive list of drugs or on the hospital list.

So this study was performed to establish efficacy of this product in our patients and eventually to propose this product to be put on the positive list for treatment of oral mucositis in this strict group of patients.

In our study we proved that gelclear oral gel is good and safe product for treatment of oral mucositis in the patients with head and neck tumours during their radiotherapy or/and chemotherapy. We achieved good response for many symptoms of oral mucositis. We also showed that response was achieved in short time (two weeks) in the most of patients. Our results are comparable with results in other similar studies.

## **CONCLUSION**

In the study were included 15 patients with head and neck tumours treated with radiotherapy and/or chemotherapy.

Gel clear oral gel treatments lasted from 1-4 weeks.

It is efficient and safe product for treatment of oral mucositis during radiotherapy and/or chemotherapy.

Usage is simple and convenient for patients.

Gel clear oral gel is fast and long-lasting remover of pain caused by oral mucositis.

It enables regular feeding with solid food and fluids during radiotherapy and/or chemotherapy, as a treatment of head and neck tumours.

Gel clear oral gel is good product for achieving good quality of life during radiotherapy and/or chemotherapy of head and neck tumours.

## **ACKNOWLEDGMENT**

This study was supported by Pharma Swiss BH d.o.o Sarajevo, Bosnia and Herzegovina.

## **References**

1. Samija M, Krajina Z, Perisic A. Radioterapija. Nakladni zavod Globus, Zagreb, 1996 god, str.193
2. Braukland J, Fauci T, Kasper W, Hauser R, Jameson G. Harrisonova nacela interne medicine, 15 izdanje, 2004 str.194. McGraw-Hill
3. Musanovic M, Obralic N Onkologija. Bosnjacki institut. Fondacija Adil Zulfikarpašić, Sarajevo, 2001
4. Ganday A, Lie D. MD, MSED New Mucositis Guidelines Issued CME 2008
5. Rosenbaum E.H, MD, Silverman S, MA, DDS, Festa B, MS, RD, Rosenbaum I:R, MA, MS, RD, Elliott-Snow R, RDH, Ignoffo R.J. Mucositis: Oral, Esophageal and gastrointestinal Problems and Solutions-PharmD;2007.
6. Summary of Evidence-based Clinical Practice Guidelines for Care of Patients with Oral and gastrointestinal Mucositis 2005 Update
7. Sook-Bin Woo, DMD, MS, BDS, MMSc ;Nathaniel S Treister, DMD, DMSc; Chemotherapy-Induced Oral Mucositis Article Last Updated: Oct 2, 2006
8. Clarkson JE, Worthington HV, Eden OB. Interventions for treating oral mucositis for patients with cancer receiving treatment. Cochrane Database of Systematic Reviews 2007, Issue 1. Art. No.: CD001973. DOI: 10.1002/14651858.CD001973.pub3
9. Sonis S:T. Is oral mucositis an inevitable consequence of

intensive therapy for hematologic cancers? *Nature Clinical Practice Oncology* (2005) 2, 134-135

10. Seto BG, Kim M, Wolinsky L, Mito RS Champlin R Oral mucositis in patients undergoing bonemarrow transplantation. *Oral Surg Oral Med Oral Pathol.* 1985 Nov;60(5):493-7.

11. Blijlevens N, Schwenkglenks M, Bacon P, D'Addio A, Einsele H, Maertens

J, Niederwieser D, Rabitsch W, RoosaarA, Ruutu T, Schouten H, Stone R,

VokurkaS, Quinn B, McCann S Prospective Oral Mucositis Audit: Oral

Mucositis in Patients Receiving High-Dose Melphalan or BEAM Conditioning

Chemotherapy—European Blood and Marrow Transplantation

Mucositis Advisory Group *Journal of Clinical Oncology*, 2008: Vol 26, No 9

(March 20)2008: pp. 1519-1525

12. Rapoport AP, Watelet LF, Linder T et al. Analysis of factors that correlate with mucositis in recipients of autologous and allogeneic stem cell

transplants. *J Clin Oncol* 1999; 17: 2446-2453, MEDLINE

13. Horowitz MM, Oster G, Fuchs H et al. Oral Mucositis Assessment Scale

(OMAS) as a predictor of clinical and economic outcomes in bone marrow

transplant patients. *Blood* 1999; 94 (Suppl. 1): 399a (Abstr.),

14. Ruescher TJ, Sodeifi A, Scrivani SJ et al. The impact of mucositis on alpha

hemolytic streptococcal infection in patients undergoing autologous bone marrow transplantation for hemotologic malignancies. *Cancer* 1998; 82: 2275-2281, Article MEDLINE

15. Spielberger R, M.D., Stiff P, M.D., Bensinger W, M.D., Gentile T, M.D.,

Ph.D., Weisdorf D, M.D., Kewalramani T, M.D., Shea T, M.D.

Yanovich S, M.D., Hansen K, M.D., Noga S, M.D., Ph.D., McCarty J,

M.D., Le Maistre C.F, M.D., Sung E.C. D.D.S., Blazar B:R, M.D.,

Elhardt D, Ph.D., Chen M, M.S., Emmanouilides C, M.D.

Palifermin for Oral Mucositis after Intensive Therapy for Hematologic

Cancers *NEJM*, 2004, Vol 351: 2590-2598

16. Sonis S, Kunz A: Impact of improved dental services on the frequency

of oral complications of cancer therapy for patients with non-head-and-

neck malignancies. *Oral Surg Oral Med Oral Pathol* 65 (1): 19-22, 1988.

17. Innocenti M, Moscatelli G, Lopez S, et al: Efficacy of Gelclair in reducing

pain in palliative patients with oral lesions: Preliminary findings from an

open pilot study. *J Pain Manage* 24:456-457, 2002.

18. Hita-Iglesias P, Torres-Lagares D, Gutiérrez-Pérez JL, et al: Evaluation of

the clinical behaviour of a polyvinylpyrrolidone and sodium hyalonurate gel

(Gelclair) in patients subjected to surgical treatment with CO2 laser. *Int J*

*Oral Maxillofac Surg* 35:514-517, 2006.

**Author Information**

**Nermina Kantardži?**

Institut za onkologiju Sarajevo

**Velda Smajlbegovi?**

Institut za onkologiju Sarajevo

**Nadja Kazic**

Institut za onkologiju Sarajevo

**Adnan Cardzic**

Institut za onkologiju Sarajevo