

A ruptured cornual ectopic pregnancy at 18 weeks' gestation: A case report

U Ince, M Osmana?ao?lu, H Bozkaya

Citation

U Ince, M Osmana?ao?lu, H Bozkaya. *A ruptured cornual ectopic pregnancy at 18 weeks' gestation: A case report*. The Internet Journal of Gynecology and Obstetrics. 2007 Volume 9 Number 2.

Abstract

A cornual pregnancy is an ectopic pregnancy that develops in the interstitial portion of the fallopian tube invading through the uterine wall. Cornual pregnancies often rupture later than other tubal pregnancies because the myometrium is more distensible than the fallopian tube. Increased vascularity associated with interstitial ectopic pregnancies is more likely to result in a catastrophic hemorrhage and death. The mortality rate of interstitial pregnancy is more than twice that of other tubal pregnancies. We report a case where cornual pregnancy was diagnosed at 18 weeks of gestation after uterine rupture and profound hemorrhage occurred. The patient underwent hysterectomy. Close monitoring of pregnancies in these patients is important to prevent a deleterious delay in treatment of a cornual pregnancy.

It's presented in the 7th International Congress of the Turkish-German Gynecological Association, Antalya, Turkey, May 16-20, 2007.

INTRODUCTION

Cornual pregnancy is a rare form ectopic pregnancy. Interstitial pregnancies account for 2–4 % of ectopic pregnancies and that 20 % of cases that advance beyond 12 weeks of gestation end in rupture [1].

We report a case where cornual pregnancy was diagnosed at 18 weeks of gestation after uterine rupture and profound hemorrhage occurred.

CASE REPORT

A 32-year multigravida, G:2, P:1, presented in our clinic with the complaint of an acute lower painful abdomen at 17 + 5 weeks of gestation. She had severe abdominal pain 4 hours before admission. Her temperature was 35.3 °C, blood pressure (BP) 70/40 mmHg and pulse rate 72 beats/min. The lower abdomen was firmly tender with rebound. On her pelvic examination slightly enlarged uterus and cervical tenderness on motion had been detected. The initial laboratory tests included haemoglobin 7.5 g/dL, hematocrit 22.3 %. Platelet count, bilirubin, alanine and aspartate transaminase and alkaline phosphatase were within normal limits. Her past medical was not history was not informative, she had had an uncomplicated normal spontaneous vaginal delivery at term. She had no risk factors for ectopic

pregnancy. On the abdominal ultrasonography, the endometrial cavity was empty and a 18-week-old viable fetus with gestational sac (FL: 24mm:17W1D, BPD: 39mm:18W) was depicted in the abdomen with massive free fluid. An emergency laparotomy was performed under general anesthesia. There was approximately 4000 ml of blood in the abdominal cavity

with a male fetus (15.25 cm length, 192 g) protruded from the right ruptured cornual region. The rupture measured about 12-13 cm in diameter, and placental tissue protruded through it (Figure1 and 2). Normal left fallopian tube and, both ovaries were seen. Hysterectomy was done. Peroperatively, in total she had received 5 units of red blood cells and 2 units of fresh frozen plasma. The postoperative course was uneventful, and she was discharged on postoperative day 6 in good condition.

Figure 1

Figure 1: Image of ruptured cornual ectopic pregnancy at 18 weeks' gestation

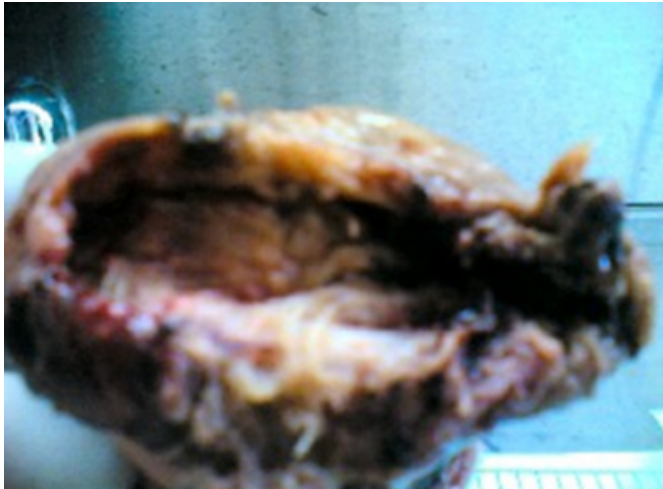
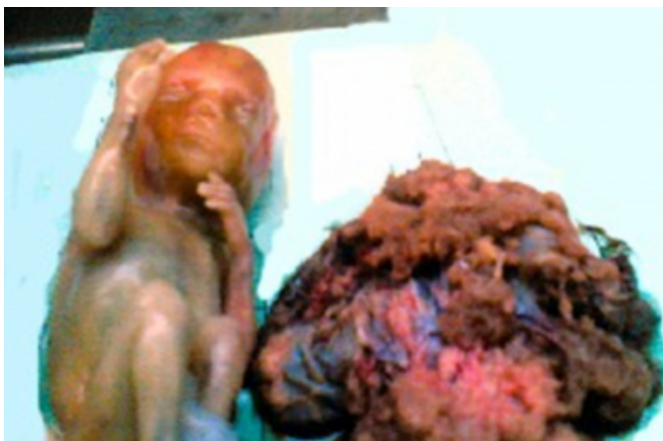

Figure 2

Figure 2: Image of fetus and placenta in ruptured cornual ectopic pregnancy at 18 weeks' gestation



DISCUSSION

The etiologic factors for cornual pregnancy are pelvic inflammatory disease, tumor, a high number of transferred embryos, a transfer near the uterine horn, excessive pressure on the syringe during the transfer, or difficulties during the ET procedure [2]. Bilateral salpingectomy is likely to be another risk factor for cornual pregnancy [3]. For nonsalpingectomized patients, peri- and intratubular adhesions, related or not related to endometriosis, are an additional risk factor. Certain authors also consider the quality of the embryos and the hormonal milieu at the moment of transfer as possible causes [4]. It is essential to remain vigilant in order to diagnose this occurrence as soon as possible if associated symptoms appear (e.g., vaginal

bleeding or pain) [5].

Cornual pregnancy is diagnosed with ultrasonographical criteria in the presence of a positive hCG level indicating pregnancy [6]. These criteria are: visualization of no gestational sac in the uterine cavity; illustrating an asymmetrically located gestational sac within the uterus (or in close proximity to the uterus); observing a thin myometrial layer surrounding the gestational sac or a thicker wall around the gestational sac. It has been also used transvaginal three-dimensional ultrasound scanning, with its capacity to reproduce the coronal plane of the uterus, facilitates exact localization of the gestational sac relative to the uterine cornu [7]. It's clear that the diagnosis of cornual pregnancy is dependent on the quality of ultrasound and the skills of investigator especially in hemodynamically stable patients. Cornual pregnancies often rupture later than other tubal pregnancies because the myometrium is more distensible than the fallopian tube. The intramural tubal segment lies in close proximity to the uterine artery and interstitial tubal rupture usually results in brisk hemorrhage and higher maternal morbidity and mortality rates than other ectopic pregnancies.

At a later gestation or after rupture, laparotomy with hysterectomy or cornual resection have been traditionally treated the cornual pregnancies. When an unruptured cornual pregnancy is diagnosed, there is a variety of conservative management options, such as medical management with methotrexate applied by parenteral route or directly injection of methotrexate or potassium chloride into the cornual gestational sac with ultrasonography guidance, laparoscopic cornual resection, and selective uterine artery embolization when conservative treatment with uterine preservation is desired [7,8,9]. In the previous reports, most of the authors used electric cauterization method for bleeding control and cornual incision. Some authors performed cornual resection without suturing the myometrial defect [10]. One of the major advantages of conservative treatment of cornual pregnancy is the preservation fertility and the key disadvantage is the risk of uterine rupture during the subsequent pregnancy. The method of deep cornual resection has an accepted risk for uterine rupture for the subsequent pregnancy [11]. In our case, because of the advanced condition of the pregnancy, the cornual was found to be largely ruptured with massive hemorrhage in the abdominal cavity. Therefore no other conservative therapeutic methods seemed possible. According to Brever H et al. [12], this case demonstrates the importance of maintaining a suspicion for ectopic pregnancy

at advanced gestational ages and for uterine rupture even in the absence of symptoms.

CORRESPONDENCE TO

Dr. Mehmet A. OSMANAĞAOĞLU Karadeniz Technical University Faculty of Medicine Department of Obstetrics and Gynecology 61080 Trabzon / TURKEY Tel : +90 (462) 377 54 19 Fax : +90 (462) 325 05 18 e-mail : osmanaga@meds.ktu.edu.tr

References

1. Lau S, Tulandi T. Conservative medical and surgical management of interstitial ectopic pregnancy, *Fertil Steril* 1999;72: 207-215.
2. Chang Y, Lee JN, Yang CH, Hsu SC, Tsai EM. An unexpected quadruplet heterotopic pregnancy after bilateral salpingectomy and replacement of three embryos, *Fertil Steril* 2003;80: 218-220.
3. Agarwal SK, Wisot AL, Garzo G, Meldrum DR. Cornual pregnancies in patients with prior salpingectomy undergoing in vitro fertilization and embryo transfer, *Fertil Steril* 1996;65: 659-660.
4. Pan HS, Chuang J, Chiu SF, Hsieh BC, Lin YH, Tsai YL, Huang SC, Hsieh ML, Chen CY, Hwang JL. Heterotopic triplet pregnancy: report of a case with bilateral tubal pregnancy and an intrauterine pregnancy. *Hum Reprod* 2002;17: 1363-1366.
5. Divry V, Hadj S, Bordes A, Genod A, Salle B. Case of progressive intrauterine twin pregnancy after surgical treatment of cornual pregnancy. *Fertil Steril* 2007;87:190.e1-3.
6. Graham M, Cooperberg PL. Ultrasound diagnosis of interstitial pregnancy: findings and pitfalls. *J Clin Ultrasound* 1979;7: 433-437.
7. Valsky DV, Hamani Y, Verstandig A, Yagel S. The use of 3D rendering, VCI-C, 3D power Doppler and B-flow in the evaluation of interstitial pregnancy with arteriovenous malformation treated by selective uterine artery embolization. *Ultrasound Obstet Gynecol* 2007;29: 352-355.
8. Tulandi T, Vilos G, Gomel V. Laparoscopic treatment of interstitial pregnancy. *Obstet Gynecol* 1995;83: 465-467.
9. Woodland MB, Depasquale SE, Molinari JA, Sagullo CC. Laparoscopic approach to interstitial pregnancy. *J Am Assoc Gynecol Laparosc* 1995;3: 439-441.
10. Gezer A, Mutlu H. Laparoscopic management of cornual pregnancy without sutures *Arch Gynecol Obstet* 2004;270: 194-196.
11. Moon HS, Choi YJ, Park YH, Kim SG. New simple endoscopic operations for interstitial pregnancies. *Am J Obstet Gynecol* 2000;182:114-121.
12. Brewer H, Gefroh S, Munkarah A, Hawkins R, Redman ME. Asymptomatic uterine rupture of a cornual pregnancy in the third trimester: a case report. *J Reprod Med* 2005;50: 715-718.

Author Information

Ulku Ince, MD

Resident in Karadeniz Technical University, Department of Obstetrics and Gynecology, Faculty of Medicine, Karadeniz Technical University

Mehmet A. Osmana?ao?lu, MD

Assistant Professor, Obstetrics & Gynecology, Faculty of Medicine, Karadeniz Technical University

Hasan Bozkaya, MD

Professor, Obstetrics & Gynecology, Faculty of Medicine