

# The Emergency Management of Renal and Ureteric Colic

R Bhogal, M Jeganathan, M Pierdies, C Rennie

## Citation

R Bhogal, M Jeganathan, M Pierdies, C Rennie. *The Emergency Management of Renal and Ureteric Colic*. The Internet Journal of Urology. 2005 Volume 3 Number 2.

## Abstract

Renal or ureteric colic is often the presumed diagnosis given to many patients presenting with acute loin and/or groin pain. Patients frequently undergo a multitude of investigations before a diagnosis is established. This often leads to a delay in appropriate management.

We assessed the emergency management of patients with suspected renal and/or ureteric colic referred to our department. All referrals over a three-month period were included in the study. We found the majority of referrals with suspected urinary tract stones do in fact have an alternative diagnosis. CT was the most sensitive method for establishing diagnosis in patients with acute loin and/or groin pain. We recommend that patients with suspected renal or ureteric colic should undergo CT on admission to confirm the diagnosis and ensure suitable management.

## INTRODUCTION

Patients with suspected renal and ureteric colic are a common referral made to acute urological services<sup>1</sup>. However many abdominal pathologies can present with similar symptoms. Consequently some patients undergo numerous investigations in order for diagnosis to be established.

It is generally accepted that renal tenderness, pain of less than 12 hours duration and microscopic haematuria suggest the diagnosis of renal or ureteric colic<sup>2</sup>. However the presence of microscopic haematuria does not accurately exclude other intra-abdominal as the cause of the patient's pain<sup>3</sup>. Therefore it is imperative that patients are correctly assessed and investigated. Once the diagnosis of renal or ureteric stone has been established the size and position of the stone determines the management of the patient<sup>4</sup>.

This study assessed whether patients referred to our department were being appropriately referred, investigated and managed.

## METHODS

In this prospective study all patients referred to acute urological services with suspected renal or ureteric colic over a three-month period were included. Patients with known urinary tract stones were excluded.

Patient demographics, duration of symptoms, results of in-

patient tests and subsequent radiological investigations were also recorded.

## RESULTS

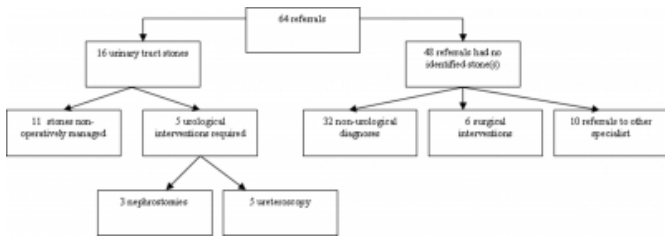
64 patients were referred to our department with suspected renal or ureteric colic from March to June 2005. They had a median age of 44 years and 42% were female. 76% of referrals were from Accident and Emergency department, 19% from general practitioners and the 5% from other medical specialties.

All patients were referred with loin and/or groin pain. The duration of the pain ranged from 7 hours to 39 days. 62% of patients had microscopic haematuria. Of note 8 patients had no urinalysis recorded prior to referral. Mid Stream Urine (MSU) sample was not to be sent in 23 patients.

16 patients (25%) had either renal or ureteric stones (Fig. 1). 13 of these had microscopic haematuria. 2 had no urinalysis recorded and 1 had no evidence of microscopic haematuria.

**Figure 1**

Figure 1: Diagnosis reached on patients presenting with suspected renal and ureteric colic.



11 patients with stones were managed conservatively and followed up with outpatient IVU. 7 had renal stones whilst 4 had ureteric stones less than 3 mm.

5 patients with urinary tract stones required in-patient intervention. All had ureteric stones (Table 1). Three patients had pyonephrosis as evidenced by associated pyrexia, rigors and/or leucocytosis. These patients required emergent decompression of the urinary tract obstruction with percutaneous nephrostomy tube prior to ureteroscopy and stone extraction. Of note three of the patients had stones identified only after CT-KUB.

**Figure 2**

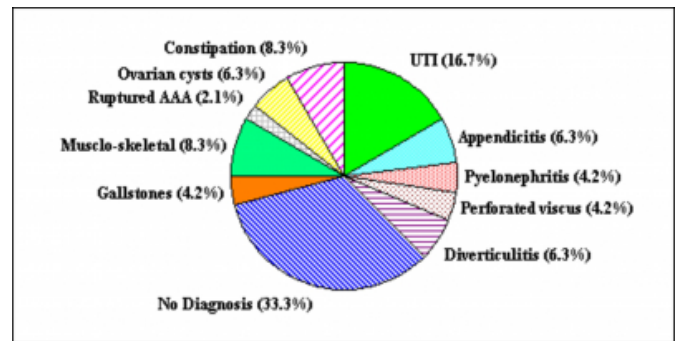
Table 1: Details of patients requiring in-patient intervention for urinary tract stones

Age (years)	Stone on KUB	Stone on USS	CT-KUB	Stone size (mm)	Position of stone	Intervention	
						Nephrostomy	Ureteroscopy
71	Y	Y	Not done	7	Right VUJ	Y	Y
27	N	N	Y	4	Left VUJ	N	Y
58	N	Y	Y	8	Right upper ureter	Y	Y
54	N	N	Y	5	Left upper ureter	Y	Y
37	N	N	Y	6	Left VUJ	N	Y

48 patients (75%) had no identifiable urinary tract stones to account for their symptoms (Fig. 2). 6 patients required emergent surgery that included 3 appendectomies, 2 laparotomies for perforated viscus and 1 repair of ruptured abdominal aortic aneurysm. Interestingly, of these six patients 4 had associated microscopic haematuria. In the 16 patients where a diagnosis was not established 7 had no urinalysis and MSU recorded.

**Figure 3**

Figure 2: Non-Urological diagnosis in patients with no identifiable urinary tract stones



Only 7% of the KUBs detected renal and/or ureteric stones compared to 16% of ultrasound scan (Table 2). 5 patients, who had no stone identified on KUB and USS, only had stones identified after CT-KUB. 3 of these patients required in-patient intervention. In addition CT was able to establish extra-urinary tract pathologies such as ruptured abdominal aortic aneurysm.

**Figure 4**

Table 2: Number of investigations performed on patients with suspected renal and/or urteric colic

Investigation	Number performed	Number of stones detected	Number of patients requiring further investigation	Number of Extra-urinary tract pathology detected
KUB	55	4	47	1
USS	44	7	31	2
CT-KUB	19	13	0	5

**DISCUSSION**

The majority of patients referred as renal and/or ureteric colic do not have stones. Urinalysis and MSU is not routinely performed in patients with suspected renal or ureteric colic. This is particularly important because as this study shows UTIs may account for many patient referrals. The routine utilisation basic tests, such as urinalysis, may prevent unnecessary admissions. Furthermore microscopic haematuria and abdominal pain do not accurately predict the presence of a renal or ureteric stone. Indeed as this study highlights patients with perforated viscus, leaking abdominal aortic aneurysm and appendicitis can have microscopic haematuria associated with acute abdominal pain.

Many patients with an acute abdomen required CT investigation. This was the most sensitive method to detect urinary tract stones as well as extra-urinary tract pathology. KUB and USS even when performed in combination failed to reveal the cause of loin and/or groin in a vast majority of

patients. As our study confirms ureteric stones of 5 mm or greater will generally require intervention and in some cases emergent in-patient treatment.

As previous authors have suggested, we recommend that patients with acute abdominal pain should undergo CT imaging on admission<sup>5,6</sup>. This will aid diagnosis and ensure correct management of the patient.

### **CONCLUSION**

Patients referred with the presumed diagnosis of renal or ureteric colic often have a non-urological cause for their pain. These patients should undergo CT scanning on admission to confirm diagnosis and aid appropriate admission and intervention. Routine investigation such as urinalysis whilst not being accurate markers for the presence of urinary tract stones can prevent unnecessary admission and investigation by detecting alternative diagnosis.

### **References**

1. Morris SB, Hampson SJ, Gordon EM, Shearer RJ, Woodhouse RJ. Should All Patients With Ureteric Colic Be Admitted? *Annals Of The Royal College of Surgeons Of England*. 1995; 77: 450-452
2. Eskelinen M. Usefulness of History-Taking, Physical Examination And Diagnostic Scoring In Acute Renal Colic. *European Journal of Urology*. 1998; 34: 467-473
3. Bove P, Kaplan D, Dalrymple N, Rosenfield AT, Verga M, Anderson K, Smith RC. Reexamining The Value of Haematuria Testing In Patients With Acute Flank Pain. *Journal of Urology*. 1999; 162: 685-687.
4. O'Flynn JD. The Treatment Of Ureteric Stones: Report on 1120 Patients. *British Journal of Urology*. 1980; 52: 436-438
5. Chen MY, Zagoria RJ. Can Non-Contrast Helical Computed Tomography Replace Intravenous Urography For Evaluation Of Patients With Acute Urinary Tract Colic. *Journal of Emergency Medicine*. 1999; 17: 299-303
6. Dalrymple NC, Verga M, Anderson KR, Bore P, Covey AM, Rosenfield AT, Smith RC. The Value Of Unenhanced Helical Computerized Tomography In The Management Of Acute Flank pain. *Journal of Urology*. 1998; 159: 735-740

**Author Information**

**Ricky Bhogal, MRCS**

SHO Urology, Department of Urology, Alexandra Hospital NHS Trust

**Mugathan Jeganathan, MBBS**

PRHO Urology, Department of Urology, Alexandra Hospital NHS Trust

**Michael Pierdies, MB ChB**

PRHO Urology, Department of Urology, Alexandra Hospital NHS Trust

**Christopher Rennie, FRCS (Urol)**

Consultant Urologist, Department of Urology, Alexandra Hospital NHS Trust