

# Reconstruction Of Upper And Lower Lips And Mandible With Multiple Flaps Following Resection Of Extensive Squamous Cell Carcinoma

R Ng, J Potochny, J Lemon, J Myers, D Chang

## Citation

R Ng, J Potochny, J Lemon, J Myers, D Chang. *Reconstruction Of Upper And Lower Lips And Mandible With Multiple Flaps Following Resection Of Extensive Squamous Cell Carcinoma*. The Internet Journal of Plastic Surgery. 2002 Volume 1 Number 2.

## Abstract

The reconstruction of composite defects of the mandible and both lips following oncological resection is challenging from both functional and aesthetic perspectives. This is a case report of simultaneous and immediate reconstruction of combined upper and lower lips and mandible with multiple flaps following resection of extensive squamous cell carcinoma. The patient was reconstructed with free fibula osteocutaneous flap, pedicled scalp flap, tongue flap, palmaris longus tendon sling and pectoralis major myocutaneous flap. At 4 weeks, patient demonstrated good speech and swallowing with an acceptable aesthetic result.

## INTRODUCTION

The reconstruction of composite defects of the mandible and both lips following oncological resection is challenging (1). Structural restoration of skeletal support, internal lining and external skin cover must take into account the functional goals of oral competence, the ability to eat and drink, and intelligible speech. Functional restoration may involve neurotomy to restore sensory or motor function, the use of static slings to support soft tissue reconstruction, or the transfer of skeletal muscle to restore oral sphincteric function. Aesthetic considerations also dictate that the reconstruction should attempt to minimize or at least camouflage the extent of disfigurement resulting from such extensive surgery (2).

## CASE HISTORY

A 56 year-old white male with a history of heavy alcohol and tobacco use presented with a 14-month history of an enlarging lesion involving the upper and lower lips.

Video 1: Survey of lesion

Examination revealed an ulcerating exophytic lesion involving the entire lower lip, right two-thirds of the upper lip, floor of mouth, right lower alveolus, buccal mucosa, and skin of the chin and right cheek. The tongue was mobile and unrestricted. There was numbness in the mental area, and palpable bilateral cervical lymphadenopathy at Levels and II.

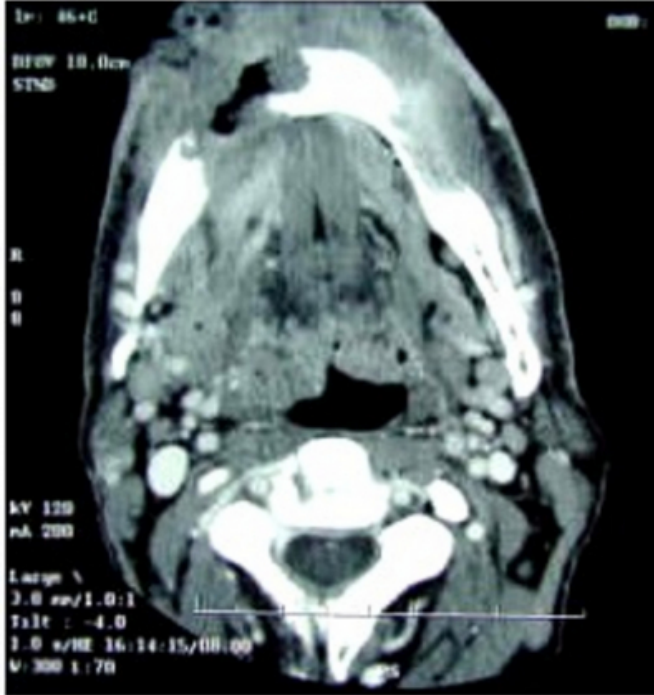
Video 2: Function

The patient wore ill-fitting dentures and was maintaining his weight through a soft diet. His speech was intelligible.

# Reconstruction Of Upper And Lower Lips And Mandible With Multiple Flaps Following Resection Of Extensive Squamous Cell Carcinoma

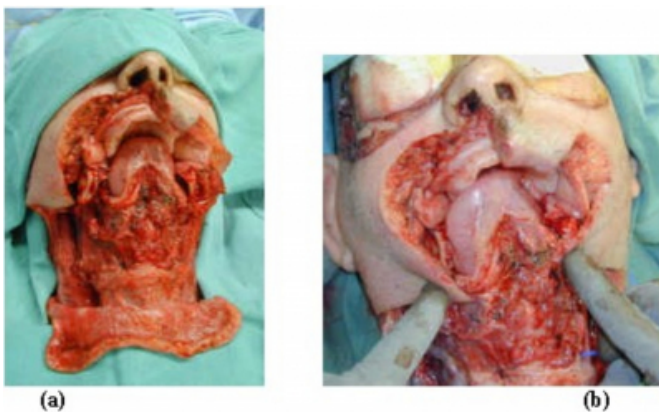
**Figure 1**

Figure 1: CT scan revealed destructive changes in the right mandible back to the angle, and enlarged lymph nodes to Level III. There was no evidence of distant metastases. The patient was clinically staged T4N2cM0.



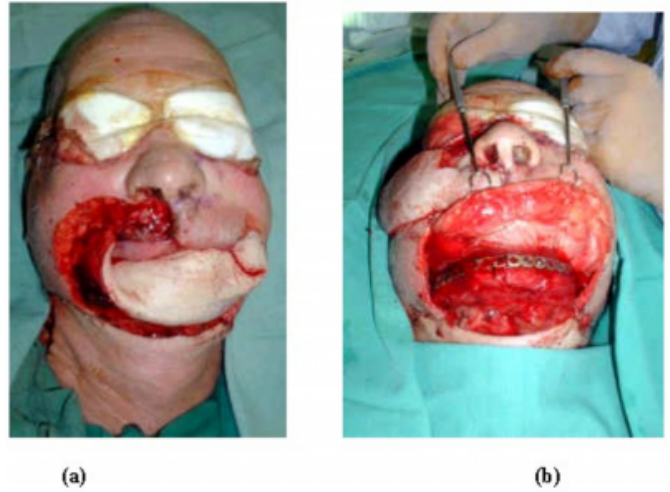
**Figure 2**

Figure 2 a & b: Composite resection with a 2 cm margin was performed of both lips and the mandible from left mid-body to right angle, with right Level I-IV and left Level I-III selective neck dissections. Two cm of left upper lip was preserved.



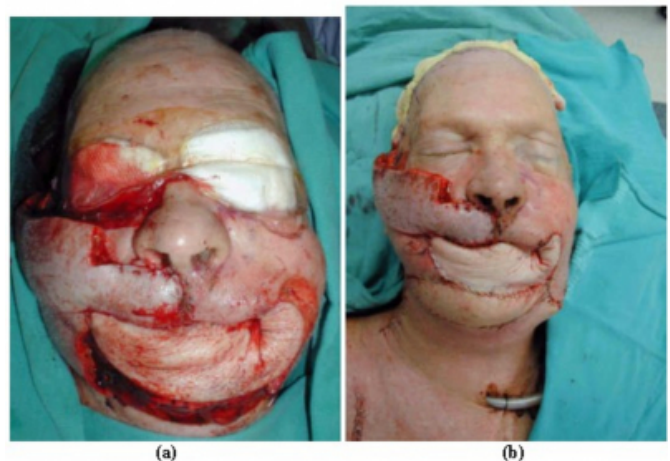
**Figure 3**

Figure 3 a & b: A free fibula osteocutaneous flap with 14 cm of bone and a 20 x 8 cm skin paddle was used to reconstruct the mandible, intra-oral lining and lower lip externally. Microvascular anastomosis was performed to the facial vessels. A palmaris longus tendon sling was used to suspend the lower lip reconstruction. A pedicled tongue flap was used to provide vermilion and mucosal lining for the right upper lip reconstruction.



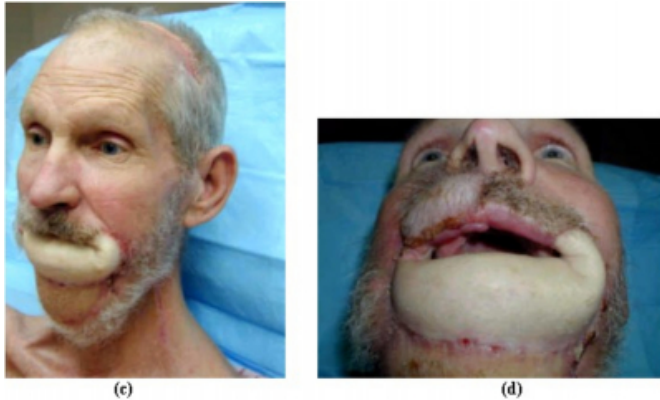
**Figure 4**

Figure 4 a & b: The right upper lip was reconstructed with a pedicled scalp flap to provide hairy skin externally, with the pedicled tongue flap (Figure 3a) providing vermilion and mucosal lining. Finally a residual skin defect over the chin was reconstructed with a pectoralis major myocutaneous flap.



**Figure 5**

Figure 5 a – d: Three weeks later, pedicle division and inseting of the scalp and tongue flaps was performed, and these photographs demonstrate the result at 6 weeks' postoperatively.



Video 3 & 4: Speech discussing diet and back to work

The patient had intelligible speech, was tolerating a soft diet, and was looking forward to resuming work as a laborer after completion of his adjuvant radiotherapy.

**DISCUSSION**

Local flaps for lip reconstruction such as the Karapandzic flap (3) satisfy the twin goals of restoring structural integrity and functional competence in the oral sphincter. However, the extent of resection in this case, leaving only 20% of the upper lip intact, clearly precluded this option, and free tissue transfer was necessary, possibly with multiple free flaps (4,5,6,7), or a combination of free and other pedicled distant flaps.

Restoration of skeletal support required a length of donor bone that, with osteotomies, could span the defect from the left mid-body to the right angle of the mandible. In this regard, the free fibula osteocutaneous flap was the option of choice (8). The flap provides good quality cortical bone of up to 25 cm in length, which is also amenable to osseointegrated dental implants if appropriate. A large cutaneous paddle can be harvested, which, in this case, was not only sufficient for restoration of lining to the floor of the mouth, but was also large enough to reconstruct the entire lower lip and left oral commissure. A double-paddle flap design, with separate components for lining and skin (9, 10) was contemplated, but thought not to be necessary. Had the skin paddle of the free fibula flap been insufficient, a second free flap such as the radial forearm flap could have been utilized, either as a flow-through chimaeric flap (11, 12), or re-

vascularised by a second set of recipient vessels.

Restoration of muscle by transposition of the masseter muscles (13), or by incorporating the brachioradialis muscle into a free radial forearm flap (14) have been reported in the literature. This was not attempted in our patient, and in the absence of functional muscle to restore oral competence, a palmaris longus tendon graft, secured to the zygomas, was utilized as a sling to support the lower lip margin (15, 16).

Reconstruction of the upper lip was aided by the fact that in the male patient, a hairbearing scalp flap can provide an aesthetically acceptable neo-moustache as part of the upper lip reconstruction (17, 18). Utilization of the tongue flap to provide lining to the upper lip reconstruction potentially produced a donor site deficit in the tongue, which had otherwise been entirely spared by the oncological resection. However, as the postoperative videos demonstrate, his speech and swallowing functions have not been compromised.

**References**

1. Urken MI, Weinberg H, Vickery C, Buchbinder D, Lawson W, Biller HF. Oromandibular reconstruction using microvascular composite free flaps: report of 71 cases and a new classification scheme for bony, soft-tissue and neurologic defects. *Arch Otolaryngol head Neck Surg* 1991; 117: 733-744.
2. Wei FC, Tan BK, Chen IH, Hau SP, Liau CT. Mimicking lip features in free-flap reconstruction of lip defects. *Br J Plast Surg* 2001; 54: 8-11.
3. Karapandzic M. Reconstruction of lip defects by local arterial flaps. *Br J Plast Surg* 1974; 27: 93-97.
4. Sanger JR, Yousif NJ, Matloub HS, Larson DL, Sewall SS. Reconstruction of lower third of face with three simultaneous free flaps. *Plast Reconstr Surg* 1994; 94: 709-713.
5. Kuzon WM, Jejurikar S, Wilkins EG, Swartz, WM. Double free-flap reconstruction of massive defects involving the lip, chin and mandible. *Microsurg* 1998; 18: 372-378.
6. Wei FC, Demirkan F, Chen HC, Chen IH. Double free flaps in reconstruction of extensive composite mandibular defects in head and neck cancer. *Plast Reconstr Surg* 1999; 103: 39-47.
7. Burt JD, Burns AJ, Muzaffar AR, Byrd HS, Hobar PC, Beran SJ, Adams WP, Kenkel J. Total soft-tissue reconstruction of the middle and lower face with multiple simultaneous free flaps in a pediatric patient. *Plast Reconstr Surg* 2000; 105: 2440-2452.
8. Hidalgo DA. Fibula free flap mandibular reconstruction. *Clin Plast Surg* 1994; 21: 25-35.
9. Yang KC, Leung JK, Chen JS. Double-paddle peroneal tissue transfer for oromandibular reconstruction. *Plast Reconstr Surg* 2000; 106: 47-55.
10. Boorman JG, Green MF. A split Chinese forearm flap for simultaneous oral lining and skin cover. *Br J Plast Surg* 1986; 39: 179-182.
11. Sanger JR, Matloub HS, Yousif NJ. Sequential connection of flaps: A logical approach to customized

## **Reconstruction Of Upper And Lower Lips And Mandible With Multiple Flaps Following Resection Of Extensive Squamous Cell Carcinoma**

---

- mandibular reconstruction. *Am J Surg* 1990; 160: 402-404.
12. Wells MD, Luce EA, Edwards AL, Vasconez HC, Sadove RC, Bouzagloul S. Sequentially linked free flaps in head and neck reconstruction. *Clin Plast Surg* 1994; 21: 59-67.
13. Shinohara H, Iwasawa M, Kitazawa T, Kushima H. Functional lip reconstruction with a radial forearm free flap combined with a masseter muscle transfer after wide total excision of the chin. *Ann Plast Surg* 2000; 45: 71-73.
14. Takada K, Sugata T, Yoshiga K, Miyamoto Y. Total upper lip reconstruction using a free radial forearm flap incorporating the brachioradialis muscle. *J Oral Maxillofac Surg* 1987; 45: 959-962.
15. Sadove R, Luce E, McGrath P. Reconstruction of the lower lip and chin with the composite radial forearm-palmaris longus free flap. *Plast Reconstr Surg* 1991; 88:209-214.
16. Carroll CMA, Pathak I, Irish J, Neligan PC, Gullane PJ. Reconstruction of total lower lip and chin defects using the composite radial forearm-palmaris longus tendon free flap. *Arch Facial Plast Surg* 2000; 2: 53-56.
17. Wilson JSP, Galvao MSL, Brough MD. The application of hair-bearing flaps in head and neck surgery. *Head and Neck Surg* 1980; 2: 386-406.
18. Jacob OJ. Reconstruction of total loss of upper lip with hair-bearing flaps. *Aus NZ J Surg* 1995; 65: 251-253.
19. Nath S, Jovic G. Total loss of upper and lower lips: challenges in reconstruction. *Br J Oral Maxillofac Surg* 1998; 36: 460-461.
20. Koshima I, Inagawa K, Urushibara K, Moriguchi T. Combined submental flap with toe web for reconstruction of the lip with oral commissure. *Br J Plast Surg* 2000; 53: 616-631.

**Author Information**

**Roy L. H. Ng**

Department of Plastic and Reconstructive Surgery, M. D. Anderson Cancer Center

**John Potochny**

Department of Plastic and Reconstructive Surgery, M. D. Anderson Cancer Center

**James Lemon**

Department of Plastic and Reconstructive Surgery, M. D. Anderson Cancer Center

**Jeffrey Myers**

Department of Plastic and Reconstructive Surgery, M. D. Anderson Cancer Center

**David W. Chang**

Department of Plastic and Reconstructive Surgery, M. D. Anderson Cancer Center