

# Ethanollic Extracts Of Vernonia Amygdalina And Ocimum Gratissimum Enhance Testicular Improvement In Diabetic Wistar Rats

O ASUQUO, A EDET, O MESEMBE, J ATANGHWO

## Citation

O ASUQUO, A EDET, O MESEMBE, J ATANGHWO. *Ethanollic Extracts Of Vernonia Amygdalina And Ocimum Gratissimum Enhance Testicular Improvement In Diabetic Wistar Rats*. The Internet Journal of Alternative Medicine. 2009 Volume 8 Number 2.

## Abstract

To study the effects of ethanollic extracts of Vernonia amygdalina and Ocimum gratissimum on the testes of diabetic rats, forty male rats were used. Group A consisted of eight (8) rats which served as non-diabetic control. The remaining rats were injected intraperitoneally with streptozotocin to induce diabetes. The rats confirmed diabetic were randomly divided into four experimental groups (B, C, D and E) made up of eight rats each. Group B served as the diabetic control and were given normal saline. Groups C, D and E received 200mg/kg body weights of Vernonia amygdalina (VA), Ocimum gratissimum (OC) and a combination of VA and OC respectively. This investigation lasted for 28 days. Results revealed normal testicular architecture in the normal control. Diabetic control exhibited alteration of germinal epithelium, distortion of seminiferous tubules as well as vacuolation of seminiferous tubules. The effects of the extracts on diabetic rats' testes showed improvements compared to the diabetic control group. These improvements were more pronounced in the group D rats which received OC than in group C treated with VA. A more appreciable testicular improvement was observed in group E treated with combination of the extracts of VA and OC. We therefore conclude that the use of the extracts of these plants should be used in combination as they exert a better improvement to combat the adverse effects of diabetes on the testes of male rats.

## INTRODUCTION

The utilization of herbal extract from plants found in fields and forests to treat various types of illnesses and diseases has increased over the years<sup>1</sup>. Vernonia amygdalina (VA) and Ocimum gratissimum (OG) are among the plants whose extracts are utilized<sup>2</sup>. The parts of the plants mostly used are the leaves, usually fresh to obtain optimum result<sup>3,4</sup>. VA is used for a wide range of ailments such as constipation, fever, purgative, worm remover and against urinary inflammation in local medicine<sup>5</sup>. OG has been used as a medicinal plant in the treatment of headache, diarrhea, and wart and kidney function<sup>6,7</sup>. VA and OG are used in the treatment of diabetes by tradomedical practitioners and natives of Cross River State. Other uses of these herbs are as insect repellent, smell disguiser and for colic<sup>8</sup>, antimicrobial<sup>9</sup>, antifungal<sup>10</sup>, antiprotozoal and antimalarial<sup>11</sup>. Diabetes mellitus is the most common endocrine disease caused by deficiency in the secretion or action of insulin<sup>12</sup>. The increasing number of aging population, consumption of calorie-rich diet, obesity and sedentary life style has led to an alarming increase in the number of diabetics Worldwide<sup>13,14</sup>. Diabetes has gradually

found its root in Africa, especially in Nigeria where Westernized ways are imbibed; this disease has a significant effect on male reproductive function as the incidence of diabetes among men attending infertility clinics is on the increase<sup>15</sup>; this suggested the use of the herbs on animal models for their efficacy. The risk factors for developing erectile dysfunction are neuropathy, blood vessel damage and poor blood sugar control<sup>16</sup>. Streptozotocin (STZ) was found to be selectively toxic to the beta cells of the pancreatic islet, and this suggested the drug's use as an animal model of type 1 diabetes mellitus<sup>17</sup>. Type I diabetes formerly known as insulin dependent diabetes mellitus or juvenile onset diabetes mellitus is characterized by severe or absolute lack of insulin caused by reduction in, or complete destruction of  $\beta$ -cell mass<sup>18</sup>. The trigger of the  $\beta$ -cell mass reduction or destruction has not been elucidated<sup>19,20</sup>. Despite the uncertainty in the etiology, three mechanisms have been speculated; genetic susceptibility, anti-immunity and environmental insults<sup>18,21,22</sup>. These mechanisms have been found to act jointly and in a sequence leading to an eventual destruction of  $\beta$ -cells, then diabetes<sup>23</sup>. Although studies have

reported hypoglycemic effects of VA<sup>24</sup>, there is no reference in literature to the possible testicular improvement of the plant extract in human or animal studies. The present study was carried out to establish the probable effects of VA and OG on the testes of diabetic rats.

## MATERIALS AND METHODS

Vernonia amygdalina (VA) and Ocimum gratissimum (OG) were harvested from the University of Calabar farm and authenticated at the Department of Botany, University of Calabar. Fresh and matured leaves of VA and OG were rinsed, dried under shade at room temperature ( $28 \pm 3$  C). The dried leaves were ground with an electric blender. 426g of the powder was soaked in 80% ethyl alcohol and agitated thoroughly for about 5 minutes. The mixture was left to stand for 48 hours in a thermocool refrigerator at 4C. The mixture was filtered first with a chess cloth and later with Whartman's paper (NO 1), and left to stand overnight. The final filtrates were concentrated in-vacuo in a rotary evaporator at 37C the extracts were dried. The percentage yields of extracts were estimated to have a mean yield of  $40.28 \pm 1.25$ g w/w for VA and  $39.42 \pm 1.08$ g w/w for OG. The extracts were stored in air-tight containers at -4C. Male Wistar rats of an average weight of 130g were used. The animals were kept in a well ventilated room and were fed growers mash (Vital feed Nig Ltd) and water ad libitum. A total of forty rats were randomly divided into five groups of eight rats each. Group A served as normal control, group B were diabetic control. These groups received normal saline. Groups C, D and E were made up of diabetic rats. Diabetes was induced using 65mg/kg body weight (bw) of Streptozotocin (STZ). Group C were treated with 200mg/kg bw of VA, group D received 200mg/kg bw of OG and group E were given 200mg/kg bw of VA and OG at 100mg/kg each. This administration lasted for 28 days. The rats were sacrificed at the end of administration, testes were rapidly excised and fixed in Bouin's fluid for 24 hours and processed for paraffin sections. Sections were cut at 5 $\mu$ m with a rotary microtome. Sections were stained with haematoxylin and eosin. Photomicrographs were taken.

## RESULTS

Sections of testes of control rats showed normal testicular architecture with distinct seminiferous tubules composed of both Sertoli and spermatogenic cells. The spermatogenic cells were seen to be at the spermiogenic stage of differentiation. Interstitial cells of Leydig were also prominently interspersed between the seminiferous tubules

(fig i). The diabetic control showed alteration and distortion of both germinal epithelium and seminiferous tubules. The peritubular tissue surrounding the seminiferous tubules and interstitial cells were altered. There was presence of vacuoles within the seminiferous tubules (fig ii). The testes of group C treated with VA had a more stable seminiferous tubules compared to group B. Vacuoles were observed, but were not numerous as those observe in the diabetic control. Few spermatogenic and Sertoli cells were found in the testes of these rats (fig iii). Group D rats' testes treated with OG showed a better improvement; distinct seminiferous tubules were observed. Numerous boundary cells as well as Sertoli cells were found in their lining epithelium. Blood vessels were seen in the connective tissue of the seminiferous tubules (fig iv). The testes of group E rats treated with combination of VA and OG showed a significant improvement of testicular arrangement. There was increase in Leydig cells; well defined seminiferous tubules were seen. Lumen of seminiferous tubules was filled with active spermatids.

Fig i Photomicrograph of testis of control group A rats showing normal testicular architecture. Spc- spermatogenic cells, Sp- spermatids, St- Sertoli cells, Lc- Leydig cells.

### Figure 1

Fig i

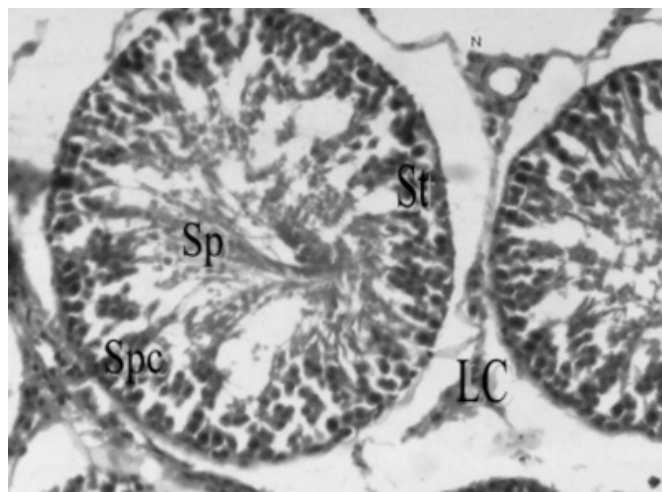


Fig ii Photomicrograph of testis of group B diabetic-induced rats showing testicular damage. Dsc-degenerating spermatogenic cells, Bst-broken sperm tails, LLC- lost Leydig cells.

**Figure 2**

Fig ii

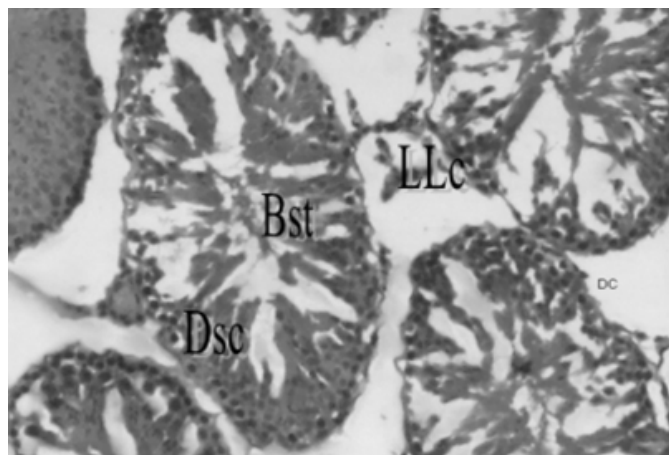


Fig iii Photomicrograph of testis of group C diabetic rats treated with Vernonia amygdalina showing improvement. Dsp- developing spermatogonia, DLc- developing Leydig cells.

**Figure 3**

Fig iii




Fig iv Photomicrograph of testis of group D diabetic rats treated with Ocimum gratissimum showing an improved testicular arrangement. Spg- spermatogonia, Rst- regenerating Sertoli cells, Lc-Leydig cells.

**Figure 4**

Fig iv

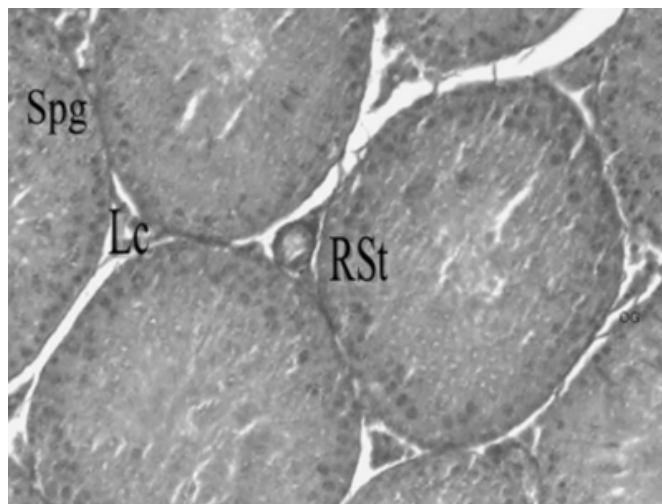
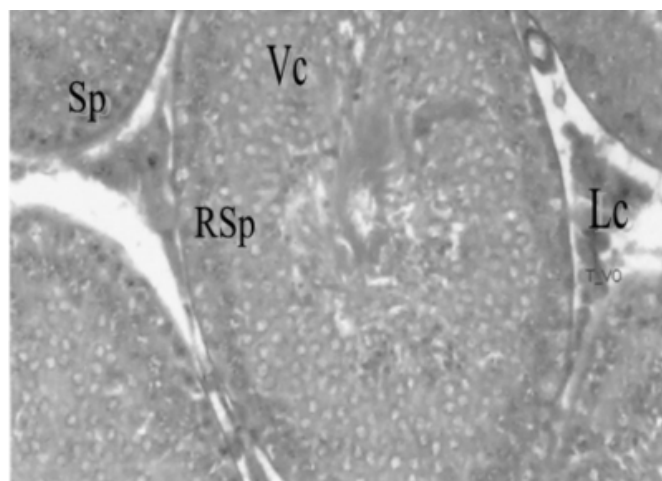


Fig v Photomicrograph of testis of group E diabetic rats treated with combination of Vernonia amygdalina and Ocimum gratissimum showing RSp-regenerated spermatogenic cells, Vc-vacuoles, Sp-spermatogonia, Lc-Leydig cells.

**Figure 5**

Fig v



## DISCUSSION

The incidence of diabetes among men attending fertility clinics and among men who are subfertile is high<sup>25</sup>. Since antiquity, diabetes has been treated with herbs; recent scientific investigations have confirmed the efficacy of these herbal preparations which are remarkably cheap and non-toxic<sup>26</sup>. The hypoglycemic effect of Vernonia amygdalina (VA) had been documented<sup>24</sup>. The use of Ocimum gratissimum (OC) as an anti-diabetic agent has not been well documented, however, it is popularly used for the treatment

of diarrhea, headache, wart, worm and kidney function<sup>6,7,27</sup>. In cross River State, Nigeria, Traditional practitioners use both extracts in combination for the treatment of diabetes. Literature abounds on the uses of VA, the leaves have found relevance as an antihelmints, a laxative herb and an anti-malarial as it is known as quinine substitute<sup>28</sup>. Phillipson et al<sup>29</sup> have also reported the anti-plasmodial effects of some sesquiterpernes and steroidal constituents of VA. Hypoglycemic effect of VA had been reported<sup>30</sup> which may be due to the presence of bioactive agents isolated from the plant<sup>31</sup>. Nevertheless, some untoward effects of VA had been reported which indicated the haemolytic effect of the saponin fractions of the extract<sup>32</sup>. Ibrahim et al<sup>33</sup> reported a significant reduction in body weight of Wistar rats on chronic feeding with leaves of VA. They also reported that the nephritic, hepatic and testicular cells architecture were normal. This is in support of our finding that VA does not have a deleterious effect on the testes of diabetic rats, but rather led to an improvement of its cytoarchitecture. Regeneration of testicular tissue observed in our work after a combined administration of VA and OG may suggest that these plants have antioxidant properties that can mop up free radicals produced by streptozotocin. This is in conformity with work carried out by Igile et al<sup>34</sup> where certain phytochemicals of VA were isolated and their antioxidant properties were demonstrated. Although little information is available on the effect of OG on diabetes, from our study, it was found that OG had a more positive and potent effect on the testes of diabetic rats compared to VA. This may be due to the high level of alkaloids and flavonoids found in OG. Alkaloids are known as the starting material in the manufacture of steroidal drugs<sup>35</sup>. Flavonoids are functional as disease resistant; OG also contains tannins that inhibit oxidation<sup>36</sup>. These components of OG put together may be responsible for the result obtained. The alkaloids may have triggered the production of testosterone, flavonoids may have acted by resisting the effect of diabetes and tannins may have inhibited oxidation by acting as an antioxidant. These potent properties of OG may have likely influenced the almost near to normal regenerative effects of testicular tissue observed in the group given combination of VA and OG. Since the effect of the combination is more promising than in the single administration, we conclude that the use of both VA and OG work in synergism to produce endowed potentials which can be exploited in the development of anti-diabetic drugs that can be used as supplements.

## References

1. Rates SM. 2001. Plants as source of Drugs. *Toxicon*. 39(5): 603-613.
2. Sofowora A. 1993. Medicinal plants and traditional medicine in Africa. 2nd ed. Spectrum book Ltd, Ibadan.
3. Agnani H, Arguillet J, Bessive MJ, Menut C 2005. Aromatic plant of tropical central Africa: Chemical and biological investigation of essential oils of *Ocimum* species from Gabon. *J. Ess. Oil. Res.* 17(4); 466-472.
4. Izevbigie, E. B. 2003. Discovery of water-soluble anticancer agent (edotides) from a vegetable found in Benin City, Nigeria. *Exp. Biol Med.* 228(3); 293-8.
5. Akinpelu DA. 1999. Antimicrobial activity of *Vernonia amygdalina* leaves. *Fitoterapia. J. Study. Med. Plants.* 70(4): 432-440.
6. Sainsbury M and Sofowora EA. 1971. Essential oils from the leaves and inflorescence of *Ocimum gratissimum*. *Phytochem* 10(8): 3309-3312.
7. Seun-Joo-Lee KU, Takayuki S, Kwang-Guen L. 2004. Identification of volatile components in Basil (*Ocimum gratissimum*) and thyme leaves (*Thymus vulgaris*) and their antioxidant properties. *Food Chemistry.* 91:131-137.
8. Adebolu TT and Oladimeji SA. 2005. Antimicrobial activity of *Ocimum gratissimum* on selected diarrhea-causing Bacteris in South Western Nigeria. *African J. Biotech.* Vol 4(7): 682-684.
9. Olasupo, N. A., Moro, D, D. and Smith, S.T. 2003. Effect of some indigenous Nigerian chewing sticks on oral bacterial flora. *Niger Med J.*, 44(3), 60-63.
10. Lesmos JA, Passos XS, Fernades OFL, Paula JR, Ferri PH, Souza LKH et al. 2005. Antifungal activity of *Ocimum gratissimum* towards *Cryptococcus neoformans*. *Mem. Ins. Oswald Cruz.* Vol 100(1)55-58.
11. Holetz FB, Nakamura TU, Fihó BPB, Cortez DAG, Diaz JAM, Nkamura CV. 2003. Effects of essential oil of *Ocimum gratissimum* on *Herpetomonas samuelpeesoai*. *Acta protozoal* 42: 269-276.
12. Seeley RR, Stephens TD, Tate P. 1996. Endocrine diseases In: *Essentials of Anatomy and Physiology*. McGraw Hill companies. USA. Pp281-284.
13. King H, Aubert RE, Herman WH. 1998. Global burden of diabetes, 1995-2025: Prevalence, numerical estimates and projections. *Diabetes care* 21; 1414-1431.
14. Boyle JP, Honey C, Honey AA, Narayan KM, Hoerger JJ, Geisis LS, Chen H, Thompson TJ. 2001. Projections of diabetes burden through 2025: Impact of changing demography and disease prevalence. *Diabetes care.* 24; 1936-1940.
15. Waugh A, Grant A. 2001. *Anatomy and Physiology in health and illness*. Ross and Wilson. 9th ed. Edingburgh, Churchill Livingstone. Pp224-236.
16. Malavige LS, Levy JC. 2009 Erectile dysfunction in diabetes mellitus. *J Sex Med* 6: 1232-1247.
17. Mansford KR, Opie L. 1968. Comparison of metabolic abnormalities in diabetes mellitus induced by streptozotocin or alloxan. *Lancet* 1(7544): 670-671.
18. Cotran RS, Kumar V and Collins T. 1999. *Robbins pathologic basis of disease*. 1st ed. New York, W B Saunders. 234-257.
19. Pelegrin M, Jean CD and Cristina C. 1998. Evidence from transgenic mice that interferon- $\gamma$  may be involved in the onset of diabetes mellitus. *J. Biol. Chem.* 273(20): 12332-12340.
20. Poirout V and Robertson, R.P. 2002. Secondary  $\beta$ -cell failure in type 2 diabetes- A convergence of glucotoxicity and lipotoxicity. *Endocrinology*, 143(2); 339-342.

21. Ramsey I. 1986. A synopsis of endocrinology and metabolism. 3rd ed. Bristol Wright. Pp 385-394.
22. Robinson S and Johnston DC. 1997. Metabolic disorders; Diabetes. In: Mechanisms of disease; an Introduction to clinical science. 1st ed Cambridge University press. 465-478.
23. Pollack JM and Bloom SR. 1992. The endocrine pancreas. Oxford textbook of pathology. New York. Oxford University press. 26-42.
24. Atanghwo IJ, Ebong PE, Egbung GE, Eteng MU and Eyong EU. 2007. Effect of Vernonia amygdalina Del on liver function in alloxan induced hyperglycemic rats. J. Pharm Biores. 4: 25-31.
25. Romeo JH, Seftel AD, Madhum ZT, Aron DC. Sexual function in men with diabetes type 2: association with glycemic control. J Urol 2000; 163: 788-791.
26. Abo KA, Adediwara AA and Jaiyesimi OE. 2000. Ethnobotanical survey of plants used in the management of diabetes mellitus in South Western region of Nigeria. J. Med & Med Sci. 2(1):20-24.
27. Gyan SS, Nyam DD and Sokomba EN. 1999. Hypoglycemic effect of crude extract of Vernonia amygdalina in normoglycemic and alloxan-induced hyperglycemic rats. J. Pharm Biores. 11:38-42.
28. Farombi EO. 2003. African indigenous plants with chemotherapeutic potentials and bioactive prophylactic agents. Afric. J. Biotech 2(12):662-671.
29. Phillipson JD, Wright CW, Kirby GL and Warhurst DC. 1993. Phytochemistry of some plants used in traditional medicine for the treatment of protozoal diseases. Abstracts: International symposium of the phytochemical society of Europe; University of Lausanne, Switzerland. PL3.
30. Ebong PE, Atanghwo IJ, Eyong EU, Ukwe C and Obi AU. 2006. Pancreatic beta cells regeneration: A possible parallel mechanism of hypoglycemic action of Vernonia amygdalina Del and Azadirachta indica. Proceedings of the 2006 international Neem conference, Kunming, China. Pp 83-89.
31. Dhavade P, Sumphan W, Norio O, Hajime H, Joju H et al 1992. Structures of two new bitter principles isolated from a Thai medicinal plant Vernonia extensia DC. Chem Pharm Bull 40(2):553-555.
32. Nimembo-Uadia R. 2003. Effect of Vernonia amygdalina in alloxan-induced diabetic albino rats. J. Med Lab Sci 12(1):25-31.
33. Ibrahim NDG, Abdurahman EM and Ibrahim G. 2000. Histological studies on the effects of chronic feeding of Vernonia amygdalina Del leaves on rats. Nig. J. Surg Res. 2: 68-74.
34. Igile GO, Oleszek W, Jurzysta M, Burda M, Fafunso A and Fasanmade A. 1994. Flavonoids from Vernonia amygdalina and their antioxidant activities. J. Agric. Food. Chem. 42, 2445-2448.
35. Maxwell A, Seepersand M, Pingel R, Mootoo DR, Reynolds WF. 1995. 3 beta-amino spirostanol steroidal alkaloids from ocimum gratissimum. J. Natl Prod. 58: 625-628.
36. Ihekoronye AL, Ngoddy PO. 1985. Integrated food science and technology for the Tropics. Macmillian Education Ltd. Pp58-62.

**Author Information**

**O. R ASUQUO**

Department of Human Anatomy, Faculty of Basic Medical Sciences, University of Calabar

**A. G EDET**

Department of Human Anatomy, Faculty of Basic Medical Sciences, University of Calabar

**O.E MESEMBE**

Department of Human Anatomy, Faculty of Basic Medical Sciences, University of Calabar

**J.I ATANGHWO**

Department of Biochemistry, Faculty of Basic Medical Sciences, University of Calabar