

Melanocytoma of the optic disc with Neuroretinitis

M Shastri, D Singhal, R Desai, S Desai, D Saxena

Citation

M Shastri, D Singhal, R Desai, S Desai, D Saxena. *Melanocytoma of the optic disc with Neuroretinitis*. The Internet Journal of Ophthalmology and Visual Science. 2008 Volume 7 Number 1.

Abstract

Melanocytoma of the optic disc are heavily pigmented benign tumors that are most often discovered during routine examination, as they are classically asymptomatic. Although a slight impairment of visual acuity attributable to the tumor may occur in large tumors, acute profound visual loss is extremely unusual. Most cases are discovered by chance. We report here a patient of melanocytoma with neuroretinitis who presented in ophthalmic out door for routine check up for dimness of vision.

INTRODUCTION

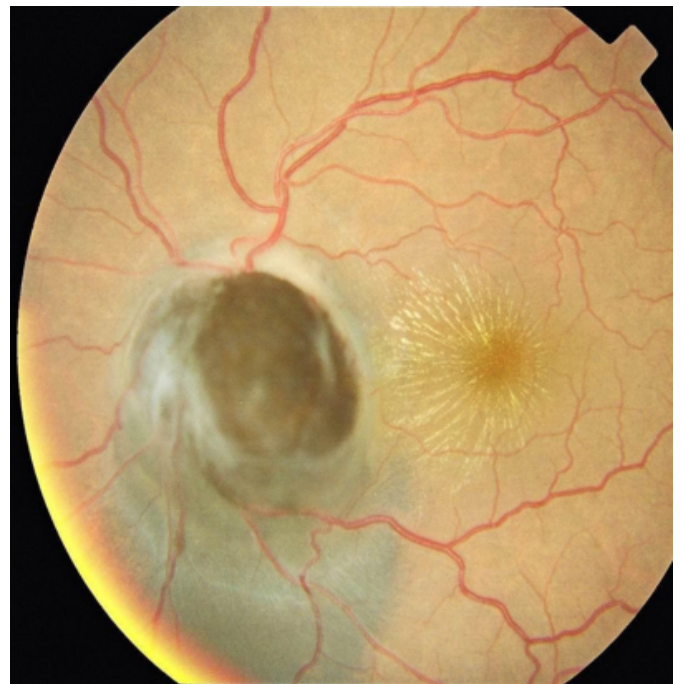Melanocytoma of the optic disc is a benign melanotic lesion caused by proliferation of the melanocytes normally found in the uvea and occasionally in the lamina cribrosa. It is typically unilateral, stationary and rarely undergoes a malignant transformation. Melanocytoma are classically asymptomatic lesions causing no appreciable change in the visual acuity except when the tumor is large or undergoes extensive necrosis or a malignant transformation. Primary malignant melanoma of the optic disc is extremely rare. Malignant melanoma at times mimics a melanocytoma thereby causing diagnostic difficulty in the early stage.

CASE REPORT

A 40 year old, dark skinned, female patient presented with the complaint of gradual progressive diminution of vision in left eye. On examination, her distant visual acuity was found to be 6/6 in right eye & 6/36 in left eye. The anterior segment on slit lamp bio-microscopy was found to be normal. General and systemic examination revealed no abnormality. On dilatation, her left eye fundus showed a uniformly black, raised mass, sitting on the optic disc, occupying the whole of the optic disc with neuro retinitis involving the macula (Figure 1).

Figure 1

Figure 1 : Fundus Photograph



Indirect ophthalmoscopy, B-scan, fluorescein angiographies and MRI further confirmed findings. (Figure 2 & 3)

Figure 2

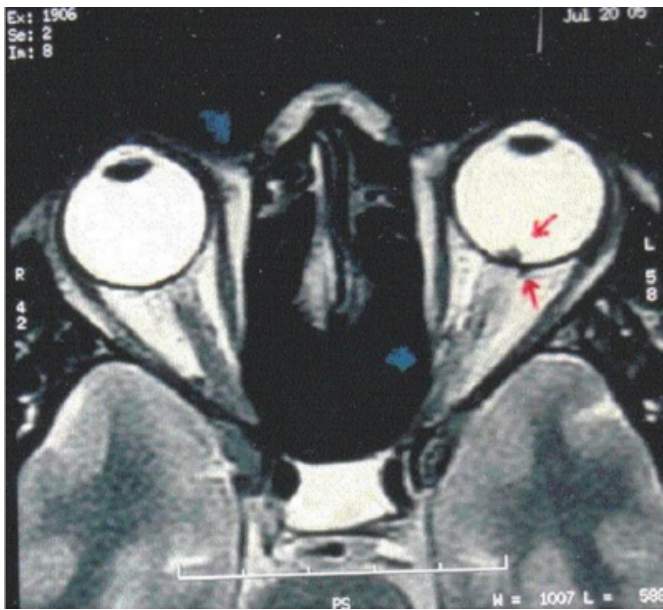
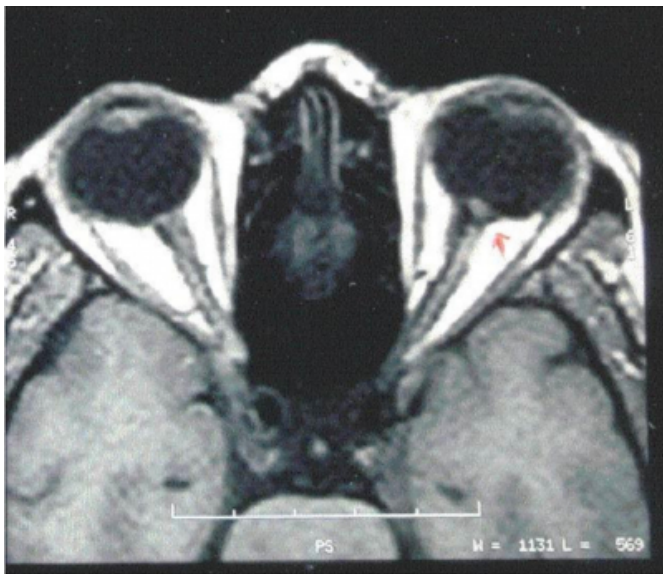

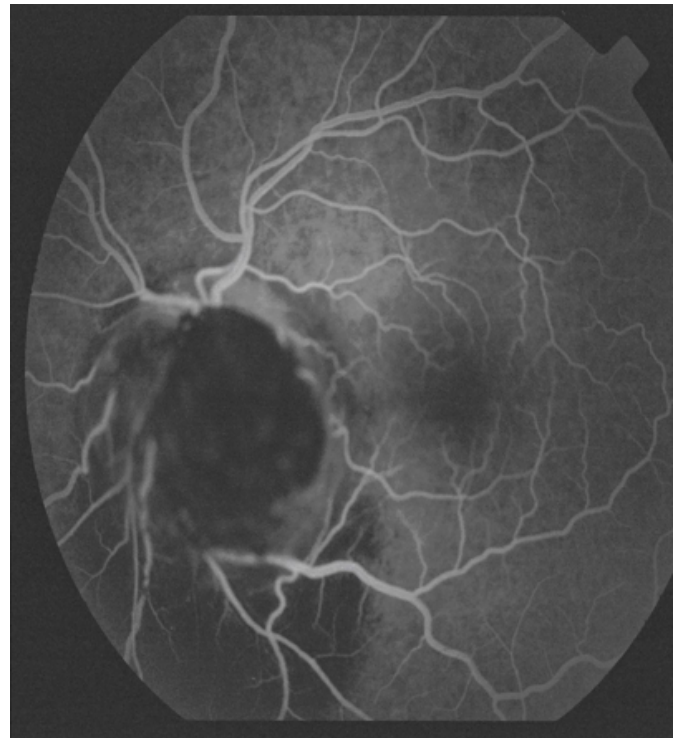
Figure 3



No abnormality was detected in the right eye. Intraocular pressure was 16.4 mm of Hg in both eyes. After refraction, no improvement in the vision of left eye was documented. On fluorescein angiography, the mass stood prominently totally masking the underlying disc and choroidal fluorescence. (Figure 4)

Figure 4

Figure 4: Fluroscein Angiography



DISCUSSION

Melanocytoma of the optic disc is rare than melanocytoma of the uvea. Ophthalmoscopically, it appears uniformly black with fibrillate margins due to infiltration into the adjacent retina. Some patients have afferent pupillary defects and nerve fiber bundle defects possibly due to nerve fiber layer compression. Melanocytoma commonly involves the infero- temporal aspect of the optic disc but, in this patient, it was located superiorly. On examination, the diagnosis strongly suggestive was that of melanocytoma because of the following reasons: a) Dark skinned female individual: melanocytoma as opposed to malignant melanoma is discovered with a relatively higher frequency in blacks and dark complexioned people. b) Visual acuity: malignant melanoma that involves the optic disc usually produces a profound fall in vision with disc edema, retinal hemorrhages and retinal detachment. Visual acuity in the present case was found to be reduced due to neuro retinitis.

c) Colour of mass: The mass was dark black with uniform pigmentation as against less and varied pigmentation of malignant melanoma. d) Fluorescein angiography: It showed typical blocked fluorescence by the melanocytoma unlike alternating areas of hyper fluorescence and hypo fluorescence in malignant melanoma. Zimmerman₂ in his study has reported occurrence of a sudden fall in vision with

papillitis and retinal hemorrhages due to ischemic necrosis in a case of melanocytoma.

A sudden fall in vision or increase in size should be viewed with caution for transformation to malignant melanoma, but other factors like acute vascular change, necrosis or a haematoma in a melanocytoma though rare should be kept in mind. Reidy et al, have observed one patient, in whom a melanocytoma of the optic disc which had been followed for 17 years, suddenly transformed into a malignant melanoma. It sometimes may be difficult to distinguish between a melanocytoma and a malignant melanoma in the early stage. Ultrasonic examination is not helpful and fluorescein angiography can be misleading. Here lies the importance of close continuous observations and serial color fundus photography at every visit, so as to monitor the size and the

rate of growth of the tumor and to guard against malignant transformation.

CORRESPONDENCE TO

Dr. Deepika Singhal * Dept of Ophthalmology, Surat Medical Institute of Medical Education & Research (SMIMER) Surat , Gujarat (India) email: deepika1103@yahoo.com ; Phone:912612233353

References

1. Jack J Kanski ,Clinical Ophthalmology ;231 Edition III.
2. Zimmerman LE, Garron LK. Melanocytoma of the optic disc. Int Ophthalmol Zimmerman LE, Garron LK. Melanocytoma of the optic disc. Int Ophthalmol Clinic 1962;431.
3. Reidy JJ, Apple DJ, Steinmetz RL. Melanocytoma: nomenclature, pathogenesis, natural history and treatment, Surg Ophthalmol 1985; 29: 319-327.

Author Information

Manisha Shastri, MS Ophthalmology

Dept of Ophthalmology, Surat Medical Institute of Medical Education & Research (SMIMER)

Deepika Singhal, MS Ophthalmology

Dept of Ophthalmology, Surat Medical Institute of Medical Education & Research (SMIMER)

Roopali Desai

Dept of Ophthalmology, Surat Medical Institute of Medical Education & Research (SMIMER)

Sejal Desai, DOMS

Dept of Ophthalmology, Surat Medical Institute of Medical Education & Research (SMIMER)

Deepak B. Saxena, MD-Community Medicine

IIPH