

# Management Of Two Partial Amputations Of The Wrist In Precarious Environment: Analysis Of 2 Observations At The Orthopedics-Traumatology Department Of The Ignace Deen National Hospital.

M Bah, A Bousso, L Lamah, L Soumaoro, M Sidibe, S Tekpa, M Soumah

## Citation

M Bah, A Bousso, L Lamah, L Soumaoro, M Sidibe, S Tekpa, M Soumah. *Management Of Two Partial Amputations Of The Wrist In Precarious Environment: Analysis Of 2 Observations At The Orthopedics-Traumatology Department Of The Ignace Deen National Hospital.*. The Internet Journal of Orthopedic Surgery. 2018 Volume 26 Number 1.

DOI: [10.5580/IJOS.52983](https://doi.org/10.5580/IJOS.52983)

## Abstract

The authors report in this study the results of the management of two cases of partial amputation of the wrist. Both of these patients showed almost identical lesions. It was a section of all the contents of the carpal tunnel and that of the Guyon canal. The first patient was a right-handed manual worker who was admitted 45 minutes after a work accident where he had left open wrist trauma. The second, a right-handed anthropologist, received 15 minutes, which after a domestic accident (fall in the toilets with the palmar face of the right hand on the sink) presented an open trauma of the right wrist. The operative technique was identical under locoregional anesthesia (plexus block) we proceeded to the repair of the tendons by KESSLER points reinforced by a peritinous surging, the suture of the arteries was done after the low molecular weight heparin and the nerves by the epiperiureal suture and a complementary immobilization of the limb in a splint plastered in cuff. The postoperative course was simple and satisfactory functional recovery after rehabilitation sessions and the resumption of professional activity. For the evaluation of our patients we used the patient's wrist evaluation score (PRWE).

## INTRODUCTION

Wounds on the ventral side of the wrist are particularly serious, sometimes involving the functional prognosis of the hand. These wounds are responsible for severe motor and sensory sequelae but also pain [1]. The repair of these lesions is a real functional issue. It has been shown that through careful surgery followed by postoperative rehabilitation that good functional results can be obtained [2]. Occupational accidents are the main etiology of these injuries, followed by domestic accidents [3]. The management of these lesions in a very poorly equipped center is a real challenge. Through these two case reports, we carried out an analysis of the diagnostic, therapeutic, and evolutionary parameters taking into account our working context.

## CASE 1:

A 53-year-old, male, docker, right handed, received for open trauma of the left wrist following an accident at work (he

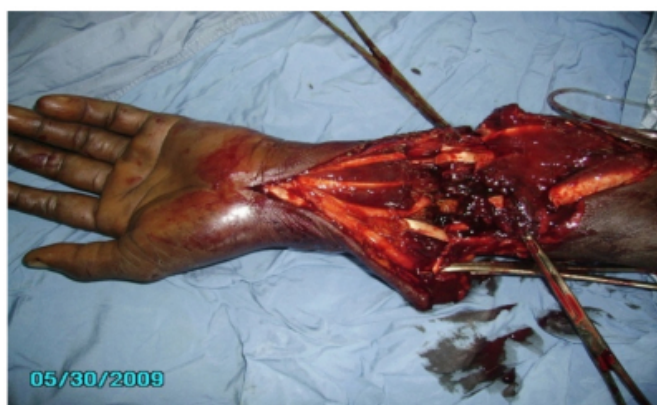was injured by a bar of glass on the ventral side of the wrist). A tourniquet was placed on his arm and he was taken to our ward 45 minutes after the accident. At the clinical examination we saw a transverse wound of the wrist with severe bleeding with impossibility of active bending of the fingers without rotational disorders, lack of sensitivity in the territories of the nerves (radial, median and ulnar), as well as lack of local heat in the hand (re-coloring was greater than 3 seconds). Face and wrist profile X-ray showed bone integrity.

For the surgery, he was placed supine with his left upper limb resting on a tablet with a tourniquet on his arm after loco-regional anesthesia (plexus block). We proceeded with abundant washing of the wound with isotonic saline serum and then to aseptic draping. At the exploration we found a large transverse wound on the ventral side of the left wrist with detachment of a fascio-cutaneous flap including the total tendon area of the common flexor muscles (superficial

and deep), long flexor digitorum, flexor muscle of carpi, flexor carpi ulnaris, long palmar muscle, and section of nerves (radial, median, and ulnar) and radial and ulnar arteries (Figure 1). The tendon ends were identified and maintained by needles. Then, we sutured the tendons via KESSLER points [4] reinforced by a pertiginous overgrip. A perineural epi suture [5] was used to repair three nerves. For arterial repair, we rinsed the two arterial ends with low molecular weight heparin, and then we reattached them. The limb was then immobilized in a plaster cast wrist splint in palmar flexion for three weeks. With this treatment we combined antibiotic prophylaxis, serotherapy and analgesics. Rehabilitation was started 21 days postoperative by active and passive movements. After a 7-year follow-up, PRWE's patient evaluation gave 0/50 for both pain and hand function. (Figure 2).

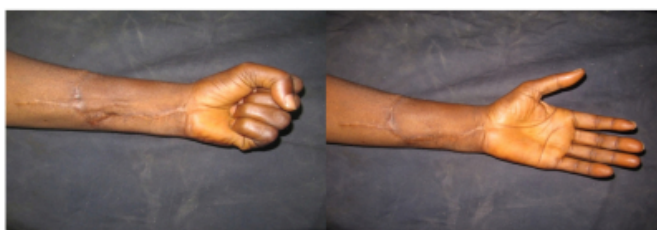### Figure 1

Anatomic Lesions



### Figure 2

Functional And Esthetic Results



### CASE 2:

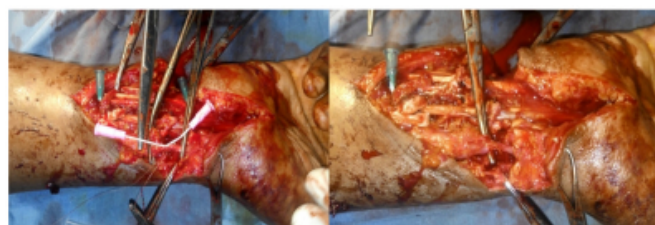A 27-year-old male, anthropologist, right-hander with no particular antecedents, presented with a trauma to the right wrist following a domestic accident. He arrived 15 minutes after the accident with a tourniquet on his arm. On clinical examination, we found a transverse wound of the right wrist severe bleeding, impossibility of active bending of the

fingers without rotational disorders, lack of sensitivity in the territories of the naves (radial, median and ulnar), as well as lack of local heat in the hand (re-coloring was greater than 3 seconds). Face and wrist profile X-ray showed bone integrity.

The patient was admitted for surgery. His right upper limb was placed on a tablet with a tourniquet on the arm under loco-regional anesthesia (plexus block), We proceeded with the abundant washing with saline serum and then with the aseptic preparation of the operative field. On exploration, we found a large transverse wound on the anterior surface of the right wrist. We found a separation in the tendon zone including common flexor muscles (superficial and deep); long flexor digitorum muscle; flexor carpi radialis muscle; flexor carpi ulnaris; palmar long muscle as well as separation of the nerves (radial, median and ulnar); as well as separation of the arteries (radial and ulnar) (Figure 3). The tendon ends were identified and maintained by needles. Then, we sutured the tendons via the KESSLER points reinforced by a pertig tendinous surjection. A peri-neural epi suture was performed for the repair of the three nerves. For arterial repair, we rinsed the two arterial ends with low molecular weight heparin and sutured them together and then checked the patency of the artery by palpating the pulse on the distal segment (Figure 4). The limb was then immobilized in a plaster cast wrist splint in palmar flexion for three weeks. Active rehabilitation was started after removal of the cast. The postoperative course was uncomplicated. After a five-year follow-up, PRWE's patient evaluation gave 2/50 for pain and 0/50 for hand function. (Figure 5).

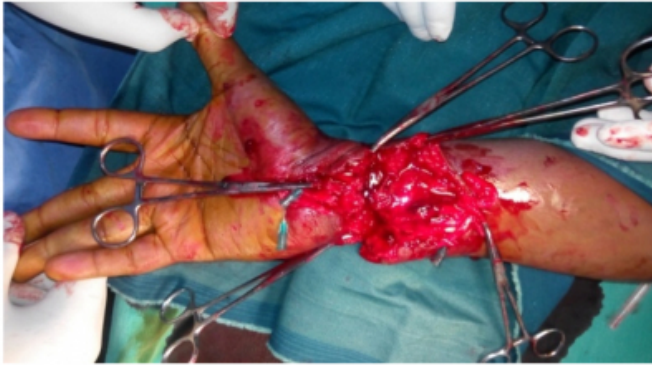
### Figure 3

Anatomic Lesions



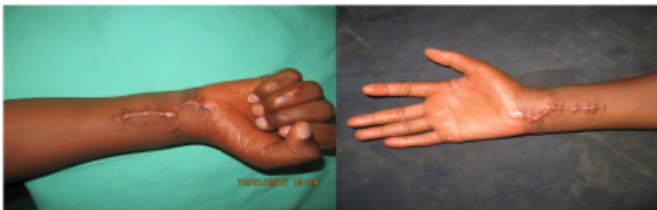**Figure 4**

Surgical Procedure



**Figure 5**

Functional And Esthetic Results



## DISCUSSION

Our patients were young males, right-handed adults, one with the injury on the dominant side and the other with the injury on the left side. They presented with almost identical lesions but of different etiologies. The lesion mechanism of the first patient proceeded in two steps: The window was tangent to the forearm to take off a fascio-cutaneous flap and to cut the ventral side of the wrist.

For the second patient, the trauma was perpendicular to the axis of the forearm. In the literature, the mechanisms of injury vary from one series to another, Work-related accidents were most frequently encountered in the literature [6,7]. Aggression as etiology was reported in the Bousakri H series [8]. All of our patients were received within the first hour of the accident. This early management was possible due to the proximity of our hospital to the accident site and, on the other hand, by the fact that both patients were covered by health insurance. Komla S A [9], however, replanted his hand seven hours after the accident, which he said was the first such repair in sub-Saharan Africa outside of South Africa. The technique used to repair the lesions of our patients was made with function of anatomical structures of the wrist in mind. Then we made KESSLER sutures for the repair of flexor tendons; On the other hand, Kleinert H E [10] and Chow J A [11] agree on the combined use of two

methods (Kleinert-Duran) which, according to them, would allow early postoperative mobilization. This is why in our cases we considered it necessary to immediately use a postoperative plaster cast in posterior flexor position to protect our stitches for three weeks and then proceed with rehabilitation by passive movements and then active movements. For nerve repair (median nerve, ulnar nerve, radial nerve), we performed an epiperineural suture [5].

In the literature [12, 13] many prognostic factors would influence the outcome including: age of the patient, arterial repair, degree of nerve contusion, number of severed tendons as well as damage to the dominant side. The rate of good results would decrease as one ages. All nerve surgery techniques used should promote revascularization of the nerve [14]. The notion of primary repair advocated by Bunnel [15] in 1956 is not in question. Nerve regeneration in a clean and richly vascularized environment remains a guarantee for good results as explained by Chaise et al. [16]. Many prognostic factors can influence the outcome of nerve repairs to the wrist. In particular, the number of tendons cut and the trauma on the dominant side [17].

## CONCLUSIONS

The care of these two patients was ensured in our service despite difficult conditions. The absence of microsurgery equipment and of a specialist in hand surgery forced the trauma orthopedic surgeon to take these lesions. Nevertheless, we were able to obtain results judged satisfactory both aesthetically and functionally.

## References

1. Baktir A, Türk CY Kabak S, et al. Flexor tendon repair in zone 2 followed by early active mobilization. *J Hand Surg Br* 1996 Oct; 21 (5): 624-8.
2. Bellemère P, Chaise F, Friol JP, Gaisne E, Lelardic C. Résultats de la mobilisation active précoce après réparation primaire des tendons fléchisseurs. *La main*. 1998 ; 3 :221-33.
3. Bellemère P. pour une compagnie nationale de prévention des accidents de la main. *Chir Main* 2003 ; 22 : 233-9.
4. Pişkin A, Yüçetürk A, Tomak Y, Ozer M, Gülman B, Ataman A et al. Tendon repair with the strengthened modified Kessler, modified Kessler, and Savage suture techniques: a biomechanical comparison *ActaOrthopTraumatolTurc*.2007; 41(3):238-43
5. Masmejean E, Lésion traumatiques des nerfs périphériques, disponible sur [www.chirurgiedelamain.eu](http://www.chirurgiedelamain.eu) consulté le 09/ 09/ 2017.
6. Knipper P, Rimareix F, Dubert. Prise en charge d'une plaie de la main en situation précaire. *Cahiers d'enseignement de la SOFCOT* 2006 ; 93 : 279-91.
7. Fikry T, Saidi H, Latifi M, Essadki B, Zryouil B, La main

traumatique par Toupie : pour une meilleure prévention. *Chir. De la main* 2004, 23 : 96-99.

8. Boussakri H, Azarkane M, Elidrissi M, Shimi M, Elibrahimi A, Elmrimi A. Résultats fonctionnels des lésions des tendons fléchisseurs de la main : à propos de 90 cas. *Pan Afr Med J*, 2013, 15 (1) :1-6.

9. Komla SA, Komla A, Batarabadia B, Anani A, Assana D., Replantation des mains : première expérience dans un pays d'Afrique sub-saharienne (Togo), *Indian J Plast Surg*, 2016 Jan-Apr ; 49 (1) : 109-111

10. Kleinert HE, Kutz JE, Atasoy E, Storno A, Primary repair of flexor tendons. *OrthopClin North Am*. 1973 Oct; 4 (4):865-76.

11. Chow JA, Thomes LJ, Dovel S, et al. Controlled motion rehabilitation after flexor tendon repair and grafting. A multicentre study. *J Bone Joint Surg Br*. 1988 Aug; 70(4):591-5.

12. Alnot JY, Badelon O, Leroux D. Les plaies tendino-nerveuses de la face antérieure du poignet. À propos d'une

série de 62 cas. *RevChirOrthop*; 1986;72 : 126-31.

13. Bourrel P, Ferro RM, Lorthioir J M. Epiperineural nerve sutures and neurilemmatic sutures. Comparative clinical results about 109 cases (author's transl). *Sem Hop*; 1981; 57:2015-23.

14. Starkweather RJ, Neviasser RJ, Adams JP, Parsons DR. The effect of devascularisation on the regeneration of lacerated peripheral nerves. *J Hand Surg*; 1978; 3: 163-7.

15. Tropet Y. Réparation des nerfs digitaux : techniques, résultats et indications. *Cahier d'enseignement de la Société française de chirurgie de la main*; 2000 ; 12 :47-63.

16. Chaise F. Les plaies des nerfs collatéraux palmaires des doigts. *Cahier d'enseignement de la Sofcot*; 1997, 64 :106-14.

17. Kim DH, Han K, Tiel RL, Murovic JA, Kline DG. Surgical outcomes of 654 ulnar nerve lesions. *J Neurosurg*; 2003 ; 98 :993-1004.

**Author Information**

**ML Bah**

Orthopedic Department, National Hospital Ignace Deen  
Guinée Conakry

**A Bousso**

Orthopedic Department, General Hospital Général Grand Yoff  
Sénégal

**L Lamah**

Orthopedic Department National Hospital Donka  
Guinée Conakry

**LT Soumaoro**

General Surgery Department, National Hospital Ignace Deen  
Guinée Conakry

**M Sidibe**

Orthopedic Department, National Hospital Ignace Deen  
Guinée Conakry

**SB Tekpa**

Orthopedic Department National Hospital Donka  
Guinée Conakry

**MT Soumah**

Orthopedic Department, National Hospital Ignace Deen  
Guinée Conakry