

Percutaneous Radio-Frequency Rhizotomy For Recurrent Trigeminal Neuralgia After Failure Of Microvascular Decompression

A Toubar, O Dawood

Citation

A Toubar, O Dawood. *Percutaneous Radio-Frequency Rhizotomy For Recurrent Trigeminal Neuralgia After Failure Of Microvascular Decompression*. The Internet Journal of Neurosurgery. 2019 Volume 15 Number 1.

DOI: [10.5580/IJNS.54079](https://doi.org/10.5580/IJNS.54079)

Abstract

Background: Trigeminal neuralgia (TN) is a pain syndrome having a great impact on quality of life. Percutaneous radiofrequency thermocoagulation (PRT) is the most common surgical procedure done for the treatment of TN. While microvascular decompression (MVD) was always used for more sustained pain relief and less incidence of recurrence but it is not always meet patient pain relief satisfaction. Hence, we aimed to evaluate the effectiveness of radiofrequency thermocoagulation rhizotomy on patients with recurrent TN after MVD.

Methodology: A prospective study of 20 consecutive cases of recurrent TN after MVD underwent PRT from March 2014 to July 2017. Based on clinical outcome and follow up, a second session of PRF was offered if patient pain relief was unsatisfactory. Effective pain control was considered when excellent or good outcome was achieved. For poor pain outcome, a second procedure was offered and done.

Results: Mean age was 50.50 ± 10.23 ranged from 32-57 years. Pain score after PRT dropped from 4.60 ± 0.50 to 1.40 ± 0.94 . The pain outcome after the first PRT procedure showed that only 35% had poor outcome which required another procedure of PRT, after which VAS dropped from 4.57 ± 0.54 to 2.00 ± 1.41 immediately while 10% of the study cohort had poor quality of pain after the second procedure.

Conclusion: Recurrence of TN is difficult to avoid regardless the choice of the procedure. The majority of patients had complete or near total pain relief. Reapplication of PRT for failed PRT for first time in such cases can achieve very good outcome for pain relief.

INTRODUCTION

Trigeminal neuralgia (TN) is a pain syndrome characterized by a sudden brief, usually unilateral, severe, recurrent electric like pain in area supplied by the trigeminal nerve, having a great impact on quality of life).(1) In addition to medications, many interventional procedures were done such as; glycerol/alcohol injections, mechanical compression, radiosurgery, and thermocoagulation rhizotomy through radiofrequency. Percutaneous radiofrequency thermocoagulation (PRT) is the most common surgical procedure done for the treatment of TN.(2,3) The main advantage of PRT being an invasive procedure, and is its effectiveness for pain relief. However, complications may occur; facial numbness, corneal reflex affection, masticatory weakness and less commonly intracranial bleeding. Such

complications are sequential to the injury of nervous structures by the surgical puncture and the thermal energy during the procedure. While microvascular decompression (MVD) was always used for more sustained pain relief and less incidence of recurrence but it is not always meet patient pain relief satisfaction, with a failure rates varied from 15% - 35%.(3-5) An alternative approaches are used to deal with the recurrent pain after MVD. Hence, we aimed to evaluate the effectiveness of radiofrequency thermocoagulation rhizotomy on patients with recurrent typical trigeminal pain after MVD.(6)

METHODOLOGY

Patient Cohort

A prospective study of 20 consecutive cases of recurrent

Percutaneous Radio-Frequency Rhizotomy For Recurrent Trigeminal Neuralgia After Failure Of Microvascular Decompression

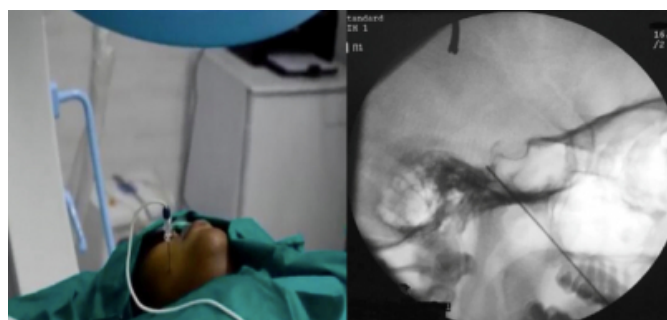typical TN after MVD underwent PRT from March 2014 to July 2017. Based on clinical outcome and follow up, a second session of PRF was offered if patient pain relief was unsatisfactory. The patients were followed 18 months.

Puncture technique

In supine position, Hartel’s technique was used: point 1 was 3 cm from the angle of the mouth on the ipsilateral side of the face, point 2 was 2.5 cm away from the external auditory meatus, while point 3 was the ipsilateral pupil. 1-2 and 1-3 lines were joined together. Taking point 1 as the entry point, the tip of the needle was directed to foramen oval, and the needle end was kept vertically in-between the two lines 1-2 and 1-3. Patients were kept awake during the procedure. Figure 1 The typical pain occurred at the puncture denoted that the needle was at the correct target. The expected sensory response, showed the appropriate location of the needle’s, which was confirmed again intraoperative imaging. Before starting lesioning, electrical stimulation was done to confirm the correct aim of trigeminal nerve branch. Then the depth of the needle’s tip was modified according to the sequential feedbacks of the stimulation. RFG-3GF radiofrequency generator (American Radionics Corporation), and the insulation RF electrode needle with 0.5 cm exposed tip (Radionics, Burlington, USA) was used for this procedure. The parameters for the electrical stimulation before lesioning is 0.2 V to 1.0 V (50 Hz, 0.2 ms) and the temperature was 75°C, with 2 -3 cycles each lasted for 120 seconds.

Figure 1

Patients were kept awake during the procedure, the tip of the needle was directed to foramen oval.



Follow up and outcome

Demographic data were recorded, duration of pain relief post MVD, side affected, which division(s) of the trigeminal nerve, and complications. Visual Analog Score (VAS) of patients preoperative and 1 day postoperative, 1 month, 2

months, 6 months, 12 months, and 18 months after the procedure. Being “0” for no pain till “10” for the worst possible pain patient had. The pain grading outcome was defined according to Barrow neurological institute pain intensity score as; excellent if pain free without any medications, good if occasional pain, no medications required or some pain, adequately controlled with medications while poor if some pain, not adequately controlled with medications or severe pain or no pain relief unchanged by the procedure(7). Effective pain control was considered when excellent or good outcome was achieved. Pain recurrence defined as the return of any kind of pain after the procedure. For poor pain outcome, a second procedure was offered and done.

Statistical analysis

Statistics were performed using the SPSS 22.0 software (SPSS Inc., Chicago, IL, USA), P <0.05 was considered statistically significant.

RESULTS

Totally 20 patients were involved in the study cohort, mean age was 50.50 ± 10.23 ranged from 32-57 years. Females were more frequent when compared to males 12:8. Duration of recurrence of symptoms after MVD was 4.50 (2.5 – 32) months with 1 -96 range. While right and left side were equally affected in the study and anatomical distribution of trigeminal nerve show in Table 1.

Table 1

Anatomical distribution of pain.

Distribution of Pain	No.	%
V2	7	35.0%
V3	2	10.0%
V1,V2	2	10.0%
V2,V3	7	35.0%
V1,V2,V3	2	10.0%

Pain score after PRT dropped from 4.60 ± 0.50 to 1.40 ± 0.94 which is highly significant as shown in Table 2. The pain outcome after the first PRT procedure showed that only 7 patients 35% were included in poor outcome group which required another procedure of PRT Table 3. The recurrence of pain symptoms occurred in average of 10 months with range from 0 months to 35 months. Table 4 showed the drop of VAS from 4.57 ± 0.54 of the 7 immediately after the second patients, and VAS 1 after 18 months from the procedure, while pain grades of poor outcome patient group after the second procedure PRT shown in Table 5; which

Percutaneous Radio-Frequency Rhizotomy For Recurrent Trigeminal Neuralgia After Failure Of Microvascular Decompression

showed that only 10% of the study cohort had poor quality of pain after the second procedure of PRT Figure 2. Regarding complications, Masticatory muscle weakness was seen in 2 cases in the second procedure group 10% and a single case of transient oculomotor nerve palsy seen after first procedure 5% which relieved 3 weeks after.

Figure 2

Pain control outcome after first and second RF.

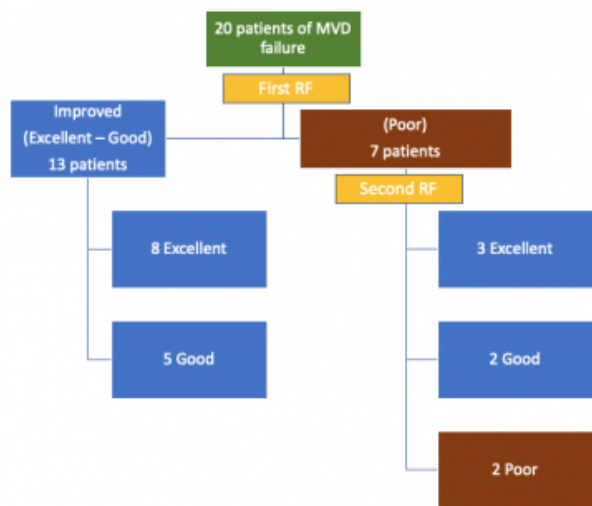


Table 2

Pain score after first RF procedure.

Pain Score Pre-treatment	Mean ± SD	Range	Pain Score Post First Radio Frequency Treatment	Test value*	Sig.
			No. = 20		
1 day	Mean ± SD	4.50 ± 0.54	4.57 ± 0.54	-	-
	Range	4 - 5			
1 Month	Mean ± SD	2.00 ± 1.41	2.00 ± 1.55	4.500	HS
	Range	1 - 4			
2 Months	Mean ± SD	1.40 ± 0.55	1.40 ± 0.55	16.000	HS
	Range	1 - 2			
6 Months	Mean ± SD	1.40 ± 0.55	1.25 ± 0.50	13.000	HS
	Range	1 - 2			
12 Months	Mean ± SD	1.00 ± 0.00	1.00 ± 0.00	7.000	HS
	Range	1 - 1			

P-value >0.05: Non significant; P-value <0.05: Significant; P-value < 0.01: highly significant
NS: Non significant; S: Significant; HS: Highly significant * : Paired t-test

Table 3

Pain grading outcome after the first PRT procedure.

Outcome	Number of patients	%
Poor	7	35.0%
Good	5	25.0%
Excellent	8	40.0%
Total	20	100.0%

Table 4

Pain score after second RF procedure.

After 1st procedure	Mean ± SD	Range	Pain Score	Test value*	Sig.
			No. = 20		
1 day	Mean ± SD	4.57 ± 0.54	4.57 ± 0.54	-	-
	Range	4 - 5			
1 Month	Mean ± SD	2.00 ± 1.41	2.00 ± 1.55	4.500	HS
	Range	1 - 4			
2 Months	Mean ± SD	1.40 ± 0.55	1.40 ± 0.55	16.000	HS
	Range	1 - 2			
6 Months	Mean ± SD	1.40 ± 0.55	1.25 ± 0.50	13.000	HS
	Range	1 - 2			
12 Months	Mean ± SD	1.00 ± 0.00	1.00 ± 0.00	7.000	HS
	Range	1 - 1			

P-value >0.05: Non significant; P-value <0.05: Significant; P-value < 0.01: highly significant
NS: Non significant; S: Significant; HS: Highly significant * : Paired t-test

Table 5

Pain grading outcome after the second PRT procedure for the poor outcome group.

Final outcome	No.	%
Poor	2	28.6%
Good	2	28.6%
Excellent	3	42.9%
Total	7	100.0%

DISCUSSION

Trigeminal neuralgia which is resistant to medical treatment can be managed first by one of these several methods of treatment. The choice of a specific procedure depends on many variables as patient age, associated medical morbidities, probability of existing vascular compression of the trigeminal root entry zone, and patient choice.(2,8) However, the management of medically resistant TN is not always satisfactory, and patients may ask for retreatment. Such recurrence is reported in 10 - 30% of patients, which occurs in 90% of the cases in the same distribution, where symptoms started.(9-11)

Recurrence of symptoms have been reported with young patients whom had surgery with increased pre-operative duration of TN, persistence of venous mechanical compression at trigeminal root entry, being females, and left sided pain in males. In our study cohort, females were more commonly affected than men, but without any statistical significance for other variables. In literature, It is still not clear why females have a more rate of pain recurrence.(8,11,12)

Through the known invasive procedures, microvascular

decompression was done by many surgeons since Jannetta started MVD as a successful method for TN treatment and the most accepted applicable technique which treat the hypothesized vascular mechanical compression etiology by relocation of the offending vessel.(4,13) MVD achieved the highest patient's satisfaction among the other procedures and the least rate of pain recurrence, also without harming the trigeminal nerve itself as concept of the procedure.(14) Hence, most of patient whom had MVD attained satisfactory outcomes, even in older age group of patients.(15,16)

In literature, a rate of recurrence was recognized and well documented, which is 20% - 30% in 4 years post MVD. However, outcomes of MVD can be query in many cases, as venous mechanical compression, and when vessel pass through the trigeminal nerve. Burchiel et al. suggested a wide classification of TN, which included; TN1 as sharp, electrical, shooting shock-like paroxysmal pain attacks and TN2 by continuous aching, burning, throbbing pain more than 50% of the time, while symptomatic TN which occurs in association with multiple sclerosis.(17) In our study, younger patients showed more frequent recurrence rate than older patients regarding liability of recurrence of symptoms after MVD.(5,15,18,19)

Some patients with recurred pain may agree to proceed have MVD again, however, many prefer to try another procedure. Each of it has its own advantages and limitations. In pervious huge case series of RF, 1217 of glycerol injections, 759 of balloon compression, 1417 of MVD and another 250 of partial root rhizotomy, they concluded that RF and MVD achieved the most rapid pain relief and long-term patient's satisfaction. While, stereotactic radiosurgery has the lowest initial pain relief, which still is a valid option for whom cannot undergo a surgical procedure.(1,2,13) Regarding glycerol injections is not anatomically specific for trigeminal nerve divisions and has the highest rate of recurrence rate as well as the occurrence of dysesthesia. Balloon mechanical compression of trigeminal ganglion has a excellent pain relief in early and long-term, but it may be associated with high incidence of significant bradycardia and hypotension intraoperative, and cause motor branch affection presented with mastication malfunction and can harm other cranial nerves. On the other hand, PRT is more reasonable regarding long term outcomes of pain relief and morbidities and could be easily done in case of recurrence of pain. So, we chose to perform PRT hoping satisfactory pain alleviation. PRT is considered to be the safest and the least invasive procedure

for TN particularly with good long-term outcomes and can be repeated easily in pain recurrence.(3,11,17)

In our clinical experience, PRT was done in cases of unsuccessful MVD cases. MVD can be also be redone in such cases but with higher morbidities and mortalities and still with a high risk of recurrence of symptomatic TN of recurrence again. Many modifications of MVD such as partial rhizotomy of trigeminal sensory root was done but the presence of adhesions of the vital structures to the Teflon increased the risk of morbidities and mortalities.(2,3)

Currently all lesioning are carried out under X-ray live guidance , which decrease the intraoperative and postoperative morbidities of mal-directions and more accurate trigeminal ganglion localization. Also, the tip of the electrode needle can be manipulated according the imaging till its accurately placed in the ganglion. Before the RF lesioning, a stimulation test was done to confirm the division by using a square wave of 100Hz frequency for stimulation. The sensory feedback corresponding to the affected division will confirm the needles tip or it can be re-adjusted till the expected response.(5,6,13,19)

In most of cases of TN to be caused by mechanical compression by vessels on root of trigeminal nerve, or others as tumors or multiple sclerosis, while PRT of TN is depends on interrupting the pain pathway by inducing partial damage to trigeminal fibers.(20,21) The PRT induced facial numbness was correlated with degree of pain alleviation, which seems to be time (120 s) and heat degree (75°C) dependent as seen in our current study.(22)

In our clinical series, all the cases were successfully targeted with no clear complications occurred during the procedure. Patients who had pain relief (excellent and good) after first procedure represented 65%, while the poor pain control group whom underwent another procedure had a pain relief rate of 71.4% which is clearly higher than most of the rate of repeated MVD mentioned in literature.

No major complications occurred in both groups whom had single or twice procedure. However, hypoesthesia in a variable degrees was seen in all, which is rare to be seen after MVD. PRT leads to a high rate of trigeminal numbness, then radiosurgery, an incidence of 42% of new numbness in trigeminal distribution after a second procedure is well reported. The degree of facial numbness correlated positively with pain alleviation. Although hypoesthesia were clear, no major complains were raised, mostly due to the

significant pain relief when compared to the preoperative pain.(21,23,24) Muscle weakness was seen in 2 cases of the group who had 2 procedures, a single case of transient oculomotor nerve palsy which relieved 3 weeks after, while no corneal analgesia were seen.

Recurrence of trigeminal pain is difficult to avoid regardless the choice of the procedure.(1,8) However, PRT can guarantee good immediate and at least short-term pain alleviation in all patients groups with different etiologies. Also, the long-term pain control of PRT for trigeminal neuralgia is comparable to MVD.

CONCLUSION

Trigeminal neuralgia can recur after MVD. PRT offer a less invasive and an excellent choice for retreatment. The majority of patients had complete or near total pain relief. Reapplication of PRT for failed PRT for first time in such cases can achieve very good outcome for pain relief.

References

1. Han I, Shin D, Chang J, Kim K, Chang J, Huh R, et al. Effect of Various Surgical Modalities in Recurrent or Persistent Trigeminal Neuralgia. *Stereotact Funct Neurosurg* [Internet]. S. Karger AG; 2010;88(3):156–62. Available from: <http://dx.doi.org/10.1159/000303530>
2. Pagni CA, Fariselli L, Zeme S. Trigeminal neuralgia. Non-invasive techniques versus microvascular decompression. It is really available any further improvement? [Internet]. *Reconstructive Neurosurgery*. Springer Vienna; p. 27–33. Available from: http://dx.doi.org/10.1007/978-3-211-78205-7_5
3. Jannetta PJ. Arterial Compression of the Trigeminal Nerve at the Pons in Patients with Trigeminal Neuralgia. *J Neurosurg* [Internet]. Journal of Neurosurgery Publishing Group (JNSPG); 1967;26(1part2):159–62. Available from: <http://dx.doi.org/10.3171/jns.1967.26.1part2.0159>
4. Bovaira M, Penarrocha M, Penarrocha M, Calvo A. Conventional radiofrequency treatment in five patients with trigeminal neuralgia. *Med Oral Patol Oral y Cir Bucal* [Internet]. *Medicina Oral, S.L.*; 2013;e76–80. Available from: <http://dx.doi.org/10.4317/medoral.17372>
5. Kim JH, Yu HY, Park SY, Lee SC, Kim YC. Pulsed and Conventional Radiofrequency Treatment: Which Is Effective for Dental Procedure-Related Symptomatic Trigeminal Neuralgia? *Pain Med* [Internet]. Oxford University Press (OUP); 2013;14(3):430–5. Available from: <http://dx.doi.org/10.1111/pme.12046>
6. Van Zundert J, de Louw AJA, Joosten EAJ, Kessels AGH, Honig W, Dederen PJWC, et al. Pulsed and Continuous Radiofrequency Current Adjacent to the Cervical Dorsal Root Ganglion of the Rat Induces Late Cellular Activity in the Dorsal Horn. *Anesthesiology* [Internet]. Ovid Technologies (Wolters Kluwer Health); 2005;102(1):125–31. Available from: <http://dx.doi.org/10.1097/0000542-200501000-00021>
7. Riesenburger RI, Hwang SW, Schirmer CM, Zerris V, Wu JK, Mahn K, et al. Outcomes following single-treatment Gamma Knife surgery for trigeminal neuralgia with a minimum 3-year follow-up. *J Neurosurg. American Association of Neurological Surgeons*; 2010;112(4):766–71.
8. Campos WK, Linhares MN. A prospective study of 39 patients with trigeminal neuralgia treated with percutaneous balloon compression. *Arq Neuropsiquiatr* [Internet]. FapUNIFESP (SciELO); 2011;69(2a):221–6. Available from: <http://dx.doi.org/10.1590/s0004-282x2011000200016>
9. Sheehan J, Pan H-C, Stroila M, Steiner L. Gamma knife surgery for trigeminal neuralgia: outcomes and prognostic factors. *J Neurosurg* [Internet]. Journal of Neurosurgery Publishing Group (JNSPG); 2005;102(3):434–41. Available from: <http://dx.doi.org/10.3171/jns.2005.102.3.0434>
10. Taha JM, Tew JM. Comparison of Surgical Treatments for Trigeminal Neuralgia: Reevaluation of Radiofrequency Rhizotomy. *Neurosurgery* [Internet]. Oxford University Press (OUP); 1996;38(5):865–71. Available from: <http://dx.doi.org/10.1097/00006123-199605000-00001>
11. XU S, ZHANG W, CHEN T, WU C, ZHOU M. Neuronavigator-guided percutaneous radiofrequency thermocoagulation in the treatment of intractable trigeminal neuralgia. *Chin Med J (Engl)* [Internet]. Ovid Technologies (Wolters Kluwer Health); 2006;119(18):1528–35. Available from: <http://dx.doi.org/10.1097/00029330-200609020-00005>
12. Bogduk N, Macintosh J, Marsland A. Technical Limitations to the Efficacy of Radiofrequency Neurotomy for Spinal Pain. *Neurosurgery* [Internet]. Oxford University Press (OUP); 1987;20(4):529–35. Available from: <http://dx.doi.org/10.1227/00006123-198704000-00004>
13. Kanpolat Y, Savas A, Bekar A, Berk C. Percutaneous Controlled Radiofrequency Trigeminal Rhizotomy for the Treatment of Idiopathic Trigeminal Neuralgia: 25-year Experience with 1600 Patients. *Neurosurgery* [Internet]. Oxford University Press (OUP); 2001;48(3):524–34. Available from: <http://dx.doi.org/10.1097/00006123-200103000-00013>
14. Gorton L, Ashour AM, Lebovitz J, Cosola Di A, Abdulrauf SI. Intractable vomiting caused by vertebral artery compressing the medulla: A case report. *J craniovertebral junction spine* [Internet]. 2015;6(2):89–91. Available from: <http://europepmc.org/articles/PMC4426530>
15. Higuchi Y, Nashold BS, Sluijter M, Cosman E, Pearlstein RD. Exposure of the Dorsal Root Ganglion in Rats to Pulsed Radiofrequency Currents Activates Dorsal Horn Lamina I and II Neurons. *Neurosurgery* [Internet]. Oxford University Press (OUP); 2002;50(4):850–6. Available from: <http://dx.doi.org/10.1097/00006123-200204000-00030>
16. Fang L, Ying S, Tao W, Lan M, Xiaotong Y, Nan J. 3D CT-Guided Pulsed Radiofrequency Treatment for Trigeminal Neuralgia. *Pain Pract* [Internet]. Wiley; 2013;14(1):16–21. Available from: <http://dx.doi.org/10.1111/papr.12041>
17. Burchiel KJ. Microvascular decompression for trigeminal neuralgia. *J Neurosurg* [Internet]. Journal of Neurosurgery Publishing Group (JNSPG); 2008;108(4):687–8. Available from: <http://dx.doi.org/10.3171/jns/2008/108/4/0687>
18. van Kleef M, Barendse G, Sluijter M. Response: Assessing a New Procedure: Thoracic Radiofrequency Dorsal Root Ganglion Lesions. *Clin J Pain* [Internet]. Ovid Technologies (Wolters Kluwer Health); 1996;12(1):77. Available from: <http://dx.doi.org/10.1097/00002508-199603000-00015>
19. Sandkühler J, Chen JG, Cheng G, Randić M. Low-Frequency Stimulation of Afferent A δ -Fibers Induces Long-Term Depression at Primary Afferent Synapses with Substantia Gelatinosa Neurons in the Rat. *J Neurosci* [Internet]. Society for Neuroscience; 1997;17(16):6483–91.

Available from:

<http://dx.doi.org/10.1523/jneurosci.17-16-06483.1997>

20. Onofrio BM. Radiofrequency percutaneous Gasserian ganglion lesions: results in 140 patients with trigeminal pain. *J Neurosurg. Journal of Neurosurgery Publishing Group*; 1975;42(2):132–9.

21. Cheng TMW, Cascino TL, Onofrio BM. Comprehensive study of diagnosis and treatment of trigeminal neuralgia secondary to tumors. *Neurology. AAN Enterprises*; 1993;43(11):2298.

22. Cheng JS, Sanchez-Mejia RO, Limbo M, Ward MM, Barbaro NM. Management of medically refractory trigeminal neuralgia in patients with multiple sclerosis.

Neurosurg Focus. American Association of Neurological Surgeons; 2005;18(5):1–5.

23. Erdine S, Ozyalcin NS, Cimen A, Celik M, Talu GK, Disci R. Comparison of pulsed radiofrequency with conventional radiofrequency in the treatment of idiopathic trigeminal neuralgia. *Eur J Pain [Internet]. Wiley*; 2007;11(3):309–13. Available from:

<http://dx.doi.org/10.1016/j.ejpain.2006.04.001>

24. Erdine S, Yucel A, Cimen A, Aydin S, Sav A, Bilir A. Effects of pulsed versus conventional radiofrequency current on rabbit dorsal root ganglion morphology. *Eur J Pain [Internet]. Wiley*; 2005;9(3):251. Available from: <http://dx.doi.org/10.1016/j.ejpain.2004.07.002>

Author Information

Ahmed Faisal Toubar, MD. PhD

Neurosurgery Department, Ain Shams University
Cairo, Egypt

Osama Mohamed Dawood, MD. PhD

Neurosurgery Department, Ain Shams University
Cairo, Egypt