

Infraclavicular Brachial Plexus Block

Citation

. *Infraclavicular Brachial Plexus Block*. The Internet Journal of Anesthesiology. 1999 Volume 5 Number 1.

Abstract

Patient Position: Supine

Common Indication: Hand, wrist, elbow and distal arm surgery

Equipment: A 10 cm long, short bevel, insulated stimulating needle; low output peripheral nerve stimulator.

Volume: Forty to fifty ml of local anesthetic of choice: 3% chloroprocaine, 1.5% mepivacaine, 2% lidocaine, all with or without NaHCO₃ and epinephrine. Ropivacaine 0.5% or bupivacaine are reserved for prolong procedures or postoperative analgesia.

Anatomical landmarks: The boundaries of the infraclavicular fossa are pectoralis minor and major muscles anteriorly, ribs medially, clavicle and the coracoid process superiorly, and humerus laterally. With infraclavicular approach, brachial plexus is approached at the level of the cords in the infraclavicular fossa in proximity to the coracoid process.

Technique:

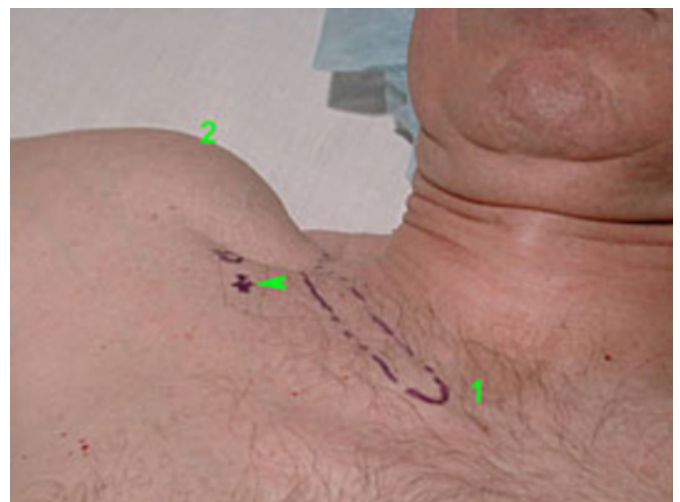
With the patient in the supine position, the block is best performed with the arm abducted at 90° angle and the patient's head facing away from the arm to be anesthetized (Figure 1).

The following anatomical landmarks are identified and marked:

1. Medial head of the clavicle
2. Acromion
3. Axillary artery
4. The midpoint between the points 1 and 2. (midpoint of the clavicle)

Figure 1

Figure 1: Infraclavicular block - landmarks. 1. Sternal (medial) clavicular head; 2. Acromion (the most prominent bony aspect of the shoulder); Arrow points the insertion site - 1 to 2 cm below the midpoint between 1 and 2.



The anesthesiologist stands at the opposite site to be blocked. The needle is inserted 2 cm below the midpoint of the clavicle and directed toward the axillary artery (Figures 2,3,4).

Figure 2

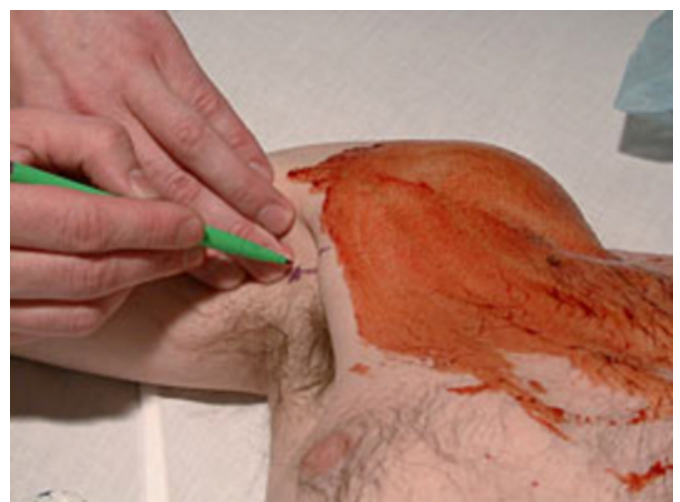

Figure 3

Figure 3: The insertion site is infiltrated with local anesthetic through a 25 G needle.

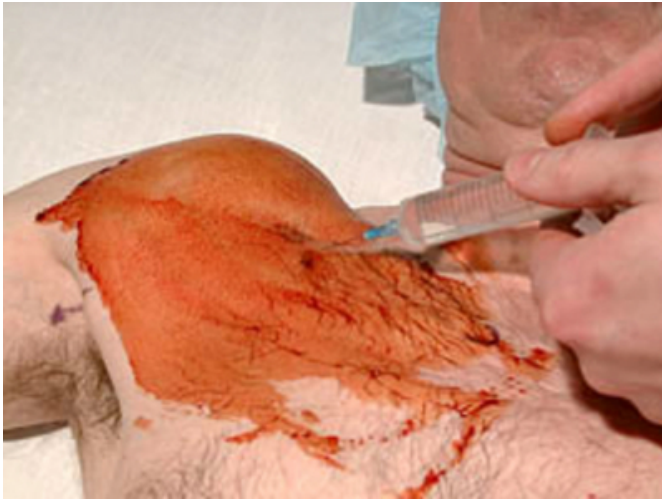
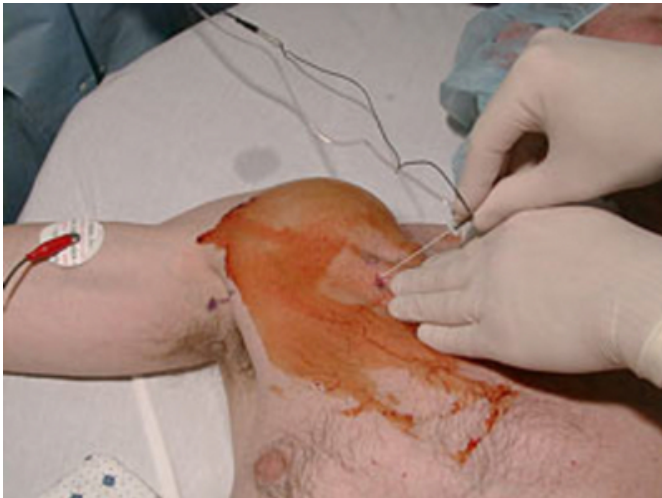
Figure 4

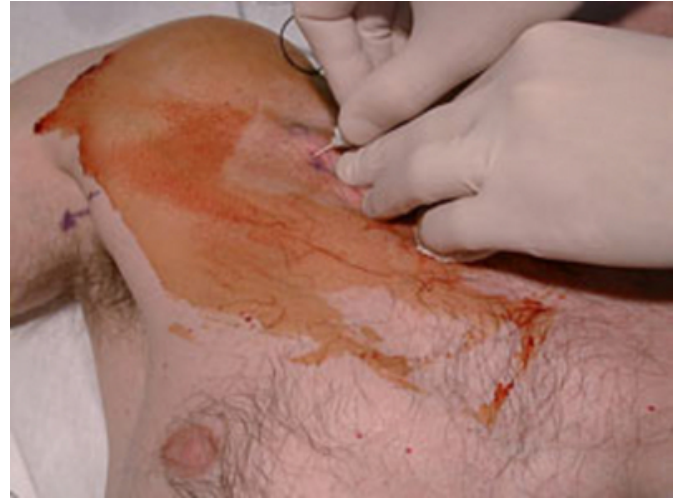Figure 4: A 10 cm long 22 G insulated needle, attached to a nerve stimulator is inserted and advanced toward the axillary artery. The needle usually assumes a 60 degree angle to the skin plane. Initial stimulating current is 0.6-0.8 mA.



With this approach, the needle commonly assumes an angle of 60° to the skin plane. The needle is slowly advanced until the twitches from hand or forearm are obtained (Figure 5).

Figure 5

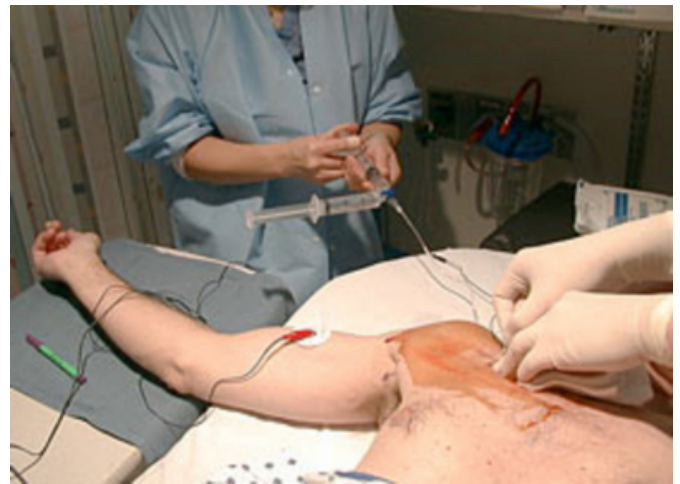Figure 5: Brachial plexus is reached at the depth of 6-8 cm.



The initial current of 0.6-0.8 mA is decreased to below 0.3 mA at which point 40 -50 ml of local anesthetic is injected (Figure 6).

Figure 6

Figure 6: The stimulating current is then gradually decreased until the sought response is still present at 0.3 mA or less. After negative aspiration for blood, 40-50 ml of local anesthetic is injected.



Tips:

- Success rate rapidly decreases with current above 0.3 mA
- Twitches from biceps muscle should not be accepted, since the musculocutaneous branch may be outside the brachial sheath.
- When the initial stimulation is that of the axillary nerve (deltoid muscle twitch) or of the

musculocutaneous nerve (biceps muscle), the needle should be redirected inferiorly (Figure 7).

Figure 7

Figure 7: Anatomy of the brachial plexus at the level of the coracoid process.

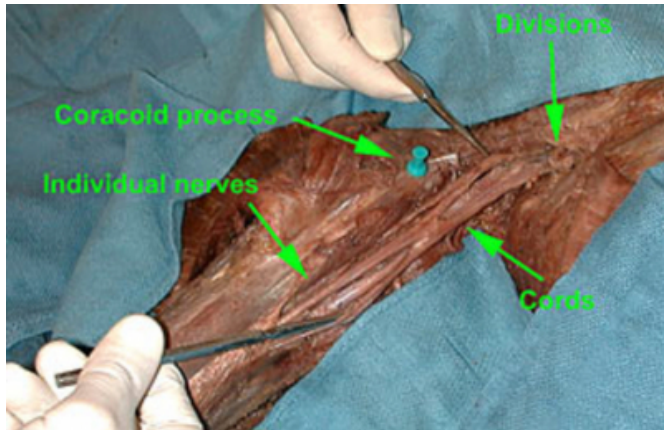


Figure 8



References

Author Information