

Neurocysticercosis In Detroit, Michigan

J Burneo, G Barkley

Citation

J Burneo, G Barkley. *Neurocysticercosis In Detroit, Michigan*. The Internet Journal of Neurology. 2002 Volume 2 Number 1.

Abstract

Neurocysticercosis (NC) is the most frequent parasitic disease of the Central Nervous System, and the most frequent cause of epilepsy worldwide (1,2,3). It is endemic in many regions of the world, and certain parts of the United States particularly the southwestern states of California and New Mexico. NC represents a major cause of morbidity among the immigrant Hispanic population. However, as the number of immigrants expanded, especially those from endemic areas, there have also been a progressive increase in the cases of NC in other parts of the country, in the past ten years.

We report nine cases of patients with NC, diagnosed at Henry Ford Hospital, in Detroit, between 1989 and 1999, were identified. All of them were immigrants to the United States, eight from Mexico and one from India.

INTRODUCTION

Neurocysticercosis (NC) is the most frequent parasitic disease of the Central Nervous System, and the most frequent cause of epilepsy worldwide (1,2,3). It is endemic in many regions of the world, and certain parts of the United States particularly the southwestern states of California and New Mexico. NC represents a major cause of morbidity among the immigrant Hispanic population. However, as the number of immigrants expanded, especially those from endemic areas, there have also been a progressive increase in the cases of NC in other parts of the country, in the past ten years.

Michigan is not considered an endemic region for NC. However, the latest U. S. census data has shown that the Hispanic population in Michigan has nearly doubled in the past decade, rising from 2.2% in 1990 to 3.5% in 2000 (4). Most of the increased Hispanic immigration into Michigan has come from people from Mexico. It is expected that a proportionate increase in NC will be seen in local hospitals. To estimate the magnitude of this problem, we reviewed the medical records at Henry Ford Hospital in Detroit, Michigan, for patients with NC in the past decade.

CASES

Nine patients with NC, diagnosed at Henry Ford Hospital, in Detroit, between 1989 and 1999, were identified (Table). All of them were immigrants to the United States, eight from Mexico and one from India.

Figure 1

Patient	Origin	Age	Sex	Year	Clinical Presentation	MRI	Findings	CSF	ELISA	EEG	Treatment	Evolution
1	Mexico	30	M	NNN	seizures	positive	active temporal lesion	neg	negative	no	PHT	favorable
2	Mexico	30	F	NNN	seizures	positive	active frontal lesion	neg	no	no	PZQ+PHT	favorable
3	Mexico	18	F	NNN	seizures	positive	active parietal lesion	neg	no	no	PHT	unknown
4	India	26	M	NNN	seizures	positive	active frontal lesion	neg	positive	no	surgery+ALB	deficit
5	Mexico	16	M	NNN	seizures	positive	active frontal lesion	neg	no	no	PHT	unknown
6	Mexico	17	M	NNN	seizures	positive	calcified frontal lesion	neg	no	no	PHT	favorable
7	Mexico	44	M	NNN	confusion halucinations	positive	calcified frontal lesion	neg	negative	norma	PZQ+PHT	favorable
8	Mexico	30	M	NNN	dimness amblyopia	positive	active multiple lesions	neg	negative	no	ALB	favorable
9	Mexico	28	M	NNN	seizures	positive	active frontal lesion	neg	negative	norma	ALB+PHT	favorable

None of the patients acquired the disease in Detroit or the United States. Seizures were the most common initial manifestation. CT and/or MRI provided the diagnosis of NC and contributed to follow-up. Brain imaging showed both viable cysts and calcifications (Figures). Cysticercosis serology, with ELISA, was performed in 3 out of 9 patients and was positive in only one patient and negative in two of them. Antiparasite treatment with albendazole or

praziquantel was provided to four patients, and surgical intervention to one. There were no deaths.

Figure 2

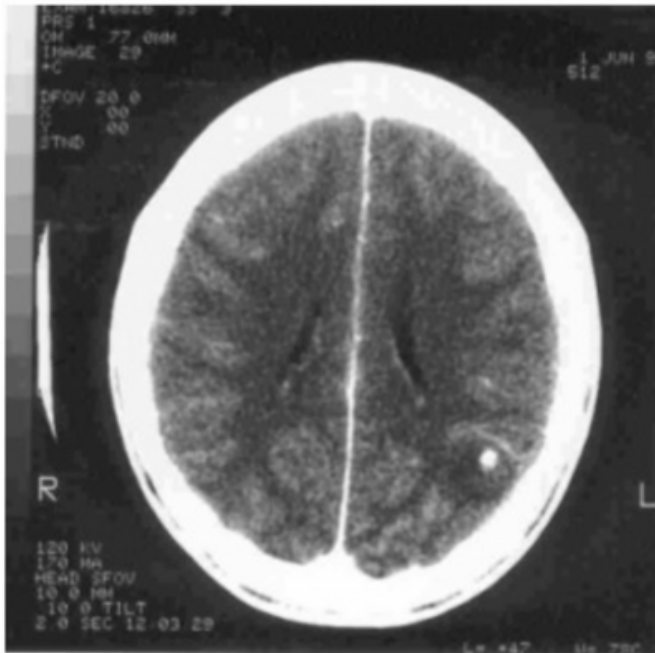


Figure 3

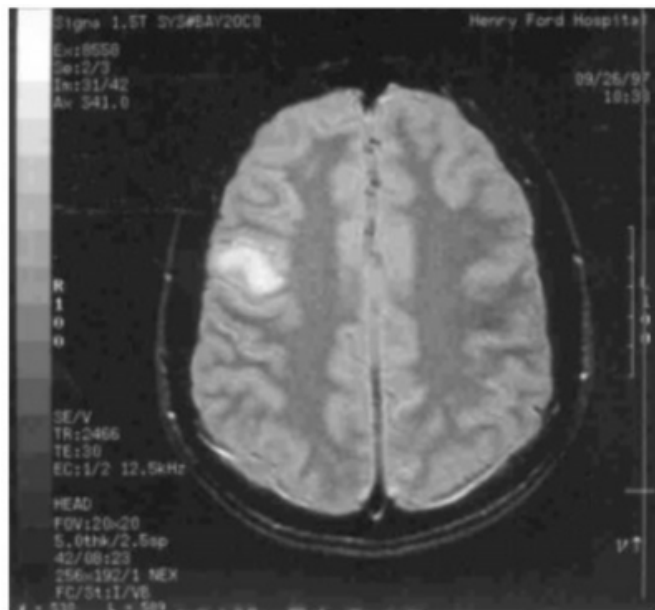
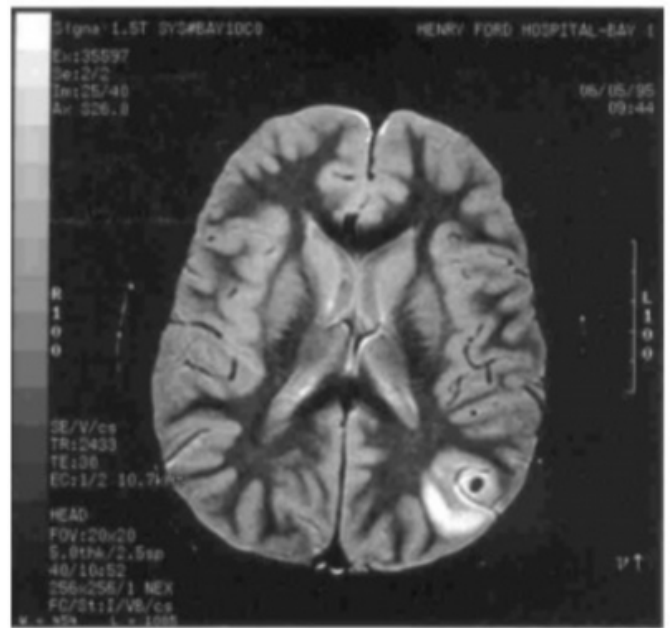


Figure 4



DISCUSSION

The clinical manifestations in the patients in our series do not differ from the ones reported in the medical literature. NC is a pleomorphic disease, although sometimes may not produce any clinical manifestation (2,3). Patients may seek medical attention because of headaches, seizures, and focal neurological or neurobehavioral manifestations.

NC is the leading cause of adult-onset epilepsy in areas of the world where the disease is endemic, particularly in the developing countries of Latin America, Asia, and Africa. Large series of patients with adult-onset epilepsy have demonstrated that NC occurs in up to 50% of cases, usually representing the single most common cause of this syndrome (5,6,7,8).

In the United States, *T. solium* taeniasis was virtually eliminated by improved animal husbandry and vigorous enforcement of meat inspection (9). Indeed, despite the fact that pigs were allowed to circulate freely in the streets of major cities in the nineteenth century, a reason why helminthes and their effects on health were a daily concern in that century (10), an exhaustive review of the literature revealed that less than 150 patients with NC were reported up to 1980 (3, 11). However, in the last few years, cases of NC have been reported in different states across the country, especially southern states, and not only in immigrants but also in locals (12). Currently the disease is prevalent in the states of California and New Mexico, and represents a major cause of morbidity among the immigrant hispanic population

(12, 13, 14).

Because the fast growth of the immigrant population in Michigan which increased by 60.7% in the past 10 years, neurological manifestations, especially seizures, in patients coming from endemic areas should prompt a search for NC with brain imaging. Serology should be part of the diagnosis work-up but was only performed in one third of the patients in our series. Antiparasitic medication should be started when appropriate. Resolution of symptoms and radiological findings with treatment confirms the diagnosis in cases in which the diagnosis may not be certain initially.

Neurologists and primary care physicians should be aware that NC is currently no longer a tropical disease seen only in the southwestern United States. NC should be considered in the differential diagnosis of immigrant patients with neurologic manifestations such as seizures in the northern states as well.

CORRESPONDENCE TO

Jorge G Burneo, MD UAB-Epilepsy Center Department of Neurology University of Alabama at Birmingham. CIRC 312. 1719 6th Avenue S. Birmingham, AL. 35294-0021 E-mail: jburneo@uab.edu Fax: (205) 934-3866 Phone: (205) 975-6255

References

1. Commission in Tropical Diseases of the International

- League Against Epilepsy. Relationship between epilepsy and tropical diseases. *Epilepsia* 1994; 35: 89-93.
2. Garcia HH, Martinez SM. *Taenia solium/Cysticercosis*. Lima: Editorial Universo; 1999.
3. Del Brutto OH, Sotelo J, Roman GC. *Neurocysticercosis: a clinical handbook*. Lisse: Swets & Zeitlinger; 1998.
4. U.S. Census Bureau, 2000 Census of Population and Housing, 1990 Census of Population and Housing.
5. Del Brutto OH, Santibañez R, Noboa CA, et al. Epilepsy due to Neurocysticercosis: analysis of 203 patients. *Neurology* 1992; 42: 389-92.
6. Lopez-Hernandez A, Garaizar C. Childhood cerebral Cysticercosis: clinical features and computed tomographic findings in 89 Mexican children. *Can J Neurol Sci* 1982; 9:401-7.
7. Garcia HH, Gilman R, Martinez M, et al. Cysticercosis as a major cause of epilepsy in Peru. *Lancet* 1993; 341: 197-200.
8. Sander JW, Hart YM, Johnson AL, Shorvon SD. National General Practice Study of Epilepsy: newly diagnosed epileptic seizures in a general population. *Lancet* 1990; 336: 1267-71.
9. Schantz PM, McAuley J. Current status of food-borne parasitic zoonoses in the United States. *Southeast Asian J Trop Med Publ Health* 1992; 22 (suppl): 65-71.
10. Snyder PJ, Cohen H. *Epilepsia Verminosa*. *J Hist Neurosci* 2001; 10: 163-172.
11. White JC, Sweet WH, Richardson EP Jr. Cysticercosis cerebri: a diagnostic and therapeutic problem of increasing importance. *N Engl J Med* 1957; 256: 479-486.
12. Shandera WX, White AC, Chen JC, et al. Neurocysticercosis in Houston, Texas. A report of 112 cases. *Medicine* 1994; 73: 37-51.
13. Cuetter JA, Guerra LG, Meza AD, Brower RD. Neurocysticercosis: a special problem in the southwestern United States. *J Trop Geogr Neurol* 1992; 2: 172-176.
14. Earnest MP, Reller LB, Filley CM, Grek AJ. Neurocysticercosis in the United States: 35 cases and a review. *Rev Infect Dis* 1987; 9: 961-979.

Author Information

Jorge G. Burneo, M.D.

UAB Epilepsy Center, Department of Neurology, University of Alabama at Birmingham

Gregory L. Barkley, M.D.

Director, Comprehensive Epilepsy Center, Department of Neurolog, Henry Ford Health System & Case Western Reserve University