

# Mesh Surgery For Pelvic Organ Prolapse: Encouraging Results In A Portuguese Center

C Pestana, F Reis, F Santos, M Silva, T Freitas, K Brazão, C Sousa

## Citation

C Pestana, F Reis, F Santos, M Silva, T Freitas, K Brazão, C Sousa. *Mesh Surgery For Pelvic Organ Prolapse: Encouraging Results In A Portuguese Center*. The Internet Journal of Surgery. 2020 Volume 36 Number 1.

DOI: [10.5580/IJS.55590](https://doi.org/10.5580/IJS.55590)

## Abstract

Pelvic organ prolapse (POP) affects up to 50% of women worldwide, and 11% of these women will eventually undergo surgical treatment. Transvaginal mesh procedures have thus been part of a surgical evolution attempting to overcome the high failure rates of native tissue repairs and minimize morbidity and invasiveness, however, non-standardized techniques and different materials used have resulted in varied outcomes and complication rates. The authors predisposed to analyze their center experience in pelvic floor surgery using a macroporous monofilament polypropylene transvaginal mesh - Prolift®.

## INTRODUCTION

Pelvic organ prolapse (POP) affects up to 50% of women worldwide<sup>1,2</sup>, and 11% of these women will eventually undergo surgical treatment<sup>3,4</sup>. A wide variety of techniques are available in POP surgery. Furthermore, over the last decade and given the success of mesh used in continence surgery, sacral colpopexy, and abdominal hernias, surgeons have utilized mesh at transvaginal repairs<sup>5</sup>. Biological or synthetic meshes are available. Type 1, non-absorbable macroporous monofilament polypropylene mesh is actually preferred for POP surgery as its pore size allows the passage of large immune cells, thus, decreasing some complications initially associated with microporous meshes. Due to similarities with native tissues, biologic grafts are more likely to undergo tissue remodelling and thus less likely to cause erosion. They can however be costly, and carry perioperative morbidity or theoretical infectious disease transmission<sup>6</sup>.

Transvaginal mesh procedures have thus been part of a surgical evolution attempting to overcome the high failure rates of native tissue repairs and minimize morbidity and invasiveness<sup>1,7</sup>, however, non-standardized techniques and different materials used have resulted in varied outcomes and complication rates<sup>8</sup>. Reports of pain, worsening sexual function, need for additional surgery, and other complications like mesh erosion, have called into question the risk-benefit ratio of transvaginal mesh placement<sup>3</sup> and

ultimately lead to a decline in its usage among many surgeons.

Given this controversy regarding meshes, the aim of this study was to analyze our center experience in pelvic floor surgery using a macroporous monofilament polypropylene transvaginal mesh - Prolift®.

## MATERIALS AND METHODS

We retrospectively reviewed data from computerized medical records at our Institution from January 2007 to December 2013. All 126 women presenting with POP surgically corrected with a macroporous monofilament polypropylene transvaginal mesh - Prolift® Gynecare (Ethicon), either anterior, posterior or total were included. The same surgical team treated all patients, according to the manufacturer's instructions.

Demographic data, medical history, prior pelvic surgery history, physical examination, main indication for surgery, concomitant procedures performed and perioperative complications were recorded.

Postoperative gynecological examination was performed in appointments with the main surgeon at months 1, 6 and 12, and then yearly. We recorded, patients' complaints, mesh related complications, failure and de novo prolapse that occurred in a time period of 4 years. Failure was defined as recurrent symptomatic prolapse and de novo prolapse as the one appearing in an initially unaffected and non-treated

vaginal compartment.

In addition to appointments' reports, an initial attempt to contact all women by phone call was made in September 2017 to assess their satisfaction with the procedure and treatment compliance (topical vaginal estrogen). We were able to contact 104 patients, 20 were unable to be reached and 2 were dead. The ones contacted were asked the following questions: "How do you feel about the surgery" "Do you maintain the regular application of the prescribed vaginal cream?"; the answers to the first question were categorized as "satisfied" or "not satisfied" depending on the report of any complaint directly related with the procedure.

### RESULTS

The Prolift<sup>®</sup> system was used to treat POP for 126 women. The mean age at time of surgery was  $63.6 \pm 7.7$  years, median parity was 3 (range 1-13) and mean Body Mass Index (BMI) was  $28.1 \pm 3.5$  kg/m<sup>2</sup>. 97.6% of patients (n=123) had postmenopausal status. (Table 1)

Twenty-six women (20.6%) had previous vaginal surgery. Previous surgery included vaginal hysterectomy with associated compartment correction (n=9), vaginal hysterectomy alone (n=8), posterior colporrhaphy (n=5), anterior and posterior colporrhaphy (n=3) and anterior colporrhaphy (n=1). (Table 1) In total, 14 of 126 women (11.1%) had the Prolift<sup>®</sup> procedure because of a recurrence of a previously treated POP – 7 (50.0%) in anterior compartment, 5 (35.7%) in posterior compartment and 2 (14.2%) in apical compartment.

The main indication for procedure was anterior compartment prolapse in 58.7% (n=74) of patients, followed by posterior compartment prolapse in 34.9% (n=44) and apical compartment prolapse in 13.5% (n=17). Concerning the operation performed, 67 women (53.2) were treated with anterior Prolift<sup>®</sup>, 37 (29.4%) with posterior Prolift<sup>®</sup> and 22 (17.5%) with total Prolift<sup>®</sup>. Concomitant vaginal hysterectomy was performed in 2 patients (1.6%), concomitant colporrhaphy in 5 (4.0%) and anti-incontinence surgery in 34 (27.0%). (Table 1)

Respective to complications, we had 1 (0.8%) intraoperative bladder injury that was repaired at the same time without any impact in the procedure. No other perioperative complications were recorded.

Concerning mesh related complications, 14 (11.1%) cases were recorded - 2 (14.3%) cases of infection (by months 1

and 3), 2 (14.3%) retractions (by months 24 and 36) and 10 (71.4%) cases of mesh erosion. 21 months (range 2-36) is the median time when erosions occurred and the implicated meshes were anterior (n=5, 50.0%), total (n=4, 40.0%) and posterior (n=1, 10.0%). 5 (50.0%) patients had complete excision of the mesh and 1 (10.0%) had partial excision, the remaining 4 (40.0%) patients were managed conservative.

During the 4 years follow up period, the vast majority of patients remained asymptomatic. In the first postoperative visit 30.2% (n=38) of patients reported any kind of urinary complaint, in the second visit, by the 6th month, only 9.5% (n=12) reported these. Pelvic pain or dyspareunia was the least prevalent complaint (2.4%, 0.8%, 1.6%, 0.8%, 1.6% and 1.6% by months 1, 6, 12 and years 2, 3 and 4 respectively). 4 years after surgery, 46.0% (n=58) of patients remained asymptomatic, 11.9% (n=15) reported urinary complaints, 1.6% (n=2) reported pelvic pain or dyspareunia, 0.8% (n=1) defecation complaints and 7.9% (n=10) others. (Graphic 1.)

Respective to failures, 5 (4.0%) were recorded during the follow-up period. The implicated meshes were anterior (n=2), posterior (n=1) and total (n=2); the median time when failure occurred was 24 months (range 12-36).

Fifty-four (42.8%) cases of POP after surgery were recorded, 32 (59.3%) were de novo. (Table 2.) A global reoperation rate of 11.9% (n=15) was observed: 46.7% (n=7) due to mesh related complications, 20.0% (n=3) due to failure, 20.0% (n=3) due to urinary incontinence and 13.3% (n=2) due to de novo prolapse. When asked about the surgery, 71 (68.3%) patients were satisfied. Fifty-one (49.0%) admit to use regularly the prescribed topical oestrogen.

**Table 1**

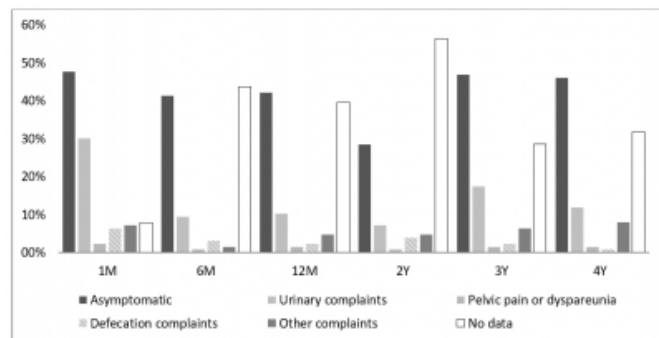
Characteristics of the study population

Variable	Value
Patients (n)	126
Age – years (SD)	63.6 (7.7)
Minimum	46
Maximum	83
Parity (range)	3 (1-13)
BMI – kg/m <sup>2</sup> (SD)	28.1 (3.5)
< 25 – n (%)	24 (19.0)
≥ 25 < 30 – n (%)	67 (53.2)
≥ 30 – n (%)	32 (25.4)
Menopausal status – n (%)	
Premenopausal	3 (2.38)
Postmenopausal	123 (97.6)
Previous vaginal surgery – n (%)	26 (20.6)
Vaginal hysterectomy + colporrhaphy	9 (34.6)
Vaginal hysterectomy	8 (30.8)
Posterior colporrhaphy	5 (19.2)
Anterior and posterior colporrhaphy	3 (11.5)
Anterior colporrhaphy	1 (3.8)
Main indication for procedure – n (%)	
Anterior compartment prolapse	74 (58.7)
Posterior compartment prolapse	44 (34.9)
Apical compartment prolapse	17 (13.5)
Prolift® Technique used – n (%)	
Anterior Prolift®	67 (53.2)
Posterior Prolift®	37 (29.4)
Total Prolift®	22 (17.5)
Associated surgery – n (%)	
Vaginal hysterectomy	2 (1.6)
Traditional colporrhaphy	5 (4.0)
Anti-Incontinence surgery	34 (27.0)

SD – Standard deviation

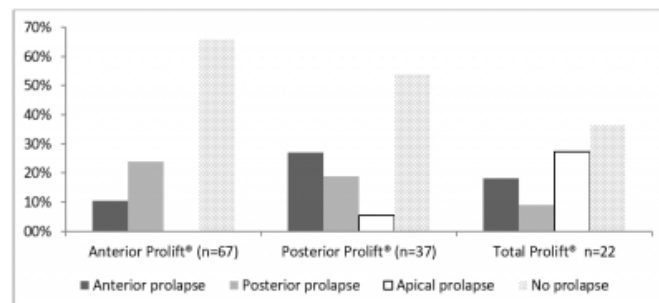
**Graphic 1**

4-year follow-up after Prolift® placement. Postoperative gynecological examination at months 1 (1M), 6 (6M) and 12 (12M), and then yearly (2Y, 3Y, 4Y).



**Graphic 2**

POP after Prolift® placement. Compartment prolapse after surgery according to the type mesh.



**DISCUSSION**

The main arguments for using a mesh in POP would be its superior efficacy and durability compared to native tissue repairs with fewer recurrences and reoperations. In our population of 126 women treated with Prolift®, 11.1% (n=14) have done it after a recurrence of a previous native tissue repair. This is one of the cases where mesh is an appropriate therapeutic option; others are, for example, prolapse stage 3 or 4, age less than 60 years and diabetes mellitus since they are all associated with an increased failure of native repairs<sup>9</sup>.

On the other side, mesh surgery exposes patients to mesh-related complications for which a woman undergoing a native tissue repair has no risk; mesh erosion, in particular, represents an important safety concern<sup>9</sup>. In our series, a global 11.1% (n=14) rate of mesh related complications was recorded, 10 of these were erosions, which means our rate of erosion (7.9%) was similar to 7% reported by Feiner et. al.<sup>10</sup>. As expected, anterior compartment was the one where the majority of them were reported (50.0%, n=5).

Management of vaginal erosion is quite straightforward, and a conservative treatment approach, with vaginal oestrogen and antibiotics, should always be attempted for asymptomatic patients. Additionally, in symptomatic ones, total excision is not always necessary<sup>2</sup>. In our study, only 4 (40.0%) patients were managed conservatively. It is generally accepted that the most important factor in preventing mesh erosion is a proper technique, which comes with proper surgeon training and experience<sup>11</sup>, our centre has the advantage of having a trained pelvic floor team of 3 surgeons performing all of these procedures. Patient related risk factors should also be carefully addressed and all patients should undergo thorough preoperative counselling regarding the potential serious adverse sequelae of transvaginal mesh repairs and the importance of therapeutic

adhesion.

Concerning intraoperative complications, the trocar-based vaginal mesh procedures like Prolift<sup>®</sup>, are associated with an increased rate of intraoperative cystostomy with a reported rate of 1.4%<sup>12</sup>, however, in our series, only 1 (0.8%) case was reported.

During the 4 years follow-up period, the vast majority of our patients remained asymptomatic, and the large per cent of patients reporting urinary complaints in the first operatory visit (30.2%, n=38), rapidly diminished by the 6th month (9.5%, n=12) and thereafter. Regardless of the surgical approach or the use of native tissue, biologics or mesh, postoperative pelvic pain is a common issue among patients<sup>11</sup>; however during our follow-up period, pelvic pain or dyspareunia were the least prevalent complaint (2.4%, 0.8%, 1.6%, 0.8%, 1.6% and 1.6% by months 1, 6, 12 and years 2, 3 and 4 respectively).

Concerning failures, different rates are described in the literature and some inconsistency exists partly due to the use of non-standardized grading systems for prolapse quantification, a 2016 Cochrane systematic review reported this risk to be 15.4%<sup>5</sup>. We recorded a failure rate of 4.0%.

Prolapse following surgery was often de novo, occurring in the compartment not surgically repaired (n=32; 59.3%). Whether to surgically repair non-prolapsed compartments concomitantly with surgical repair of prolapsed compartments remains an unresolved issue.

Some studies showed a significantly higher reoperation rate with mesh procedures; in the 2016 Cochrane systematic review, a reoperation rate of 11.4% versus 4.8% with native tissue repairs was mentioned<sup>5</sup>, however this was driven predominantly, even thought not exclusively, by reoperations due to mesh-related complications. Our results were similar since our global reoperation rate was 11.9% (n=15) and the majority was also due to mesh related complications (46.7%, n=7).

The majority of contacted patients were satisfied about the surgery, but only 49.0% admit to use regularly the prescribed topical oestrogen, a question raising concerns about mesh erosion risk.

One major limitation of this study is the large loss of information that occurred at the 2 years follow-up appointment. One explanation for this may be the

coincidence in time when the physical process of each patient was transferred to the computerized one, resulting in a loss of some data. Since this is a retrospective study this is an issue that we could not overcome. To our knowledge we present one of the largest follow up periods described in observational studies.

## CONCLUSION

This retrospective study confirms the safety of the Prolift<sup>®</sup> mesh kits for prolapse correction. 4-year follow-up shows no major morbidity and the majority of patients remained asymptomatic and satisfied with the procedure. As there are pros and cons in using a mesh in each vaginal compartment repair, the question whether to use it or not should be always answered on an individual basis.

## References

1. Khandwala S. (2013). Transvaginal Mesh Surgery for Pelvic Organ Prolapse: One-Year Outcome Analysis. *Female Pelvic Med Reconstr Surg*; 19: 84-89.
2. Vaiyapuri GR, Han HC, Lee LC, Tseng LAA, Wong HF. (2011). Use of the Gynecare Prolift<sup>®</sup> system in surgery for pelvic organ prolapse: 1-year outcome. *Int Urogynecol J*; 22:869-877.
3. Illston J, Garris J, Richter H, Wheeler T. (2015). Pain Scores and Exposure Rates After Polypropylene Mesh for Pelvic Organ Prolapse. *South Med J*; 108(12): 715-721.
4. Olsen AL, Smith VJ, Bergstrom JO, Colling JC, Clark AL et al. (1997). Epidemiology of surgically managed pelvic organ prolapse and urinary incontinence. *Obstet Gynecol*; 89:501-506.
5. Maher C, Feiner B, Baessler K, Christmann-Schmid C, Haya N, Marjoribanks J. (2016). Transvaginal mesh or grafts compared with native tissue repair for vaginal prolapse. *Cochrane Database Syst Rev*; 2:CD012079. \*\*
6. Dallenbach P. (2015). To mesh or not to mesh: a review of pelvic organ reconstructive surgery. *Int J Womens Health*; 7:331-343.\*
7. Franco E, Tardiu L, Mias N, Laguna L, Vicens L. (2012) Surgical Treatment of Vaginal Prolapse with Prolift<sup>®</sup> mesh in patients with risk of recurrence. *Arch. Esp. Urol*; 65 (6): 616-622.
8. Hong M, Chu T, Wei Y, Ding D. (2013). High success rate and considerable adverse events of pelvic prolapse surgery with Prolift: A single center experience. *Taiwan J Obstet Gynecol*; 52: 389-394
9. Kontogiannis S, Goulimi E, Giannitsas K. (2016). Reasons for and Against Use of Non-absorbable Synthetic Mesh During Pelvic Organ Prolapse Repair, According to the Prolapsed Compartment. *Adv Ther*; 33:2139-2149.\*
10. Feiner B, Jelovsek JE, Maher C. (2009). Efficacy and safety of transvaginal mesh kits in the treatment of prolapse of the vaginal apex: a systematic review. *BJOG*; 116: 15-24.\*
11. Gaines N, Gupta P, Sirls LT. (2016). Pelvic Prolapse Repair in the Era of Mesh. *Curr Urol Rep*; 17:20 11
12. McLennan GP, Sirls LT, Killinger KA, et al. (2013). Perioperative experience of pelvic organ prolapse repair with the PROLIFT<sup>®</sup> and ELEVATE<sup>®</sup> vaginal mesh procedures. *Int Urogynecol J*; 24(2):287-94

**Author Information**

**C. Pestana, Resident**

Department of Gynecology and Obstetrics, Nélío Mendonça Hospital  
Portugal

**F. Reis, Assistant**

Department of Gynecology and Obstetrics, Nélío Mendonça Hospital  
Portugal

**F. Santos, Assistant**

Department of Gynecology and Obstetrics, Nélío Mendonça Hospital  
Portugal

**M. Silva, Assistant**

Department of Gynecology and Obstetrics, Hospital de São João  
Portugal

**T. Freitas, Assistant**

Department of Gynecology and Obstetrics, Nélío Mendonça Hospital  
Portugal

**K. Brazão, Assistant**

Department of Gynecology and Obstetrics, Nélío Mendonça Hospital  
Portugal

**C. Sousa, Senior Assistant**

Department of Gynecology and Obstetrics, Nélío Mendonça Hospital  
Portugal