

Common Case, Rare Age: Invasive Breast Cancer At The Age Of 22

C Pestana, C Macedo, R Gomes, C Pereira, K Brazão, F Bacelar

Citation

C Pestana, C Macedo, R Gomes, C Pereira, K Brazão, F Bacelar. *Common Case, Rare Age: Invasive Breast Cancer At The Age Of 22*. The Internet Journal of Gynecology and Obstetrics. 2021 Volume 25 Number 1.

DOI: [10.5580/IJGO.55766](https://doi.org/10.5580/IJGO.55766)

Abstract

In 2018 there was an estimated 2.1 million newly diagnosed female breast cancer cases[1,2], 11,7% in women under the age 40 and <5% before age 35[1]. The incidence of breast cancer in women younger than 30 is very low, accounting for less than 0,5% of all cases[3]. Breast cancer at very young age is associated with worse outcomes in terms of prognosis and life expectancy and has shown to be an independent predictor of adverse outcomes[4]. There is evidence that tumors progress faster, present with higher grade, and more often are associated with negative hormone receptors when compared to tumors in older women[2,5]. The clinician who follows these patients faces three major difficulties: the scarce existing literature, unique challenges related to chemotherapy and adjuvant therapies-induced complications[4,6] and a higher chance of local and regional recurrence[7,8].

INTRODUCTION:

It is difficult to establish a clear age limit for ‘young’ women. The 40-year limit seems to be the most consensual among authors to better frame a cluster of patients with specific issues. Subjects like family planning, fertility preservation and genetic counselling differ not only from postmenopausal women but also from older premenopausal patients⁶. Breast cancer in young women is an uncommon condition and accounts for less than 0,5% of all cases in women younger than 30³. There is evidence that tumors progress faster, present with higher grade, and more often associated with negative hormone receptors and higher frequency of HER 2 overexpression when compared to tumors in older women^{2,5,8}. Young patients present worse prognosis than in more advanced age, with greater probability of local and regional recurrence^{2,7,8}. Some challenges arise age-related, not only the higher rates of morbidity and mortality, but also issues related to body image, self-development, family, social and professional dynamics, genetic mutations and also compromise of sexual and reproductive function⁸.

CASE REPORT:

A 22-years-old healthy female presented with mastodynia and feeling of engorgement and swelling in the left breast

(LB), for 2 months, at the department of senology. Clinical history revealed irrelevant personal background, unknown family history (foster care) and underwent no previous surgery. Smoker 10 cigarettes/day, for 3 years. Menarche achieved at the age of 10, regular cycles, non-hormonal contraception, GOP0.

Physical examination showed small volume asymmetric breasts, with larger LB, with a hard consistency and evident peripheral vascularization in all quadrants. No individualized nodules or masses were palpated. Nipple-areolar complex (NAC) were centered with no mastorrhea, bilaterally. Axillary palpation did not reveal any suspicious findings, bilaterally.

Following clinical findings, imaging tests were requested. Mammography revealed ACR C, of LB, with branched and pleomorphic microcalcifications that occupy most of the upper quadrant, R5 (American College of Radiology - Breast Imaging Reporting and Data System BI-RADS) and R2 of right breast (RB) (Image 1). Breast ultrasound was performed and showed no individualizable breast nodules but the presence of microcalcifications (Image 2), on the left side while on the right side, breast and right axilla presented normal characteristics.

Image 1

right breast; left breast; left breast with arrow indicating microcalcifications.

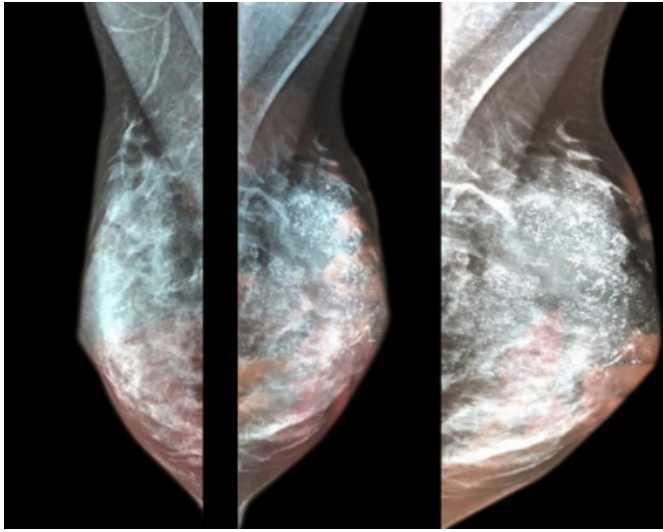
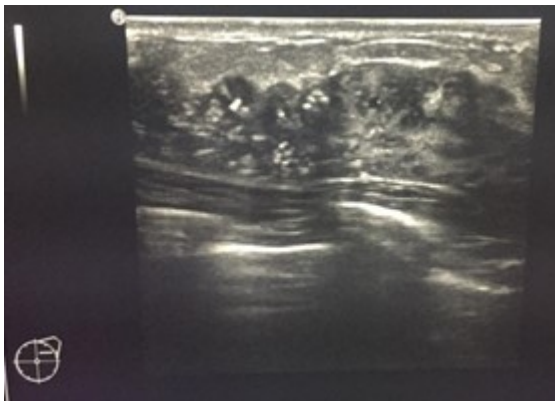


Image 2

arrow indicating microcalcifications in LB.

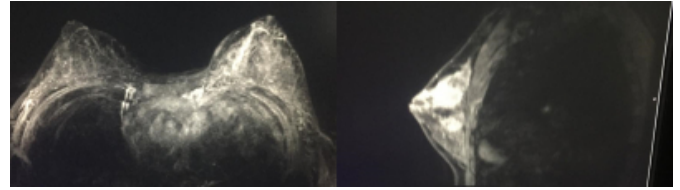


Left breast stereotaxic guided core biopsy was performed with a 1.1 mm focus of high-grade ductal carcinoma in situ with central necrosis and estrogen receptors (ER) and progesterone receptors (PR) both positive. The left axillary ultrasound guided core biopsy revealed non-malignant lymphoid tissue.

Magnetic resonance imaging (MRI) was requested and revealed a pathological contrast enhancement with centripetal distribution throughout the LB parenchyma, R6, and another pathological contrast enhancement in the inner-upper quadrant of RB, R4 (Image 3).

Image 3

Bilateral mammary MRI; left breast MRI.



Second-look RB ultrasound was performed, showing no pathological changes. Due to the discrepancy between imaging exams and pathological anatomy, a vacuum assisted core biopsy was done. The result was invasive grade 2 ductal carcinoma with ER + (80%), PR + (80%), Her2 + (cerb2 3+), Ki-67 of 35%, along with high-grade ductal carcinoma in situ with central necrosis. RB MRI-guided biopsy revealed fibrosis and healthy breast tissue.

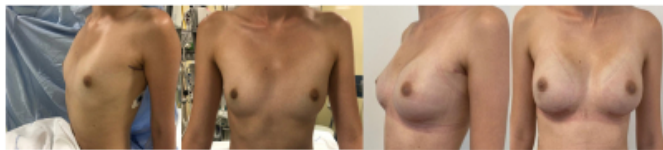The case and prognosis were discussed with the patient. A pre neoadjuvant-chemotherapy left sentinel lymph node biopsy was proposed, as well as preservation of fertility with vitrified oocytes after ovarian stimulation with letrozole. Genetic testing was negative for mutations with high risk for breast/ovarian cancer. A left mastectomy was proposed but the patient chose bilateral mastectomy (right prophylactic).

Left sentinel lymph node (identified with blue dye due to unavailability of other methods at the time such as iron, indocyanine green or technetium) revealed carcinoma metastasis in 2/4 lymph nodes. Systemic staging exams showed no alterations (peripheral blood, bone scintigraphy and thoracic-abdomin-pelvic computed tomography scan).

Neoadjuvant chemotherapy with doxorubicine, cyclofosamide, taxanes and double HER 2 block with transtuzumab and pertuzumab. Granulocyte colony stimulating factor (GCSF) was also administered. No major complications occurred. The post-chemotherapy imaging reassessment revealed a partial imagiological response and overlapping images for inner-upper quadrant of RB. Skin-sparing mastectomy and NAC was performed, bilaterally (with negative intra-operative examination of the right and left nipple's base). Additionally, left axillar lymphadenectomy was performed (0 metastases in 8 ganglia) with a TNM ypTis;N0;LV0;R0. Immediate breast reconstruction followed mastectomy with 2 anatomical silicone prosthesis. At day 14 after surgery the patient presented an extrusion of the left prosthesis, undergoing a surgical replacement.

Image 4

Pre mammary surgery; 3 months post mammary surgery.



In the multidisciplinary appointment it was agreed to start therapy with exemestane and goserrelin (for 5 years), alendronic acid and trastuzumab (for 12 months) in association with axillary radiotherapy. A 10-year-long-term follow up was defined along with smoking cessation appointments and regular physical exercise.

DISCUSSION:

Signs and symptoms in the breasts at a very young age can lead to the assumption of diagnoses of benignity due to the relative infrequency of breast cancer in this group⁹. Tumor diagnosis can be delayed, and thus contribute to more advanced stages of this disease at younger ages. Sentinel node biopsy was decided before the on-set of primary systemic treatment due to little experience with breast carcinomas at such early ages, with the intention of surgical staging without any effects of therapy. Oncoplastic techniques, performed by a trained breast surgical team, can improve aesthetic results, with complications delaying adjuvant treatments in less than 2% of cases⁶. Whenever a mastectomy is the preferred choice, skin and nipple-sparing techniques can be considered as locoregional recurrence rates are comparable with standard mastectomy⁶. For this reason, we opted for immediate reconstruction with preservation of skin and NAC. The option of choosing tamoxifen with a gonadotropin-releasing hormone (GnRh) agonist was weighted, as it is better tolerated at young ages and also due to the overexpression of Her2 in tumoral cells. The discrepancy between the pathological responses after chemotherapy (partial by imaging exams and complete at TNM post op or vice versa) are not uncommon. Taking into account the high risk of recurrence we opted for an steroid aromatase inhibitor, exemestane, and a GnRh agonist. The

patient's expectations regarding body image and reproductive future and the type of surgical approach should be discussed and addressed individually. Follow-up should be tight and prolonged as the probability of recurrence is higher at these ages compared to older women.

CONCLUSION:

Given the clinical suspicion of malignancy, breast exams should be requested even in young women without risk factors.

References

- 1 - F. Cardoso, S. Kyriakides, S. Ohno, F. Penault-Llorca⁴, P. Poortmans, I. T. Rubio, S. Zackrisson & E. Senkus, on behalf of the ESMO Guidelines Committee. Early breast cancer: ESMO Clinical Practice Guidelines for diagnosis, treatment and follow-up. *Annals of Oncology*, 2019, 30: 1194–1220, doi:10.1093/annonc/mdz173
- 2 - Sopik, V. International variation in breast cancer incidence and mortality in young women. *Breast Cancer Res Treat*, 2020, <https://doi.org/10.1007/s10549-020-06003-8>
- 3 – Hamilton, LJ. Cornford, EJ. Maxwell, AJ. A survey of current UK practice regarding the biopsy of clinically and radiologically benign breast masses in young women. *Clin Radiol.*, 2011, Aug;66(8):738-41. doi: 10.1016/j.crad.2011.03.008. Epub 2011 Apr 21. PMID: 21513922.
- 4 – Anders, C. Johnsonb, R. Littonc, J. Phillipsd, M. & Bleyere, A. Breast cancer before age 40 years. *Semin Oncol.*, 2009, June ; 36(3): 237–249. doi:10.1053/j.seminoncol.2009.03.001.
- 5 - Yao, Y. Cao, M. Fang, H. & Xie, J. Breast cancer in 30-year-old or younger patients: clinicopathologic characteristics and prognosis. *World Journal of Surgical Oncology*, 2015, 13(1), 38. doi:10.1186/s12957-015-0462-4
- 6 - Suter, M. B. & Pagani, O. Should age impact breast cancer management in young women? Fine tuning of treatment guidelines. *Ther. Adv. Med. Oncol*, 2018, 10, 1758835918776923. <https://doi.org/10.1177/1758835918776923>.
- 7 - Kothari, A. S. Beechey-Newman, N. D'Arrigo, C. Hanby, A. M. Ryder, K. Hamed, H. & Fentiman, I. S. Breast carcinoma in women age 25 years or less. *Cancer*, 2002, 94(3), 606–614. doi:10.1002/cncr.10273
- 8 - Villarreal-Garza, C. Lopez-Martinez, E. A. Muñoz-Lozano, J. F. & Unger-Saldaña, K. Locally advanced breast cancer in young women in Latin America. *Ecancermedicalscience*, 2019, 13. doi:10.3332/ecancer.2019.894
- 9 – Das, U. Lakshmaiah, KC. Lokanatha, D. Babu, G. Jacob, L. & Babu, S. Breast Cancer in Women of Younger than 35 Years: A Single Center Study. *J Mol Biomark Diagn*, 2015, 6: 261. doi:10.4172/2155-9929.1000261

Author Information

C. Pestana

Resident at the Department of Gynecology and Obstetrics, Nélío Mendonça Hospital
Portugal

C. Macedo

Resident at the Department of Gynecology and Obstetrics, Nélío Mendonça Hospital
Portugal

R. Gomes

Resident at the Department of Gynecology and Obstetrics, Nélío Mendonça Hospital
Portugal

C. Pereira

Resident at the Department of General Surgery, Nélío Mendonça Hospital
Portugal

K. Brazão

Assistant at the Department of Gynecology and Obstetrics, Nélío Mendonça Hospital
Portugal

F. Bacelar

Assistant at the Department of Gynecology and Obstetrics, Nélío Mendonça Hospital
Portugal