

# The Missing 'Speaking Valve'

P Puttasiddaiah, S Berry, M Kumar

## Citation

P Puttasiddaiah, S Berry, M Kumar. *The Missing 'Speaking Valve'*. The Internet Journal of Otorhinolaryngology. 2005 Volume 4 Number 2.

## Abstract

Aspiration of the voice prosthesis should be thought of when it is missing. These patients may be relatively asymptomatic on presentation and hence a fibre-optic endoscopic examination of the trachea and the main bronchi should be carried out in the out-patient itself.

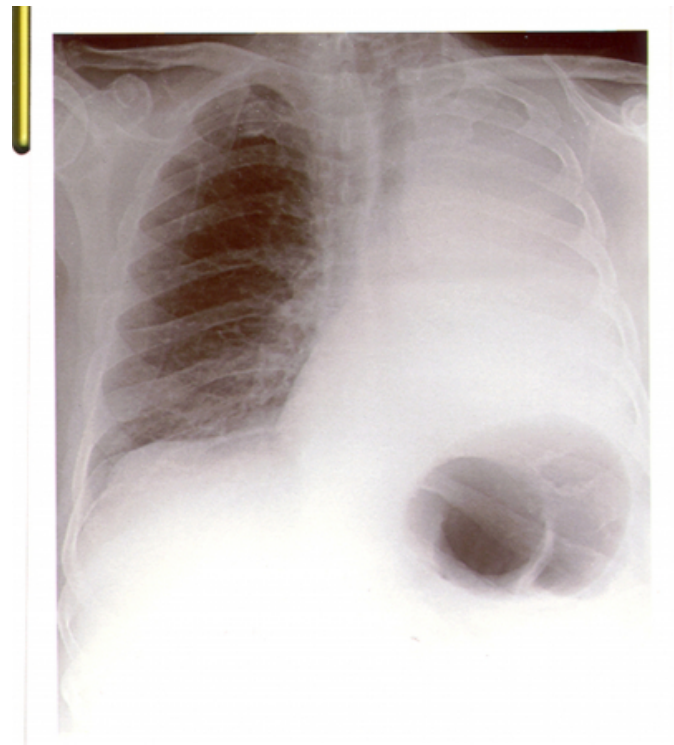
## CASE HISTORY

A 76 year old man underwent total laryngectomy for laryngeal carcinoma. A tracheo-oesophageal puncture was carried out at the same time and a Provox 2 voice prosthesis was inserted. On discharging from the hospital, arrangements were made for regular follow up in the out patient clinic. The patient reported that his Provox 2 voice prosthesis was missing for few days while attending a routine follow up out patient clinic, 4 months after the operation. He complained of slight difficulty in breathing but remained systemically well.

Examination of the trachea and the main bronchi with a flexible endoscope revealed 'the missing valve' in the left main bronchus with surrounding granulation tissue obstructing the bronchus. A chest X ray was performed (Fig 1) prior to arranging an emergency bronchoscopy under general anaesthesia to retrieve the prosthesis. Patient was admitted and treated with systemic antibiotics. A repeat Chest X ray confirmed considerable improvement.

## Figure 1

Figure 1: Chest X ray showing left lung collapse.



## DISCUSSION

Several methods have been advised for the restoration of voice after total laryngectomy. The Provox voice prosthesis is a silicone device for surgical rehabilitation of voice in laryngectomised patients. The prosthesis is placed in a fistula created through the tracheo-oesophageal wall either at the time of the primary operation or later as a second stage independent procedure. The prosthesis is self retaining and has got an average life span of 3-6 months. Of the various prostheses currently available, the Provox has been the most

popular due to its superior design. Provox 2 is a second generation prosthesis and can be inserted through the tracheostoma as an anterograde procedure.

Aspiration of the voice prosthesis is a complication reported before<sup>1</sup>. This usually occurs when the patient himself attempts to replace the prosthesis in the tracheo-oesophageal puncture. Replacing the Provox 2 valve is done almost exclusively in a hospital setting either by an otolaryngologist or by a speech therapist. Even when aspiration occurs, the prosthesis usually lodges above the carina<sup>2</sup>. Good stomal occlusion followed by a forceful cough is all that is necessary to expel the lodged prosthesis. Total collapse of an entire side of the lung as happened in our case is extremely rare. However, severe pneumonia induced by aspiration of a

voice prosthesis has been reported<sup>3</sup>.

### **CORRESPONDENCE TO**

Manoj Kumar Dept of Otolaryngology Singleton Hospital  
Swansea SA2 8QA E mail: manoj.kumar@doctors.org.uk

### **References**

1. Andrews JC, Mickel RA, Hanson DG, Monahan GP, Ward PH. Major complications following tracheoesophageal puncture for voice rehabilitation. *Laryngoscope*. 1987; 97: :562-7
2. Izdebski K, Reed CG, Ross JC, Hilsinger RL Jr. Problems with tracheoesophageal fistula voice restoration in totally laryngectomized patients. A review of 95 cases. *Arch Otolaryngol Head Neck Surg*. 1994; 120: 840-5
3. Garcia Alvarado M, Yebra Bango M, Arellano Rodriguez B, Jaurena Churi J, Garcia Gasalla M. Torpid pneumonia secondary to the aspiration of a phonation prosthesis. *Rev Clin Esp*. 1999; 199: 481-2

**Author Information**

**P. Puttasiddaiah**

Departments of Otolaryngology, Royal Glamorgan Hospital

**S. Berry**

Singleton Hospital

**M. Kumar**

Departments of Otolaryngology, Royal Glamorgan Hospital