

# Study Of Keloids In Children In The Plastic Surgery Department Of The Aristide Le Dantec Hospital In Dakar

A Ndiaye, L Ndiaye, M Foba, C Deme, A Sankale

## Citation

A Ndiaye, L Ndiaye, M Foba, C Deme, A Sankale. *Study Of Keloids In Children In The Plastic Surgery Department Of The Aristide Le Dantec Hospital In Dakar*. The Internet Journal of Plastic Surgery. 2023 Volume 16 Number 1.

DOI: [10.5580/IJPS.56593](https://doi.org/10.5580/IJPS.56593)

## Abstract

**INTRODUCTION:** Keloids are benign fibrous tumours of the skin, usually formed as a result of abnormal scarring. They most frequently affect melanodermal subjects without distinction between men and women, children and adults. With frequent recurrences, its management requires therapeutic combinations and treatment over a long period of time. The aim of our work was to report on the management of keloids in children in our department.

**PATIENTS AND METHODS:** We conducted a retrospective study covering the period from January 1st 1996 to December 31st 2020 in the Department of Plastic Reconstructive and Aesthetic Surgery at Aristide Le Dantec Hospital in Dakar. The records of 152 patients under 16 years of age were collected. We analysed age, sex, location of the keloid, treatment and complications.

**RESULTS:** The mean age was 8.3 years and the sex ratio was 0.52. Auricular location was the most frequent. One hundred and twenty-two patients were treated. Dermal corticosteroid infiltration alone was performed in 52.5% of cases or combined with surgery in 47.5% of cases. Pressure therapy was systematic. We obtained complete involution of the keloids in 41.7% of cases and recurrence in 13.3% of cases. Minor complications occurred in 26.6% of our patients. The rate of patients lost to follow-up treatment was 50.8% of cases.

**CONCLUSION:** The treatment of keloids in children is complex. Dermocorticoid infiltration alone or combined with surgery is the best available/cost/effectiveness ratio in our conditions but this strategy requires compliance and monitoring of the treatment to avoid recurrence or complications.

## INTRODUCTION

Keloids are benign fibrous tumours of the skin, usually formed as a result of abnormal scarring. They most frequently affect melanodermal subjects without distinction between men and women, children and adults. With frequent recurrences, its management requires therapeutic combinations and treatment over a long period of time. The aim of our work was to report on the management of keloids in children in our department.

## PATIENTS AND METHOD

We conducted a retrospective study covering the period from 1 January 1996 to 31 December 2020 in the Department of Plastic Reconstructive and Aesthetic Surgery at Aristide Le Dantec Hospital in Dakar. The records of 152 patients under 16 years of age were collected. We analysed age, sex, location of the keloid, treatment and complications.

## RESULTS

### Age and gender

The average age of our population at the time of the first consultation was 8.31 years with extremes ranging from 2 months to 15 years. The most represented age group was 10-15 years with 70 patients, i.e. 45.4% of the total number.

There were 100 girls and 52 boys, giving a sex ratio of 0.52.

Figure 1 shows the distribution of patients according to sex and age group.

### Family history of keloids

A family history of keloids was found in 29 patients (19.08% of cases).

### Average consultation time

The average consultation time from the appearance of the lesion was 22.5 months with extremes of 1 and 120 months.

**Location**

Our study found 11 locations. Auricular keloids were found in 102 patients, i.e. 42.1% of the total number, keloids of the face in 11.15% of cases and those of the thorax in 10.7% of patients. The lobule was involved in 68.6% of the ear lesions, i.e. 29% of the total number.

Figure 2 shows the distribution of lesions according to their location.

**Circumstances of occurrence**

Table 1 details the distribution of injuries according to the circumstances of occurrence. Figure 3 shows the main circumstances of occurrence according to gender.

**Treatment**

In our series, 122 patients were treated. The treatment was mainly carried out according to 2 therapeutic modalities:

- Intra-lesional corticosteroid infiltrations every 3 weeks in 52.5% of patients;
- surgery combined with corticosteroid infiltrations every 3 weeks in 47.5% of patients.

Table II details the modalities of triamcinolone infiltrations according to the therapeutic scheme.

**Evolution**

Complications were noted in 32 of the 122 patients treated (26.2%).

In the operated patients, the complications were as follows

- 3 cases of suture loosening ;
- 2 cases of post-operative infections ;
- 1 case of side effects related to intra-lesional corticosteroid therapy.

In the non-operated patients, we noted

- 11 cases of side effects related to intra-lesional corticosteroid therapy
- 3 cases of local infection

- 12 cases of skin pigmentation disorders such as hypochromia.

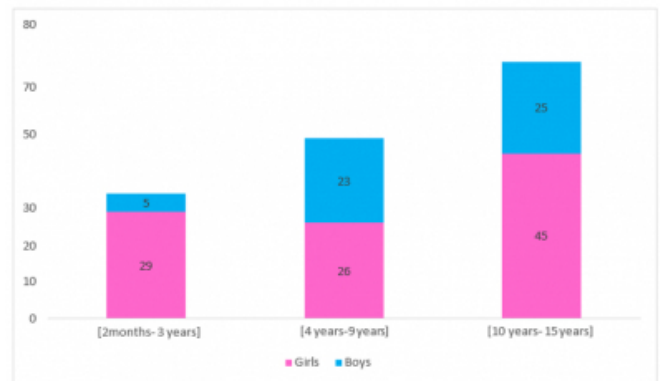
Table III shows the distribution of patients according to the evolution of the treatment.

Among the patients treated and regularly followed up :

- 41.7% had a total involution ;
- 45% had an incomplete involution;
- 13.3% had a recurrence.
- 50.8% were lost to follow-up, of which 24.6% were lost to surgery.

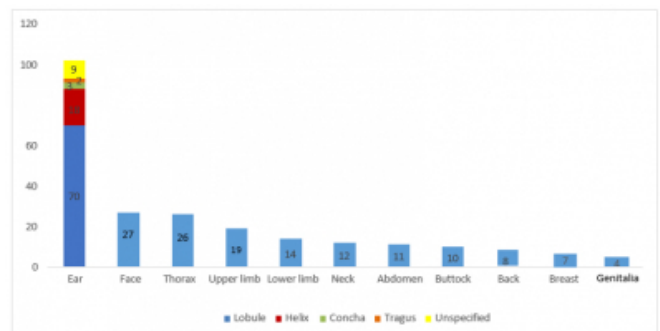
**Figure 1**

Distribution of patients according to age and gender



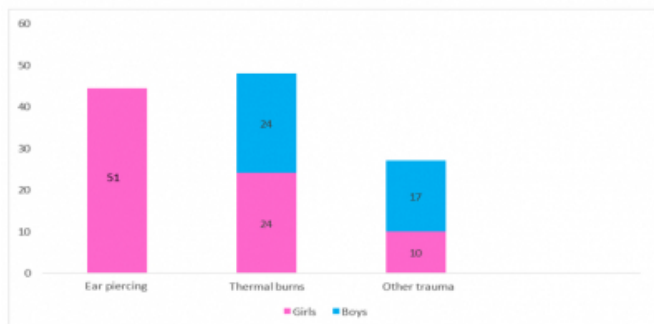
**Figure 2**

Distribution of lesions according to location



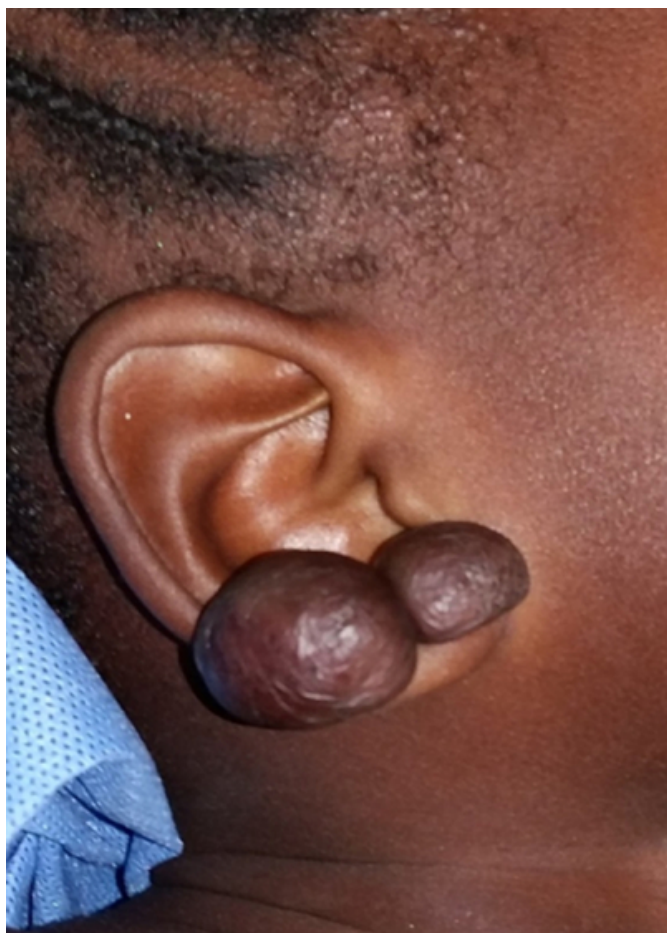**Figure 3**

Main circumstances of occurrence by gender



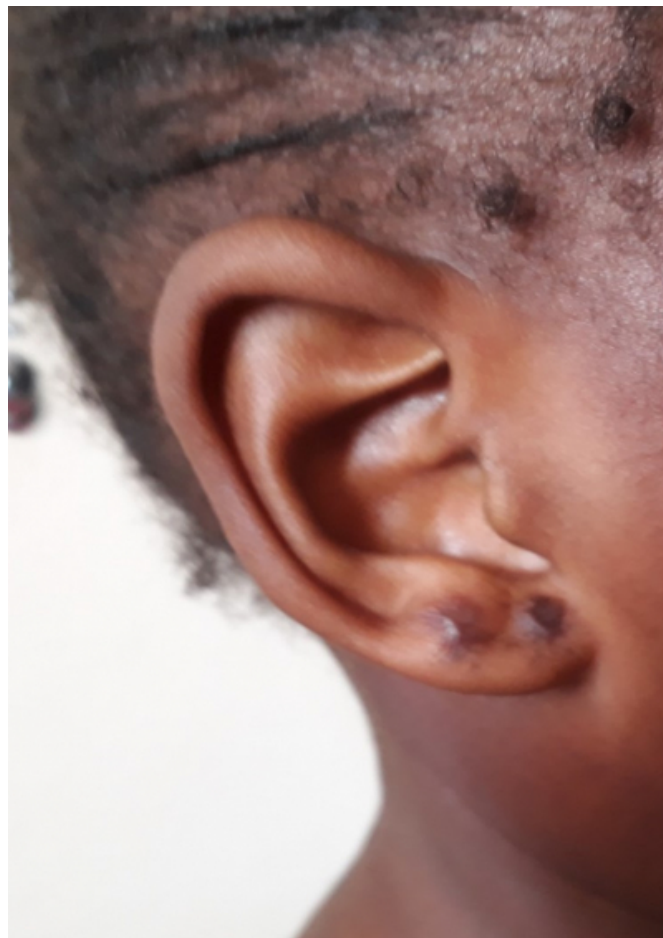**Figure 4**

Ear keloids before treatment



**Figure 5**

Ear keloids after surgery and infiltration



**Table 1**

Distribution of injuries according to the circumstances of occurrence

Circumstances	Number of patients	Percentage
Ear piercing	51	33,55%
Thermal burns	48	31,58%
Other trauma	27	17,76%
Spontaneous onset	10	6,58%
Infectious dermatosis	9	5,52%
Post-surgical onset	7	4,61%
<b>Total</b>	<b>152</b>	<b>100%</b>

**Table 2**

Triamcinolone infiltration modalities according to the therapeutic scheme

	operated patients	non-operated patients
number of sessions	6,8 sessions	5,7 sessions
average dose of triamcinolone per session	51,3mg	68,5mg
total dose of triamcinolone	379,5mg	377,9 mg

**Table 3**

Distribution of patients according to the evolution of the treatment

	operated patients	non-operated patients	Total
Total involution	14 (11,4%)	11 (9%)	25 (20,4%)
Partial involution	8 (6,6%)	19 (15,6%)	27 (22,2%)
Recurrence	4 (3,3%)	4 (3,3%)	8 (6,6%)
Lost to view	30 (24,6%)	32 (26,2%)	62 (50,8%)
Total	56 (45,9%)	66 (54,1%)	122 (100%)

## DISCUSSION

### Age

The most represented age group in our study was [10-15 years] with a mean age of 8.31 years. These results are similar to those found in the literature. Michael et al [1] found a mean age of 9.3 years in a retrospective study of 304 patients aged between 3 months and 18 years. These results are in line with the hormonal theory according to which the appearance of keloids is facilitated by sex hormones, which would explain the increase in keloids at puberty and during pregnancy [2]. Oestrogens and androgens are thought to cause local vasodilatation in the reticular dermis which facilitates the establishment of chronic inflammation at the source of the keloid [3]. Lane et al [4] also found that patients who had their ear pierced after the age of 11 years had more keloids than those who had been pierced before the age of 11.

### Gender

Our study found a sex ratio of 0.52 with a predominance of female patients in all age groups, particularly in the [2 months to 3 years] age group where there were 29 girls for only 5 boys. In Senegal, the ears of young girls are traditionally systematically pierced within a few days of birth. A second piercing during childhood is very common. Circumcision is also practised at a very early age for boys in Senegal. However, unlike the ears, the genitals are not an elective area for keloid formation and there are relatively few penile keloids in the literature [5,6]. This may explain

why keloids are more frequently found in girls than in boys.

### Family history of keloids

We had a family history of keloids in 19% of our patients, this figure rose to 10% in Michael's study in Nigeria. Several authors suggest a genetic origin of keloids. Chen et al [7] studied the genealogical data of 6 Chinese families of the Han ethnic group, practising strict endogamy, and found a genetic transmission profile consistent with the autosomal dominant mode, but with incomplete penetrance and variable expression. This incomplete penetrance would explain why not all patients with keloids reported keloids in other family members.

### Average time to consultation

In our study, the mean time to referral was 22.5 months [1-120 months] from lesion onset. These results differ from those in the literature, where average consultation times of 3.1 years, 5.4 years and even 9.5 years were found in studies carried out in France [8], Iraq [9] and Japan [2] respectively. This disparity between our results and those of the literature is paradoxical, as we would expect to find longer consultation times in a low-income country such as ours, where the supply of care is less extensive. This shorter delay can be explained by the fact that keloids are more aggressive in their evolution in melanodermal subjects, pushing them to consult earlier.

### Location

The most frequent location in our series was the ear with 102 keloids or 42.1% of the total number. The lobule was the most frequent auricular location with 29% of the total number. These results are similar to those of previous studies of paediatric keloids where the ear was frequently the predominant location, accounting for up to 90% of the total number in some series [10,11]. This predominance of ear lesions could be related to socio-cultural factors. Indeed, ear piercing is traditionally performed in childhood in several countries including Senegal. Studies carried out on adult patients, or on children from cultures where ear piercing is not systematically practised, have found other predominant locations such as the pre-sternal region in adults [12] and the upper limbs in children, where vaccines are thought to be involved [13].

### Circumstances of onset

Further analysis reveals that the circumstances of onset vary

greatly with age. Before the age of walking, the main circumstance for the appearance of keloids is ear piercing, which is traditionally done very early in little girls in Senegal, usually during the first week after birth. In the next age group, that of 2-9 years, the age of learning to walk and exploring the environment for the child, thermal burns are predominant. However, thermal burns are less common in the 10-15 year age group where keloids appear secondary to trauma or ear piercing.

### **Treatment**

There is no consensus on the optimal management of keloids and the treatment regimens found in the literature illustrate the great variability in therapeutic approaches. This variability also depends to a large extent on the resources available to practitioners. Some treatments such as interferons and radiotherapy are not very accessible in Senegal. In 2017, there was only one radiotherapy machine for the whole country, which was largely insufficient to meet the demand of cancer patients; moreover, its use should be avoided in children. Intra-lesional corticosteroid infiltrations, pressotherapy and, to a lesser extent, surgery, remain the means of treatment with the best availability/cost/efficiency ratio. Massage and pressure therapy were systematically recommended for all patients because of their accessibility. Surgical removal was never used alone; it was always combined with corticosteroid infiltration of the scar for fear of recurrence.

### **Evolution**

Complications secondary to the treatment were found in 18% of the patients treated: 22.7% of the complications arose from the surgery (suture loosening, infection) while 77.3% of the patients presented complications secondary to intra-lesional corticoid injections. Complications of intralesional corticosteroid injections are well known in the literature, with reports of skin pigmentation disorders, local infections, localised skin atrophy, ulcerations and telangiectasias [5]. But the most feared complication is Cushing's syndrome secondary to systemic passage of corticosteroids and which manifests itself by weight gain mainly on the face and trunk. Some authors have suggested that iatrogenic hypercorticism is more common in paediatric patients and may even occur with low doses [4,14]. In contrast to adults, there is some correlation between the frequency of systemic passage of corticosteroids and the size of the doses administered. Teelucksingh et al. report a case

of a 9-year-old girl who developed prolonged Cushing's syndrome after a single dose of 40 mg triamcinolone [15].

The main difficulty in treating keloids is their ability to recur. Recurrence rates of up to 100% have been reported in the literature [6]. Our study found recurrence in 6.56% of patients treated, a rate similar to that of Hamrick in the USA (6%).

We had a high number of patients lost to follow-up. Indeed, 71 patients, or 58.2% of cases, were lost to follow-up at different stages of treatment. These results are relatively similar to those of the literature where we find proportions of lost to follow-up ranging from 12.12% to 62.5% [12,16]. The duration of the treatment, its side effects, the pain caused by the infiltrations, the uncertainty as to the results and the possibility of recurrence are all factors favouring poor compliance with the treatment, regardless of income.

### **CONCLUSION**

The treatment of keloids in children is complex. Dermocorticoid infiltrations alone or combined with surgery are the best available/cost/effectiveness ratio in our conditions, but this strategy requires good monitoring and compliance with the treatment to avoid recurrence or complications.

### **References**

1. Michael AI, Ademola SA, Olawoye OA, Iyun AO, Adebayo W, Oluwatosin OM. Pediatric keloids: A 6-year retrospective review. *Pediatr Dermatol.* 2017 ; 34 (6) : 673-676.
2. Noishiki C, Hayasaka Y, Ogawa R. Sex Differences in Keloidogenesis: An Analysis of 1659 Keloid Patients in Japan. *Dermatol Ther (Heidelb).* 2019 ; 9 (4) : 747-754.
3. Ogawa R. Keloid and Hypertrophic Scars Are the Result of Chronic Inflammation in the Reticular Dermis. *Int J Mol Sci.* 2017 ; 18 (3) : 606.
4. Lane JE, Waller JL, Davis LS. Relationship between age of ear piercing and keloid formation. *Pediatrics.* 2005 ; 115 (5) : 1312-14.
5. Hietanen KE, Järvinen TA, Huhtala H, Tolonen TT, Kuokkanen HO, Kaartinen IS. Treatment of keloid scars with intralesional triamcinolone and 5-fluorouracil injections - a randomized controlled trial. *J Plast Reconstr Aesthet Surg.* 2019 ; 72 (1) : 4-11.
6. Lahiri A, Tsiliboti D, Gaze NR. Experience with difficult keloids. *Br J Plast Surg.* 2001 ; 54 (7) : 633-635.
7. Chen Y, Gao J-H, Liu X-J, Yan X, Song M. Characteristics of occurrence for Han Chinese familial keloids. *Burns.* 2006 ; 32 (8) : 1052-1059.
8. Sellier S, Boullie MC, Joly P, Dehesdin D. Treatment of keloids with shaving and cryosurgery: preliminary reports. *Ann Dermatol Venerol.* 2006 ; 133 (3) : 225-229.
9. Sharquie KE, Al-Dhalimi MA. Keloid in Iraqi patients : a clinicohistopathologic study. *Dermatol Surg.* 2003 ; 29 (8) : 847-851.

10. Bran GM, Goessler UR, Hormann K, Riedel F, Sadick H. Keloids: current concepts of pathogenesis (review). *Int J Mol Med.* 2009 ; 24 (3) : 283-293.
11. Sclafani AP, Gordon L, Chadha M, Romo T. Prevention of earlobe keloid recurrence with postoperative corticosteroid injections versus radiation therapy : a randomized, prospective study and review of the literature. *Dermatol Surg.* 1996 ; 22 (6) : 569-574.
12. Kouotou EA, Nansseu JR, Omona Guissana E, Mendouga Menye CR, Akpadjan F, Touunkara TM, et al. Epidemiology and clinical features of keloids in Black Africans : a nested case-control study from Yaoundé, Cameroon. *Int J Dermatol* 2019 ; 58 (10) : 1135-1140.
13. Acosta S, Ureta E, Yañez R, Oliva N, Searle S, Guerra C. Effectiveness of Intralesional Triamcinolone in the Treatment of Keloids in Children. *Pediatr Dermatol.* 2016; 33 (1) : 75-79.
14. Sanchez J, Antonicelli F, Tuton D, François C. Specificities in children wound healing. *Ann Chir Plast Esthet.* 2016 Oct ; 61 (5) : 341-347.
15. Teelucksingh S, Balkaran B, Ganeshmoorthi A, Arthur P. Prolonged childhood Cushing's syndrome secondary to intralesional triamcinolone acetonide. *Ann Trop Paediatr.* 2002 ; 22 (1) : 89-91.
16. Oluwasanmi JO. Keloids in the African. *Clin Plast Surg.* 1974; 1 (1) : 179-195.

**Author Information**

**Aï Ndiaye**

Dept. of Plastic and Reconstructive Surgery, Faculty of Medicine, Cheikh Anta Diop University; Aristide Le Dantec University Hospital Center

Dakar, Senegal

aninandiaye@yahoo.fr

**L Ndiaye**

Dept. of Plastic and Reconstructive Surgery, Faculty of Medicine, Cheikh Anta Diop University; Aristide Le Dantec University Hospital Center

Dakar, Senegal

**Ml Foba**

Dept. of Plastic and Reconstructive Surgery, Faculty of Medicine, Cheikh Anta Diop University; Aristide Le Dantec University Hospital Center

Dakar, Senegal

**Cat Deme**

Dept. of Plastic and Reconstructive Surgery, Faculty of Medicine, Cheikh Anta Diop University; Aristide Le Dantec University Hospital Center

Dakar, Senegal

**Aa Sankale**

Dept. of Plastic and Reconstructive Surgery, Faculty of Medicine, Cheikh Anta Diop University; Aristide Le Dantec University Hospital Center

Dakar, Senegal