

# Massive Odontogenic Fibromyxoma Of Maxilla

V Malhotra, A Sethi, S Malhotra, D Sareen, R Puri

## Citation

V Malhotra, A Sethi, S Malhotra, D Sareen, R Puri. *Massive Odontogenic Fibromyxoma Of Maxilla*. The Internet Journal of Oncology. 2004 Volume 3 Number 1.

## Abstract

We report the case of a 22-year-old male who presented to us with a large, hard swelling involving the right side of face with intranasal and intraoral extension of two years duration. A nasal biopsy revealed it to be a fibromyxoma. The patient underwent an extended total maxillectomy with complete excision of the mass. The patient is completely tumour free three years following surgery.

## INTRODUCTION

Myxomas are uncommon tumours occurring mainly in the left atrium of the heart. Among the bones, maxilla and mandible are most commonly affected by this tumour. Although benign, these tumours are locally destructive and aggressive and may extend into the nasopharynx, nose, paranasal sinuses or the orbit. The treatment options range from enucleation to extensive radical surgery, reports of highly aggressive varieties of myxoma with a fatal outcome advocate the need for a radical primary resection. The massive expansion of the maxilla with extensive involvement of the nose, oral cavity and facial soft tissues prompted us to report this case.

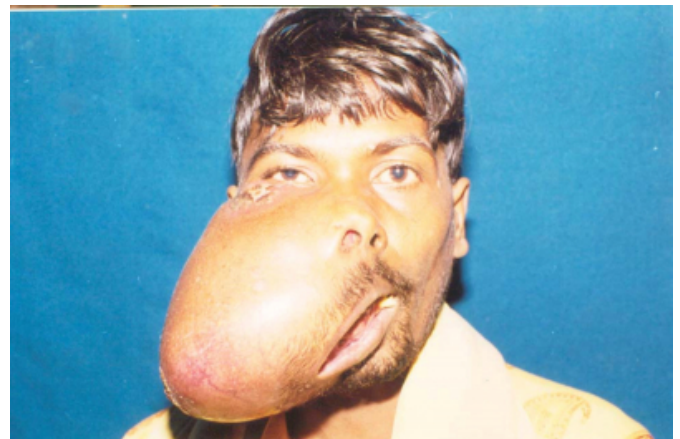## CASE REPORT

A 22-year-old male presented to us with a gradually enlarging, painless, non-tender mass involving the right half of the face of two years duration. It was also accompanied by a mass in right nasal cavity and oral cavity since one year. There was no history of hemorrhage from the mass or a sudden increase in size of the mass. The patient received treatment from various local practitioners in the form of some oral medications without any relief.

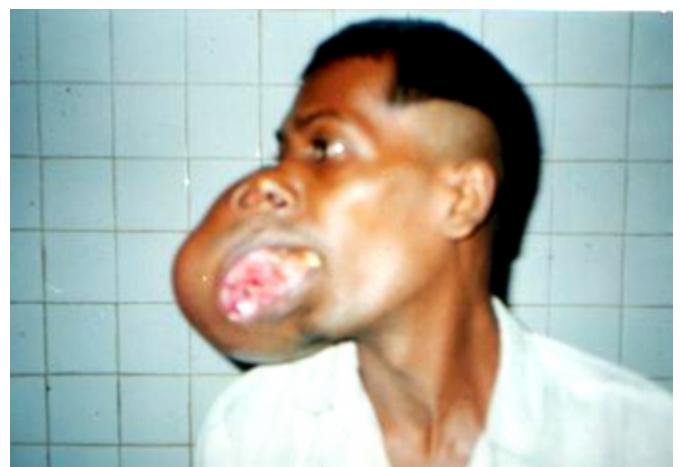On examination, the patient was found to have a hard, non-tender, fixed mass involving the right half of the face. The mass measured 20cm. X 15cm. X 10cm. (figures 1 & 2). The patient also had a firm, non-tender, grayish pink mass involving the right nostril, hard palate and oral cavity. The orbit was apparently free from the mass with normal visual acuity.

**Figure 1**

Figures 1 & 2: Massive facial deformity due to tumour.



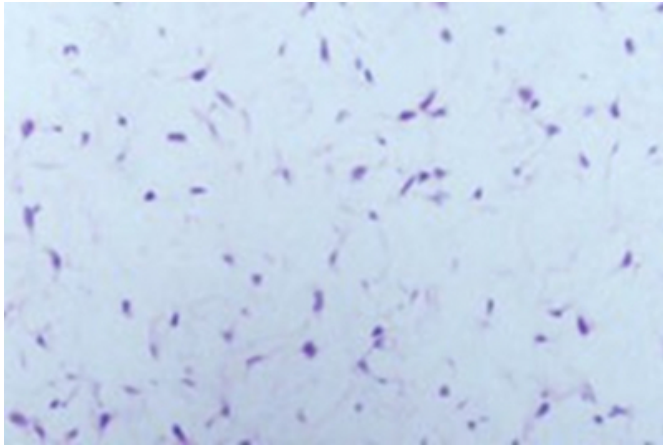
**Figure 2**



Routine blood and urine investigations and chest X-ray were normal. A biopsy from the nasal mass revealed a fibromyxoma (figure3).

**Figure 3**

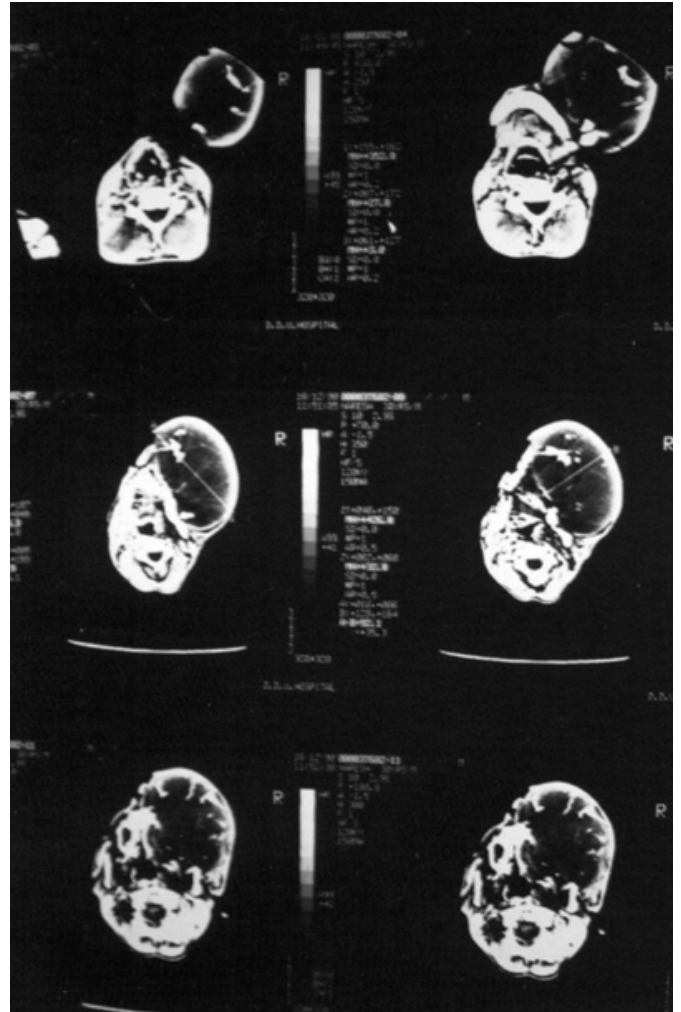
Figure 3: Stellate cells in a reticular stroma suggestive of myxoma (H & E staining, 250 X).



A CT-scan of the paranasal sinuses revealed an expansile mass involving the right maxillary antrum with gross expansion of the anterolateral wall of the maxilla, extension into the nasal cavity and destruction of turbinates, destruction of hard palate with extension into the oral cavity and partial destruction of posterior wall of maxillary antrum (figure 4).

**Figure 4**

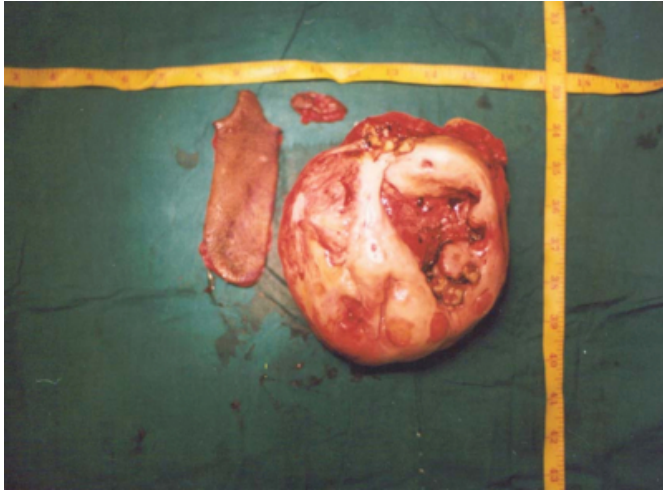
Figure 4: CT- scan (Axial views) showing extensive tumour with expansion of the maxillary antrum.



The patient underwent an extended total maxillectomy with complete excision of the mass and partial excision of overlying skin. The excised specimen measured 15cm. X 15cm. X 8cm. (figure 5). And the histopathologic evaluation was consistent with fibromyxoma. The patient has been regularly followed up and shows no signs of recurrence three years postoperatively.

### Figure 5

Figure 5: Excised specimen with partially excised skin.



### DISCUSSION

Odontogenic myxomas are rare tumours and considered to arise from connective tissues of dental papillae. They are histologically benign, being primarily composed of stellate cells in a reticular stroma. Due to markedly similar histologic features, they may be confused with a normal dental papilla.

The average age of presentation is between 25 to 30 years, although it may occur in patients within their first few months of life, and in much older individuals. Our patient was a 22-year-old male. The tumours tend to grow slowly and can reach sufficient size to produce considerable facial deformity, as in our case.

Although these tumours are benign, they may cause extensive local destruction with a tendency to recur after initial excision. Our patient also had a locally aggressive tumour with destruction of turbinates and hard palate. Malignant odontogenic myxomas are also reported in the

literature with an extremely rare occurrence and a fatal outcome. All these features strongly advocate the need for a primary radical excision of the tumour. Similarly our patient also underwent a radical surgery in the form of an extended total maxillectomy with orbital preservation.

### CONCLUSION

In conclusion, odontogenic fibromyxoma is an uncommon, slow growing, locally aggressive tumour which may present to the clinician with a sufficiently large size producing a massive facial deformity. The patient should be offered a radical primary excision to minimize the risk of recurrence of the tumour.

### CORRESPONDENCE TO

Dr Ashwani Sethi, E-80, Naraina Vihar New Delhi, INDIA  
Phone No: 91-11-55399725 E mail-  
dr\_sethi@rediffmail.com

### References

1. Allpin AL, Maniglia AJ, Gregor RT and Sawyer R. Myxomas of the mandible and maxilla. *Ear Nose Throat J* 1993; 72(4): 280-284.
2. Hasleton PS, Simpson W and Graig RP. Myxoma of the mandible- a fibroblastic tumour. *Oral Surg Oral Med Oral Pathol* 1978; 46(3): 396-406.
3. Perzin KH, Panyu H and Wechter S. Non-epithelial tumours of the nasal cavity, paranasal sinuses and nasopharynx. *Cancer* 1982; 50(10): 2193-2202.
4. Pratt MF and Warnock G. Odontogenic myxoma of the maxilla. *Otolaryngol Head Neck Surg* 1987; 96(3): 292-296.
5. Deron PB, Nikolovski N, den Hollander JC, Spoelstra HA and Knegt PP. Myxoma of the maxilla: a case with extremely aggressive behaviour. *Head Neck* 1996; 18(5): 459-464.
6. Latha P, Lisa W, Cynthia H, Lisa LC, Lawrence F, et al. Sinonasal myxoma: A pediatric case. *J Pediatr Hematol Oncol* 2005; 27(2): 90-92.
7. Cohen PB and Gamble JW. Maxillary resection for odontogenic myxoma. *J Oral Surg* 1997; 35: 573-577.
8. Pahl S, Henn W, Binger T, Stein U and Remberger K. Malignant odontogenic myxoma of maxilla: case with cytogenetic confirmation. *J Laryngol Otol* 2000; 114(7): 533-535.

**Author Information**

**Vikas Malhotra, M.S.**

Assistant Professor, Dept. of ENT, Maulana Azad Medical College, Associated L. N. Hospital

**Ashwani Sethi, M.S.**

Senior Resident, Dept. of ENT, Maulana Azad Medical College, Associated L. N. Hospital

**Shilpi Malhotra, B.D.S.**

Maulana Azad Medical College, Associated L. N. Hospital

**Deepika Sareen, M.B.B.S.**

Junior Resident, Maulana Azad Medical College, Associated L. N. Hospital

**Rajeev Puri, M.S.**

Senior Consultant, Dept. of ENT, Maulana Azad Medical College, Associated L. N. Hospital