

Nasal Septal Abscess Caused by Dental Infection: A Case Report

F Özan, S Polat, H Yeler

Citation

F Özan, S Polat, H Yeler. *Nasal Septal Abscess Caused by Dental Infection: A Case Report*. The Internet Journal of Otorhinolaryngology. 2005 Volume 4 Number 2.

Abstract

Nasal septal abscesses caused by dental infection are rare. We report a case of a nasal abscess caused by dental infection. In this manuscript development of the condition, possible complications, and treatment are discussed.

INTRODUCTION

Nasal septal abscesses caused by dental infection were rare. Three cases were found in the English literature. (1,2) We report a case of a nasal abscess caused by dental infection. In this manuscript development of the condition, possible complications, and treatment are discussed.

A nasal septal abscess (NSA) is defined as a collection of pus between the cartilage or bony septum and its normally applied mucoperichondrium or mucoperiosteum.³ NSA is a rare entity, but, if diagnosed and attended to promptly, it can be cured with little residual deformity of problems.⁴ On the other hand, neglect can lead to nasal collapse and even cavernous sinus thrombosis.^{3,4,5,6}

This pathology is often the result of an infected septal hematoma which can be a serious complication of trauma or surgery.^{1,5} The rupture of the small vessels that supply the nasal septum forms a hematoma that separates the mucoperichondrium from the septal cartilage. Cartilage destruction follows as a result of ischemic and pressure necrosis. The static blood and the necrotic cartilage form an adequate medium for the growth of the bacteria which normally colonize the nasal mucosa.^{3,5,7}

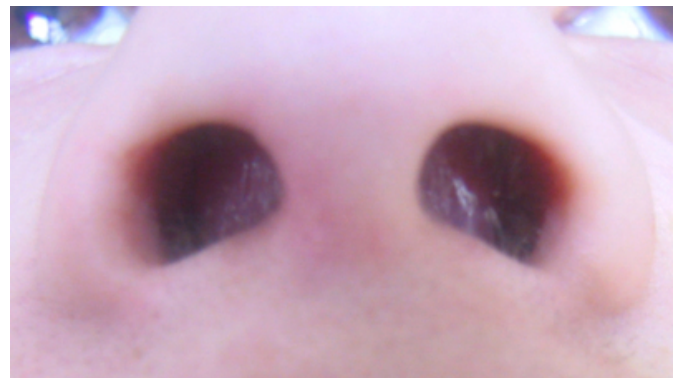The aim of this manuscript was presentation this rare condition, its life threatening complications, and how to manage it.

CASE REPORT

A 21-year-old woman presented with complaints of having something in her nose, pain, nasal airway obstruction and swollen upper lip.

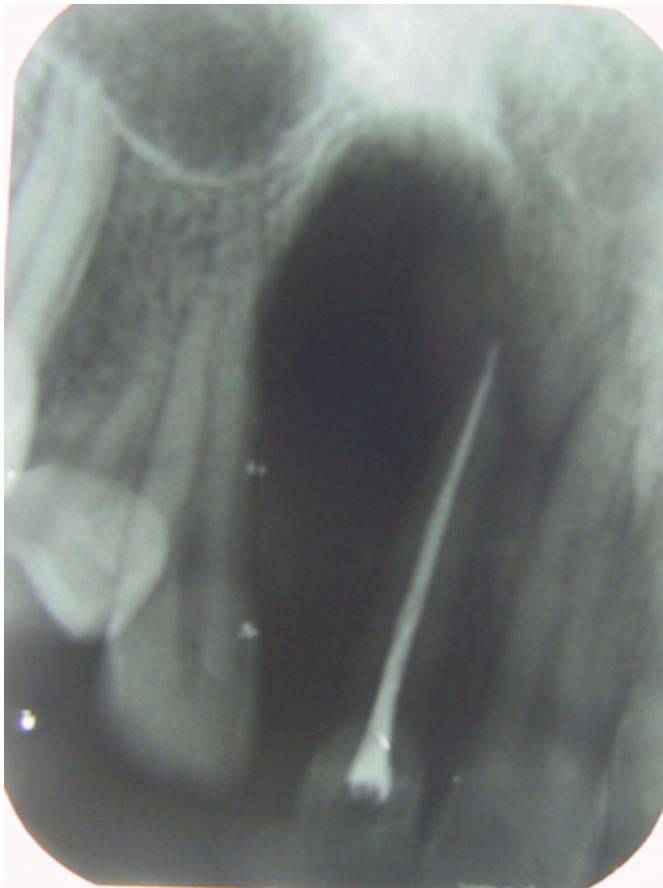
There is no history of trauma, sinusitis or surgical trauma. Two weeks prior to presentation at our institution, the patient had had root canal filling in dental office to upper left second incisor. A few days later after root canal therapy had been her complaint of pain, upper lip swollen and nasal obstruction occurred.. The physical examination at presentation was remarkable for an anterior round purplish mass in the nose which projected bilaterally from the nasal septum (Figure 1).

Figure 1



Her upper lip and perinasal areas were swelled and tender to palpation. Periapical radiograph was taken and it was observed that there was large periapical lesion associated with upper left second incisor that had been root canal filling (Figure 2).

Figure 2



Under topical anesthesia aspiration was attended, but we did not get enough pus on aspiration for microbiologic evaluation. Then she was started on 625mg amoxicillin + clavulanic acid twice a day (Bioment Ko-Amoksiklav BID, Fako, Istanbul, Turkey) and 550 mg naproxen sodium twice a day (Synax Fort, Biofarma, Istanbul, Turkey). Apical resection operation was planned when her acute symptoms were resolved. Three days after started on antibiotic regimen apical resection was made. At the operation we encountered larger apical lesion than seen on radiography. Lesion was extended to floor of the nasal cavity, we encountered greyish nasal mucosa. Granulation tissue was curetted and root tip excised. Pus that was small amount was drained from operation area. Postoperatively patient was continued on previous medication regimen for a week. At the time of suture removal nasal airway obstruction and upper lip swollen were totally resolved (Figure 3). After 1 month the patient showed no evidence of infection.

Figure 3



DISCUSSION

Abscess of the nasal septum are uncommon. The most common cause is infection of an untreated nasal septal hematoma following nasal trauma. More infrequently, nasal septal abscess occurs following nasal surgery, furunculosis of the nasal vestibule, sinusitis, influenza, and dental infections.⁵ Nasal obstruction is the most common presenting symptom seen with NSA. Other associated symptoms include throbbing nose pain, general malaise, fever, headache, and tenderness over the perinasal area.^{3,5,8} The presenting symptoms depend on the etiology of the NSA and the earliest symptoms are

usually those of a mild upper respiratory infection. Examination of the nose usually reveals bilateral swelling of the anterior septum that can range in color from gray to reddish purple. The size of the swelling depends on the stage at which the patient is examined. ³

The pathophysiology of a NSA depends on the aetiology of the abscess. There are several proposed mechanisms for the development of a NSA: (1) direct extension along the tissue planes as seen with sinusitis; (2) infection of a septal hematoma; (3) infections of dental aetiology; and (4) venous spread from the orbits or cavernous sinus. ³

As mentioned above a NSA can be followed by infection of the orbit or cavernous sinus by way of the ethmoidal and ophthalmic veins.^{1,4,5}

Piotrowski et al. reported a case of nasal septum abscess, complicated with cavernous sinus thrombophlebitis in a four-year-old child.⁶ The ophthalmic and angular veins are valveless, communicating from the danger area defined by a triangle formed from the glabella to the corners of the mouth. The lack of valves and the intracranial

communication via the cavernous sinus predisposes this area to the spread of infection.^{3,5} A nasal septal abscess is usually the result of an infected hematoma of the septum. A secondary septal abscess may be the result of infections extending from any of the neighboring tissues. Dental infections can reach to the septum by direct extension. Septic embolism through the bloodstream is highly improbable but cannot be excluded. The close relationship of the incisor teeth to the nasal floor explains the fact that an abscess arising from the central upper incisors may extend and bulge into the nasal floor.¹

Delayed diagnosis and treatment may lead to extensive destruction of the nasal skeleton. The septal cartilage may undergo necrosis secondary to interference with its blood supply by thrombotic vasculitis the pus separates the mucoperichondrium from the cartilage, causing ischemic necrosis, followed by further lysis by the bacteria. The lost cartilage is replaced with fibrous tissue that may scar and later lead to unorganized asymmetric contractions that will result in obstructive nasal symptoms.^{1,3,5}

Necrosis of the septal cartilage leads to septal deformity, perforation, and saddle nose deformity.^{1,3,5} Prevention of serious complications can be achieved only by prompt and effective surgical treatment. Different authorities advocate almost same treatment methods, as well antibiotic coverage, incision, drainage and packing.^{1,3,4,5,9} Antibiotic treatment has to be given immediately to prevent bacteremia, which will occur on manipulation of a mature abscess. Most often choice of antibiotic is Penicillin. Evaluation of aspiration samples reveals factor pathogenic organism which is usually *Staphylococcus*.^{1,5} Less often, it may be *Streptococcus pneumoniae* or β -hemolytic *Streptococcus*.¹ An incision across the swelling is made as near as possible to the floor of the

nose to prevent pocketing of the pus. Necrotic tissue and cartilage, granulations, and blood clots are removed. Drainage is provided by Penrose drain sutured in the incision. The packing serves both as a stent for the nasal skeleton and septum. It prevents reaccumulation of blood and pus.^{1,3,4,5} Mostly treatment protocol depends on infection's source.

Our treatment protocol is different from others. Since little amount of pus was observed and granulation tissues were curetted totally, extraoral drainage found unnecessary. However, the mass in the nose reduced significantly just after operation. There was no reaccumulation at the follow examinations. In our case usage of antibiotic and remove of source of infection seemed to be enough for treatment protocol because of uneventful healing.

References

1. da Silva M, Helman J, Eliachar I, Joachims HZ. Nasal septal abscess of dental origin. *Arch Otolaryngol* 1982;108:380-1.
2. Chopra S, Desai NT. Nasal septal abscess due to infection from upper incisors. *J Indian Dent Assoc* 1969;41:249-50.
3. Rafael Santiao, Villalonga P, Maggioni A. Nasal Septal Abscess: A Case Report. *Int Pediatr*. 1999;14:229-31
4. Bennett J, Rapado F. Nasal septal abscess in a healthy, non-immunocompromised patient. *Hospital Medicine* January 1998;59:78
5. Matsuba H, Thawley SE. Nasal Septal Abscess: Unusual Causes, Complications, Treatment, and Sequelae. *Ann Plast Surg* 1986;16:161-6
6. Piotrowski S, Augustyniak M, Bojarska D, Mielniczak K. Cavernous sinus thrombosis-complicaton of nasal septum abscess in children. *Wisd Lek*. 1994;47:155-7
7. Dispenza C, Saraniti C, Dispenza F, Caramanna C, Salzano FA. Management of nasal septal abscess in childhood: our experience. *Int J Pediatr Otorhinolaryngol*. 2004 68:1417-21
8. Cuddihy PJ, Srinivasan V. An unusual presentation of a nasal septal abscess. *J Laryngol Otol*. 1998;112:775-6
9. Ambrus PS, Eavey RD, Baker AS, Wilson WR, Kelly JH. Management of nasal septal abscess. *Laryngoscope* 1981;91:575-82

Author Information

Fatih Özan, DDS

Research Assistant, Department of Oral and Maxillofacial Surgery, School of Dentistry, Cumhuriyet University

Serkan Polat, DDS, PhD

Assistant Professor, Department of Oral and Maxillofacial Surgery, School of Dentistry, Cumhuriyet University

Hasan Yeler, DDS, PhD

Assistant Professor, Department of Oral and Maxillofacial Surgery, School of Dentistry, Cumhuriyet University