

Images In Clinical Medicine: Snake In The Brain

N Sethi, J Torgovnick, I Omeis, S Wright, S vanSwam, E Robilotti

Citation

N Sethi, J Torgovnick, I Omeis, S Wright, S vanSwam, E Robilotti. *Images In Clinical Medicine: Snake In The Brain*. The Internet Journal of Radiology. 2005 Volume 4 Number 2.

Abstract

Giant intracranial aneurysm is defined as one larger than 2.5 cm in maximum diameter. Treatment of giant aneurysms has traditionally been associated with a higher morbidity and mortality rate than smaller lesions. Giant aneurysms are thought to represent about 5-8% of all intracranial aneurysms and their treatment involves a careful consideration of all the anatomical features involved.

CASE REPORT

A 45-year-old male presented to our emergency room with headache. Magnetic resonance imaging of the brain and magnetic resonance angiography showed a left occipital lobe giant arteriovenous malformation (AVM) (Fig 1 and 2).

Figure 1

Figure 1: MRI of the brain showing giant AVM

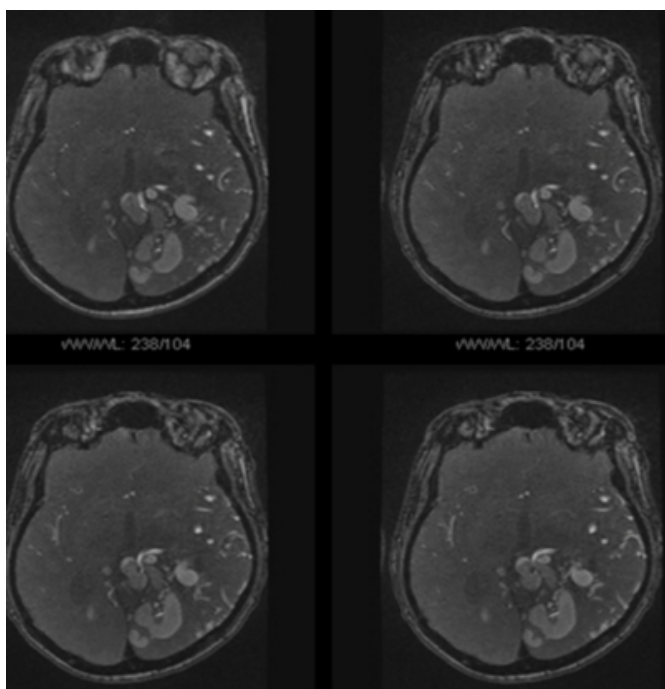
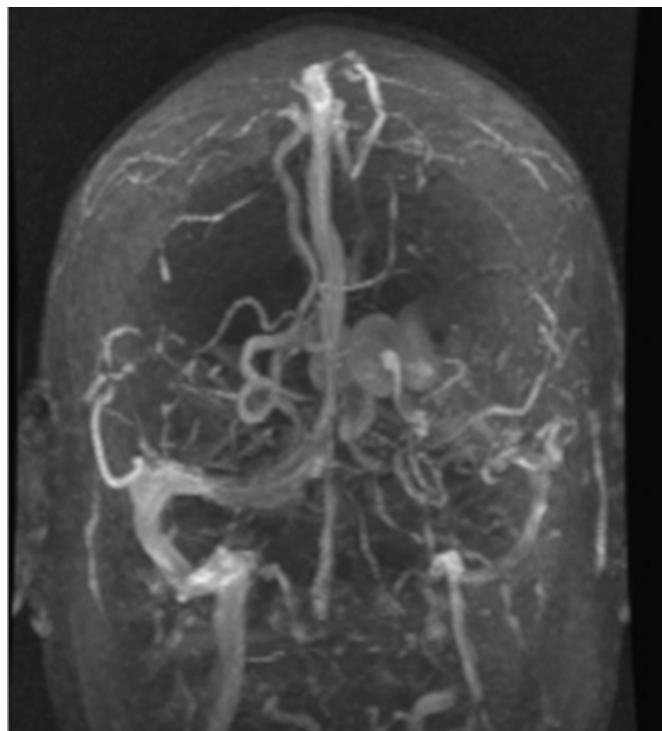


Figure 2

Figure 2: MRA of the brain showing giant AVM



DISCUSSION

Giant arteriovenous malformations are difficult to treat and often carry higher treatment morbidity and mortality rates than do smaller AVMs. Their presenting symptoms are hemorrhage, seizures, headaches and progressive neurological deficits. Treatment options include surgery, embolization (endovascular techniques), radiosurgery and a combination of the above approaches. The aneurysm can either be directly clipped or aneurysmorrhaphy with vessel reconstruction can be done. Other surgical techniques

include proximal occlusion and exclusion of the aneurysm from the circulation using clips above and below the lesion. Alternatively an extracranial to intracranial bypass procedure can be performed with subsequent trapping or proximal occlusion of the vessel. Endovascular techniques include balloon trapping with balloons placed intravascularly above and below the giant aneurysm. Coil embolization of giant aneurysms has been attempted often successfully. Most patients receive multimodality treatment with embolization followed by surgery, embolization followed by radiosurgery or embolization, radiosurgery, and surgery. Multimodality treatment is usually necessary to achieve complete AVM

obliteration. In our case it was decided to monitor the patient without treatment.

CORRESPONDENCE TO

N.K Sethi, M.D. Chief Resident, Neurology Saint Vincent's Hospital and Medical Center 153 West, 11th Street New York, NY 10011 Email: sethinitinmd@hotmail.com

References

1. Chang SD, Marcellus ML, Marks MP, Levy RP, Do HM, Steinberg GK. Multimodality treatment of giant intracranial arteriovenous malformations. *Neurosurgery*. 2003 Jul; 53(1):1-11; discussion 11-3.

Author Information

N. K. Sethi, M.D.

Department of Neurology, Saint Vincent's Hospital and Medical Centers

J. Torgovnick, M.D.

Department of Neurology, Saint Vincent's Hospital and Medical Centers

I. Omeis, M.D.

Department of Neurosurgery, Saint Vincent's Hospital and Medical Centers

S. Wright

Medical Student, New York Medical College

S. vanSwam

Medical Student, New York Medical College

E. Robilotti

Medical Student, New York Medical College