

# Protracted diarrhea associated with eosinophilia in an HIV infected patient

R Lin, L Lugo, F Smith

## Citation

R Lin, L Lugo, F Smith. *Protracted diarrhea associated with eosinophilia in an HIV infected patient*. The Internet Journal of Asthma, Allergy and Immunology. 2006 Volume 5 Number 2.

## Abstract

### INTRODUCTION

Eosinophils may accumulate in the colon in a variety of disorders, including eosinophilic gastroenteritis, allergic colitis of infancy, infections, drug reactions, vasculitis, and inflammatory bowel disease(1). We report the diagnostic difficulties involved in a HIV infected patient with prolonged diarrhea associated with eosinophilia. The role of therapeutic trials is also discussed.

### CASE REPORT

39 year old South American male with a history of AIDS presented to the hospital on 7/30/06 with a 1.5 year history of diarrhea. The patient reported watery diarrhea up to 5 liters a day and weight loss of 13 kg. He had been hospitalized in Ecuador for several months before coming to US. He had been told that he had celiac sprue and had been treated with a course of steroids with transient improvement. At the time of hospital admission the patient had been taking lopinavir/ritonavir, emtricitavine/tenofovir, trimethoprim-sulfamethoxazole(at doses for pneumocystis prophylaxis), azithromycin, and loperamide for 6 months.

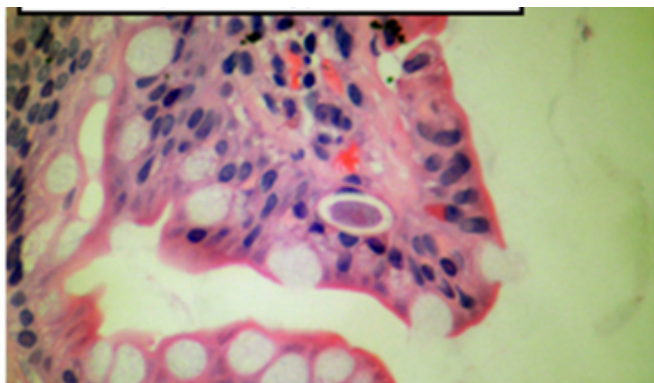
On admission the white blood count(WBC) was  $11.1 \times 10^3 /\mu\text{L}$  with 3% eosinophils. The prothrombin time was elevated at 15.2 sec(normal upper limit 14.6 sec). The AST was 120 u/L and the ALT was 123 u/L. The CD4 count was  $41 \times 10^3 /\mu\text{L}$ . The HIV-1 viral load was below the level of detectability. Stool studies did not reveal cryptosporidia, Clostridium difficile, Vibrio cholera, acid fast bacteria, or other parasites. Intravenous hydration was administered. Endoscopic biopsies of stomach and small intestine showed mild gastritis only. On 8/2/06 the WBC was  $8.8 \times 10^3 /\mu\text{L}$  with 9% eosinophils. On 8/7/06 colonoscopic biopsies of the colon and ileum revealed mild ileitis without sprue and mild increases in lamina propria mononuclear cells with edema in

the colon. Culture from colonoscopy showed a resistant E.coli. He was started empirically on cefipeme and metronidazole for one week without change in his symptoms. On 8/10/06 the WBC was  $3.4 \times 10^3 /\mu\text{L}$  with 12.5% eosinophils. A CT scan of abdomen showed diffuse mesenteric adenopathy. He was placed on nitazoxanide for 10 days without change in his symptoms. Because of the lack of improvement all antibiotics were stopped. On 8/29/06, the WBC was  $4.5 \times 10^3 /\mu\text{L}$  with 24.9% eosinophils. Skin prick tests and atopy patch tests for various foods were negative. Serological tests for scleroderma, and celiac sprue were negative. Histoplasma urine antigen was negative The ESR and C-reactive protein levels were normal. Levels of gastrin, secretin, and vasoactive intestinal peptide were normal. Ameba sp. and Strongyloides antibodies negative. On 9/13/06 the WBC was  $5.3 \times 10^3 /\mu\text{L}$  with 27.1% eosinophils. Octreotide was administered for three weeks with only transient improvement. On 9/26/06 the WBC was  $4.1 \times 10^3 /\mu\text{L}$  with 16% eosinophils. On 10/6/06 a laparotomy was performed and biopsies of the peritoneum, mesenteric lymph nodes, and small bowel were obtained. The small bowel showed increased eosinophils, plasma cells, and lymphocytes in the lamina propria with some blunting of the villous architecture without increase in intraepithelial lymphocytes. Cultures of the lymph node grew E. coli 0157. Viral cultures from small bowel negative. Methylprednisolone 40 mg every 12 hours was administered intravenously with only transient relief. On 10/13/06 when the patient was on corticosteroid therapy, the WBC was  $7.7 \times 10^3 /\mu\text{L}$  with 6.2% eosinophils. The corticosteroids were discontinued. The patient was treated with trimethoprim/sulfamethoxazole 160 mg/800 mg four times a day as well as nitazoxanide, and had gradual resolution of diarrhea during the first week of treatment. During this time,

a more detailed examination of the small bowel biopsy revealed *Isospora belli* macrogametocyte stage (figure 1) and other *Isospora* stages. Eight examinations of stool for ova and parasites during the hospitalization were negative. When the patient was close to discharge on 11/25/06 the WBC was  $5.6 \times 10^3 /\mu\text{L}$  with 9% eosinophils. The patient was discharged on oral trimethoprim/sulfamethoxazole.

### Figure 1

Figure 1: Small bowel mucosa with subnuclear parasitophorous vacuole containing macrogametocyte in surface epithelial cell (hematoxylin-eosin stain)



### DISCUSSION

Eosinophilia is associated with numerous disorders<sup>(1)</sup>, but most often relates to atopic diseases and hypersensitivity phenomenon. In the setting of HIV, eosinophilia may be associated with cutaneous disease such as eosinophilic folliculitis, hyper IgE syndrome, atopic dermatitis and prurigo nodularis<sup>(2,3)</sup>. In the absence of skin disease, eosinophilia in HIV infection may relate to other conditions such as parasitic infection and drug hypersensitivity.

The patient described in this report had *Isospora* infection as the cause of both his intestinal symptoms/signs as well as the hypereosinophilia. *Isospora* is a coccidian protozoa predominantly found in tropical and subtropical climates especially in South America, Africa and South East Asia<sup>(4)</sup>. In the United States, *Isospora* accounted for 2%-3% of AIDS-defining illness in the 1980's. In the late 1990's *Isospora* associated AIDS illnesses decreased to less than 0.1% probably due to the use of trimethoprim-sulfamethoxazole to prevent *Pneumocystis jirovecii*. In immunocompetent hosts, patients usually develop a self limiting diarrheal illness lasting 2 to three weeks characterized by malaise, abdominal cramps, and profuse watery diarrhea without blood. However, in the immunocompromised patient the infection may result in severe protracted diarrheal disease with subsequent

dehydration and malabsorption. *Isospora belli* is usually diagnosed by identification of oocysts in stool wet mounts or acid fast stained fecal smears from concentrates using flotation or sedimentation methods<sup>(4)</sup>. However, *I. belli* parasites are shed intermittently in low numbers, multiple stool examinations may be required. In this patient, the diagnosis was not established until repeated tissue samples were examined.

Gastrointestinal manifestations accompanied by eosinophilia raise the possibility of helminthic infection, most commonly *Strongyloides stercoralis*. In the patient described in this report, a therapeutic trial of nitazoxanide failed to improve the patient's condition. While other helminthic infections may cause eosinophilia, *Isospora* is the only significant protozoan infection that is associated with eosinophilia<sup>(1)</sup>. A therapeutic trial with *Isospora* doses of trimethoprim/sulfaxazole was considered in this patient after multiple anti-infective medications and corticosteroids had been unsuccessful. As *Isospora* has been reported to occur 10-14% of HIV/AIDS patients with diarrhea in Venezuela and Peru<sup>(5,6)</sup>, this approach seemed reasonable in this patient. However the time course to resolution was not rapid, and the key aspect of successful treatment was the identification of the organism.

This case demonstrates the diagnostic difficulties that may arise in HIV infection associated with diarrhea and eosinophilia.

### ACKNOWLEDGMENT

The authors acknowledge the assistance of Ann Nelson, MD and the Armed Forces Institute of Pathology.

### References

1. Rothenberg ME. Eosinophilic gastrointestinal disorders (EGID). *J Allergy Clin Immunol.* 113(1):11-28, 2004.
2. Paganelli R, Scala E, Mezzaroma I, Pinter E, D'Offizi G, Fanales-Belasio E, Rosso RM, Ansotegui JJ, Pandolfi F, Aiuti F. Immunologic aspects of hyperimmunoglobulinemia E-like syndrome in patients with AIDS. *J Allergy Clin Immunol.* 1995;95(5 Pt 1):995-1003.
3. Skiest DJ, Keiser P. Clinical significance of eosinophilia in HIV-infected individuals. *Am J Med.* 1997;102(5):449-53.
4. Fisk TL, Keystone JS, Kozarsky P. *Cyclospora cayentanensis, Isospora belli, Sarcocystis Species, Balantidium coli, and Blastocystis hominis* in Mandell, Douglas, and Bennett's Principles and Practices of Infectious Diseases 6th edition. 2005 Elsevier Churchill Livingstone Philadelphia Chapter 281.
5. Certad G, Arenas-Pinto A, Pocaterra L, Ferrara G, Castro J, Bello A, Nunez L. Isosporiasis in Venezuelan adults infected with human immunodeficiency virus: clinical characterization. *Am J Trop Med Hyg.* 2003;69(2):217-22.

6. Garcia C, Rodriguez E, Do N, Lopez de Castilla D,  
Terashima A, Gotuzzo E. [Intestinal parasitosis in patients

with HIV-AIDS] Rev Gastroenterol Peru.  
2006;26(1):21-4.(Spanish)

**Author Information**

**Robert Y. Lin, M.D.**

Department of Medicine, Saint Vincents Hospital, Manhattan, Saint Vincent Catholic Medical Centers

**Luz Amarilis Lugo**

Department of Medicine, Saint Vincents Hospital, Manhattan, Saint Vincent Catholic Medical Centers

**Fred B. Smith, M.D.**

Department of Pathology, Saint Vincents Hospital, Manhattan, Saint Vincent Catholic Medical Centers