

Anesthetic Management Of A Pregnant Patient Throughout The Emergent Craniotomy For Brain Tumour And Cesarian Section At The Same Session

N Baykan, A Gerçek, ? Do?an, ? Usseli

Citation

N Baykan, A Gerçek, ? Do?an, ? Usseli. *Anesthetic Management Of A Pregnant Patient Throughout The Emergent Craniotomy For Brain Tumour And Cesarian Section At The Same Session*. The Internet Journal of Anesthesiology. 2003 Volume 8 Number 1.

Abstract

A 29-year-old primipara woman in the 36th week of pregnancy was admitted to our Emergency Clinic with a complaint of severe headache for 3 months and nausea / vomiting since last week. A large frontoparietal intracranial tumour with peripheral edema was found at magnetic resonance imaging. Due to the high risk of herniation, she underwent an emergent craniotomy and cesarean section at the same session. Here, we presented the management of the patient throughout the perioperative period.

INTRODUCTION

During pregnancy, central nervous system disorders seldom require immediate surgical attention. These cases are usually vascular in nature such as subarachnoid haemorrhage related to congenital saccular aneurysm or cerebral arteriovenous malformation. Less frequently, the problem is a cerebral or spinal tumour.^{1,2} The decision to proceed neurosurgery depends on the site, size, type of the tumour, and neurological signs as well as the patient's wish.

Perioperative management of these patients can be complicated by the significant maternal physiological and physical changes that can occur during pregnancy, and is a challenge to anesthesiologist, obstetrician and neurosurgeon.¹

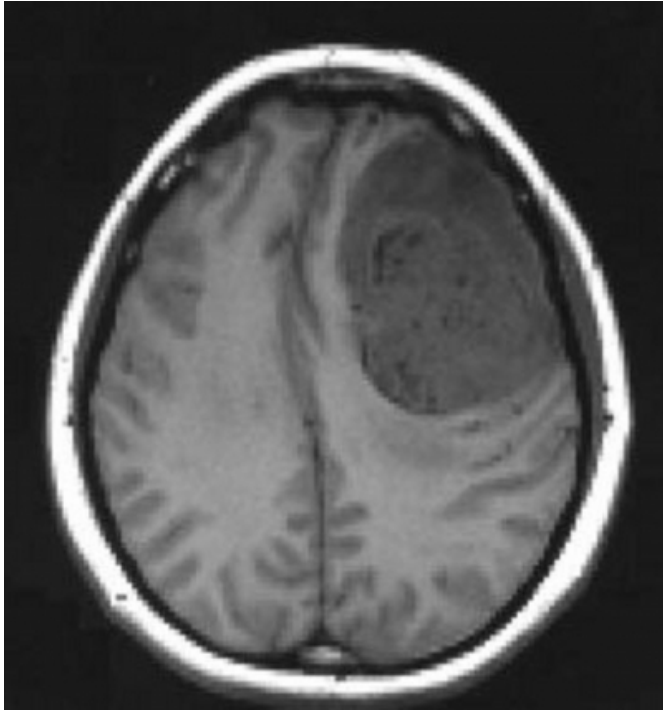
CASE REPORT

A 29-yr-old primipara woman (162 cm, 78 kg) at 36 weeks gestation was admitted to our Emergency Clinic with complaints of severe headache localized to the left frontal area of the head for 3 months and nausea / vomiting since last week. Her past medical history was unremarkable. With differential diagnosis of migraine, infection (meningitis, sinusitis, etc.), hemorrhage (as a result of aneurysm, hypertension, preeclampsia, HELLP syndrome, incidental) and any cause of increase in intracranial pressure she was internalized. As a result of physical examination mild apathia and bilateral grade 1 papiledema were detected.

Laboratory tests were at normal range. Cranial magnetic resonance imaging revealed a large intracranial mass (6x7 cm in diameter) with peripheral edema in left frontoparietal location, causing left-to-right midline shift (Fig 1).

Figure 1

Figure 1: Cranial magnetic resonance imaging revealed a large intracranial mass (6x7 cm in diameter) with peripheral edema in left frontoparietal location, causing left-to-right midline shift.



After a multidisciplinary consultation among the neurosurgeon, obstetrician and anesthesiologists it was decided that the patient was under the risk of cerebral herniation due to the large intracranial mass causing a midline shift at the dominant hemisphere. An emergent craniotomy had to be performed from the perspective of the neurosurgeons and neuroanesthesiologists. Fetal cardiotocography and ultrasoundography revealed that fetus was well and compatible with life after cesarean section. Obstetricians and anesthesiologists thought that there would be no problem about performing a cesarean section from the perspective of the fetus and a sectio was scheduled at the same session before the craniotomy.

The patient was premedicated with ranitidine 50 mg I.V. Anesthesia was induced with propofol 2 mg kg⁻¹ and remifentanyl 1 µg kg⁻¹ I.V. bolus dose. Lidocaine 1.5 mg kg⁻¹ and vecuronium bromide 0.15 mg kg⁻¹ I.V. were administered to facilitate intubation and to maintain muscle relaxation respectively. The trachea was intubated with a 7.5 mm inner diameter endotracheal tube at the first attempt without any difficulty. A left lateral tilt to decrease pressure to the inferior vena cava and 15 degrees reverse Trendelenburg to decrease intracranial pressure were applied to the operation

table. Anesthesia was maintained with 50 % air in O₂, 0.5 MAC sevoflurane and remifentanyl infusion 0.25 µg kg⁻¹ min⁻¹. Ventilation was controlled with a 8 mL kg⁻¹ tidal volume and a respiratory rate sufficient to maintain end tidal CO₂ at 30 ± 2 mmHg. Heart rate, invasive arterial blood pressure from the right radial artery, peripheral O₂ saturation, end tidal CO₂ values, central blood pressure from vena basilica and body core temperature were monitored throughout the anesthesia.

First, the obstetrician performed the cesarean section. After delivering a healthy girl neonate with APGAR score 7 and 10 at 1st and 5th min respectively, sefuroxime 1.5 g, oxytocin 5 units I.V bolus and 10 units in 500 ml 0.9 % NaCl infusion were started. Dexamethasone 0.1 mg kg⁻¹, mannitol infusion 0.5 mg kg⁻¹ and furosemid 0.1 mg kg⁻¹ IV were administered to the patient to decrease brain edema and ICP. A left frontotemporal craniotomy was performed. Appearance of the brain was Grade I (soft and pulsating, not protruding from the skull) according to the 4-point scale after the bony flap was removed and durotomy was done. The tumour was resected without any complication. Peroperative tumour sampling confirmed the diagnosis of an anaplastic oligodendrioglioma, grade III. Vital signs remained stable during operation. After bleeding control, phenytoin 1000 mg I.V. were administered as an anticonvulsant agent. Sevoflurane and remifentanyl infusion were stopped during stapling. Muscle relaxation was reversed with neostigmine 1.5 mg and atropine sulphate 0.5 mg I.V. The trachea was extubated 5 min from the end of the anesthesia when the patient responded to verbal stimulation. The patient's Glasgow Coma Scale was 15 and no neurological deficit was detected. The patient was admitted to the intensive care unit. Control CT revealed persistence of edema. After checking intestinal peristaltic the patient started to oral intake at postoperative day 1.

Vaginal bleeding was at normal range. Although being under the treatment of dexamethasone 4x4 mg, phenytoin 3x100 mg on the postoperative day 2 the patient had generalized convulsions controlled with diazepam. In the postictal period the patient did not show any neurological deficit. Edema at the frontal lobe and midline shift was seen in CT. Dexamethasone doses were increased and 50 mL %20 mannitol infusion six times a day were started.

At day 3, generalized convulsions were observed again. Electroencephalography did not show status epilepticus. Carbamazepine 200 mg three times a day was administered

and phenytoin and mannitol were decreased gradually and stopped. To prevent infantile side effects of the drugs via breast-feeding, lactation was stopped with bromocriptine and commercial formula was used for oral feeding.

After 5 day-follow up in the intensive care unit, the patient discharged on postoperative day 10 and attended to the follow up of Medical Oncology Department.

DISCUSSION

The incidence of brain tumours in female population is estimated as 3.4-6 per 100,000. But the prevalence of intracranial tumour in pregnancy is not known. Brain tumours tends to become larger during pregnancy due to fluid retention, increased blood volume and hormonal changes therefore they can be diagnosed earlier.¹

The decision to proceed neurosurgery during pregnancy depends on the site, size, type of tumour, and neurological signs, as well as the patient's wishes.^{4,5} As described here, a large brain tumour at the frontoparietal location with edema causing midline shift is an emergency due to the high risk of brain herniation.

As a result, anesthetists faced with this problem have to base their management on theoretical knowledge of obstetric and neurosurgical anesthesiology and of the effects of the physiological changes of pregnancy on the cerebral circulation.

General anesthesia remains safe and dependable for operative delivery in parturients with intracranial tumour. Tracheal intubation allows maternal hyperventilation thereby controlling raised intracranial pressure. But it must be kept in mind that endotracheal intubation can be difficult at the third trimester of the pregnancy due to edema and the structural changes at the oropharynx, neck, and mammarian glands.⁶ Also, increased abdominal pressure can push the diaphragm up, to perform endobronchial intubation is easier. During intubation, the risk of vomiting and aspiration is higher. Therefore patient should be premedicated with ranitidine 50 mg I.V like in this case. Although rapid sequence I.V. induction using succinylcholine has been advocated to in pregnant patients to reduce risk of aspiration; succinylcholine was avoided for the concern of increasing intracranial pressure. We used propofol 2 mg kg⁻¹, remifentanyl 1 µg kg⁻¹, lidocaine 1.5 mg kg⁻¹ and vecuronium bromide 0.15 mg kg⁻¹ I.V which rendered the intubation possible 120 sec after induction.

Nitrous oxide was avoided because it may worsen cerebral vasodilation when used with a potent inhalation agent. We used 0.5 MAC sevoflurane with 50 % air in O₂ and remifentanyl infusion at a rate of 0.25 µg kg⁻¹ min⁻¹. In recent studies, low-dose inhalational agents together with remifentanyl infusions (0.25-0.30 µg kg⁻¹ min⁻¹) proved to provide satisfactory hypnotic state without awareness.^{7,8} After delivery of the baby, the neurosurgeon proceeded to perform craniotomy at which time the concentration of sevoflurane was set between 0.5-1.0 MAC according to the hemodynamic variables and the tightness of the brain.

One issue in the present case was the use of opioids before the delivery of the baby. It can be argued that opioid should be withheld due to concerns of neonatal depression in the face of augmented stress response and increased intracranial pressure in the mother. Remifentanyl has a unique metabolism by plasma and tissue esterases and a context-sensitive half-life of 3 to 4 min, independent of the duration of infusion.⁹ The transfer of conventional opioids across the placenta may risk resultant neonatal depression. Despite of crossing the placenta, remifentanyl can be metabolized and redistributed to both mother and fetus rapidly.¹⁰ Data on the pharmacokinetics of remifentanyl in the neonate suggest a similar pattern of metabolism to older children and adults.^{11,12} Here, APGAR score was 7 at 1st min and 10 at 5th min following delivery, neonate was healthy and did not need any interventions due to the central system depression. Opioid properties of remifentanyl allow both control of the intraoperative stress response and a more rapid recovery than the other commonly used opioids. Because of its metabolism and short duration of action, remifentanyl can be considered to be safe and effective for general anesthesia for emergency cesarean sections in patients with neurological risk factors.¹³

Oxytocin has been used in patients with intracranial tumours without any adverse effects.³ On the other hand, ergotamine has been associated with hypertensive responses, which may increase intracranial cranial pressure more. Osmotic diuresis with mannitol is routinely used for decreasing brain bulk and intracranial pressure. It has been shown to cause fetal hypovolemia and electrolyte imbalance in both animal and human studies. However, there is no evidence that mannitol 0.5-1 g kg⁻¹ has any significant effect on fetal fluid balance.¹

Dexamethasone is used to decrease cerebral edema. Its acute use may be safe for fetus but chronic use of corticosteroids may result in fetal adrenal suppression and fetal hypoadrenalism particularly during the third trimester.³ It is

believed that the administration of high dose steroids for at least 24 to 48 hours would facilitate fetal lung development for premature delivery of the fetus. Treatment or prophylaxis with the anticonvulsants should be administered to all gravid patients presenting with intracranial mass and increased intracranial pressure who are apt to develop a seizure disorder. Deleterious effects from the anticonvulsants are infrequent.¹⁴ Maternal and fetal hypoxia and acidosis resulting from a seizure disorder may have more impact on fetus compared with the anticonvulsant use.

Here, main symptoms of increased intracranial pressure and cerebral edema were severe headache, nausea / vomiting and apathy. We must be careful at evaluating pregnant patients and although the incidence is very low, possibility of intracranial neoplasms must be kept in mind.

As a result, anesthetists faced with coincidence of intracranial neoplasm and pregnancy have to base their management on theoretical knowledge of obstetric and neurosurgical anesthesia and of the effects of the physiological changes of pregnancy on the cerebral circulation, ICP and the tumour. We would like to emphasize that the fetal and maternal well-being mainly depend on maintenance of hemodynamic stability and avoidance of aortacaval compression, hypoxemia and hypercarbia.

CORRESPONDENCE TO

Dr Arzu Gercek, M.D. Yaliboyu cad. Emanet sok. Emek apt.
No:2/28 Bostanci 81110 Istanbul, Turkey.
Tel:+905326417334 Fax:+902164453089
(email:agercek@hotmail.com)

References

1. Wlody DJ. Neurosurgery in the pregnant patient. In: Newfield P, Cottrell JE, eds. Handbook of neuroanesthesia. Philadelphia: WW Lippincott, 1999: 285-98.
2. Weir BK. Intracranial aneurisms and A-V malformations: Surgical Considerations. In: Albin SM. Textbook of neuroanesthesia with neurosurgical and neuroscience perspectives. New York: McGraw-Hill, 1997:845-59.
3. Todd MM, Warner DS, Sokoll MD, et al. A prospective, comparative trial of three anesthetics for elective supratentorial craniotomy. *Anesthesiology* 1993; 78:1005-20.
4. Chang L, Looi-Lyons L, Bartosik L, et al. Anesthesia for cesarian section in two patients with brain tumours. *Can J Anaesth* 1999;46:61-5.
5. Korula G, Farling P. Anesthetic management for a combined cesarean section and posterior fossa craniotomy. *J Neurosurg Anesthesiol* 1998;10:30-3.
6. Giannini A, Bricchi M. Posterior fossa surgery in the sitting position in a pregnant woman with a cerebellopontine angle meningioma. *Br J Anaesth* 1999;82:941-4.
7. Hung OR, Morris I. Dynamic anatomy of upper airway: an essential paradigm. *Can J Anaesth* 2000;47:295-8.
8. Larsen B, Seitz A, Larsen R. Recovery of cognitive function after remifentanyl-propofol anesthesia: A comparison with desflurane and sevoflurane anesthesia. *Anesth Analg* 2000;90:168-74.
9. Loop T, Priebe HJ. Recovery after anesthesia with remifentanyl combined with propofol, desflurane or sevoflurane for otorhinolaryngeal surgery. *Anesth Analg* 2000;91:123-129.
10. Michelson LG, Hugh CC Jr. The pharmacokinetics of remifentanyl. *J Clin Anesth* 1996;8:679-82.
11. Santos IL, Sanchez J, Rebosa MJ, et al. General anesthesia with remifentanyl in two cases of emergency cesarean section. *Rev Esp Anesthesiol Reanim* 2001;48:244-7.
12. Kan RE, Hughes SC, Rosen MA, et al. Intravenous remifentanyl: placental transfer, maternal and neonatal effects. *Anesthesiology* 1998;88:1467-74.
13. Ross AK, Davis PJ, Dear Gd GL, et al. Pharmacokinetics of remifentanyl in nanesthetized pediatrics undergoing elective surgery or diagnostic procedures. *Anesth Analg* 2001;93:1393-401.
14. McCarroll CP, Paxton LD, Elliott P, et al. Use of remifentanyl in a patient with peripartum cardiomyopathy requiring cesarean section. *Br J Anaesth* 2001;86:135-8.
15. Isla A, Alvarez F, Gonzalez A. Brain tumour and pregnancy. *Obst Gynecol* 1997;89:19-20.

Author Information

Nigar Baykan, M.D.

Associate Professor, Department of Anesthesiology and Reanimation, Institute of Neurological Science, Marmara University

Arzu Gerçek, M.D.

Instructor, Department of Anesthesiology and Reanimation, Institute of Neurological Science, Marmara University

?. Varlık Do?an, M.D.

Assistant Professor, Department of Anesthesiology and Reanimation, Faculty of Medicine, Marmara University

?mre Usseli, M.D.

Department of Neurosurgery, Acibadem Hospital