
Rarities Of The Stone Disease Of The Urinary Tract

A Hussain

Citation

A Hussain. *Rarities Of The Stone Disease Of The Urinary Tract*. The Internet Journal of Urology. 2005 Volume 3 Number 2.

Abstract

Here we present three cases of stone disease of the urinary tract. The aim is to demonstrate that we still have advanced stone pathology in our practice, in developing countries, and the way of dealing with such pathologies. The first one is a female patient of 63 years old had a very big left renal stone, she had a recurrent left loin pain for which she taken analgesia for long time. The second case was a male patient of 54 years old had three perineal fistula openings since one year. His X-Rays revealed impacted big urethral stone, with erosion of the urethral wall and multiple fistula formation. The last case is a female patient of 80 years old with a big vesical stones; she had incontinence recently for which she ask medical advice.

All three cases treated surgically by conventional approach with the use of prophylactic antibiotic. They run a very good postoperative course. Stone analysis revealed mixed stone. Conclusion: advanced urinary tract stone disease still existed in poor, developing countries that had shortage in medical service and defective health system. Conventional surgery is a safe, feasible in these patients.

CASE PRESENTATION

CASE ONE

A 63 years old female patient, living in rural village presented to our clinic complaining of recurrent left flank pain for which she had taken analgesia for long time, in the first visit the patient was subjected to the necessary investigations in form of:

General urine examination, blood urea and creatinine, blood sugar, ultrasound examination, KUB x-ray.

These investigations revealed a very big stone 5.5 X5.5 cm occupying the hugely dilated left renal pelvis, the cortical thickness of the affected kidney is good, and general renal function is normal. The IVU examination, which has been done in the next visit, revealed:

A very big stone occupying the dilated left renal pelvis and satisfactory excretion of the dye. The ureter, urinary bladder and other kidney are all normal.

The patient was prepared for surgery, and the left kidney was explored by classical left flank incision, extra renal pelvis found hugely dilated and contain a stone that resemble a ball of 5.5X5.5 cm. The stone retrieved after incision of the dilated pelvis and pyloplasty done, the patient run a very good postoperative course and discharged from hospital in

the 7th post operative day. Follow up IVU revealed a very good function of the left kidney. And well-reconstructed pelvis. follow up of 6 months was unremarkable.

Figure 1

Case (1) plain X-Ray

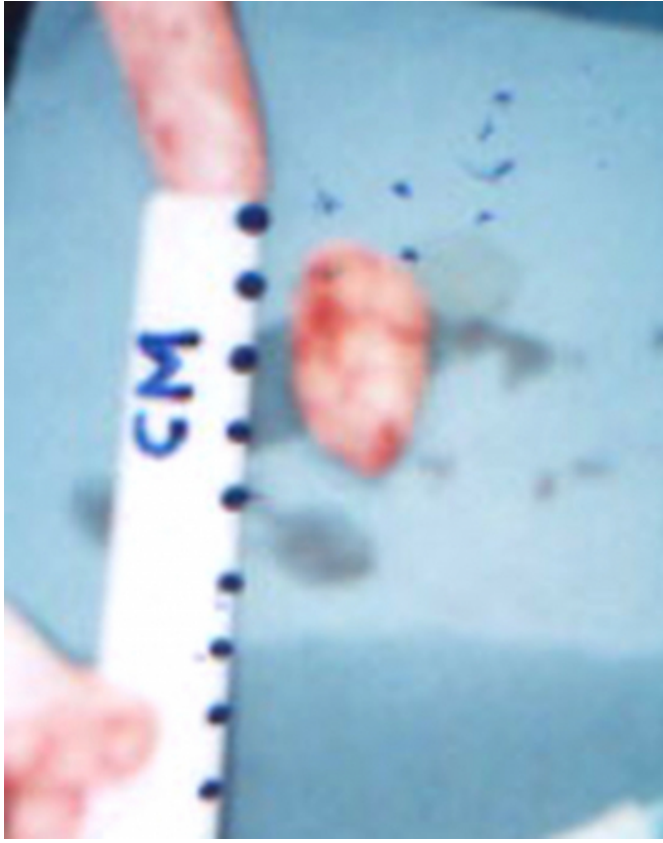


Figure 2

Case (1) urethral stone 3x2 cm

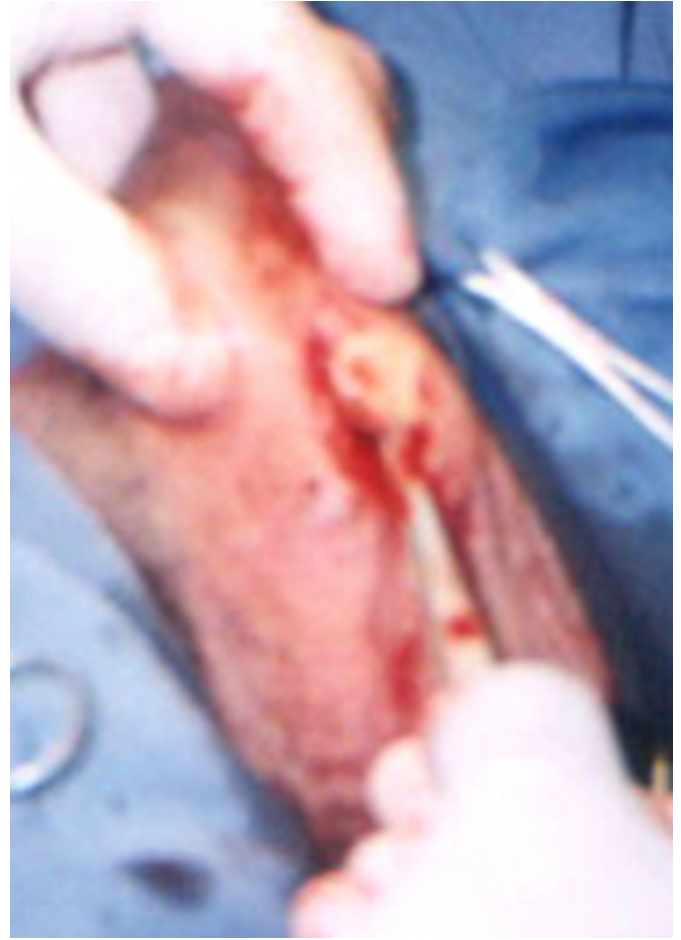

Figure 3

Case (1) extraction of urethral stone

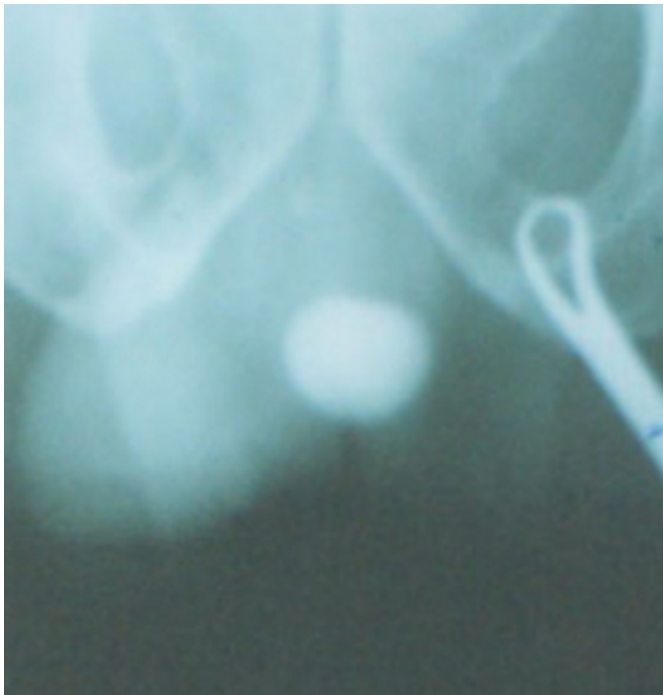
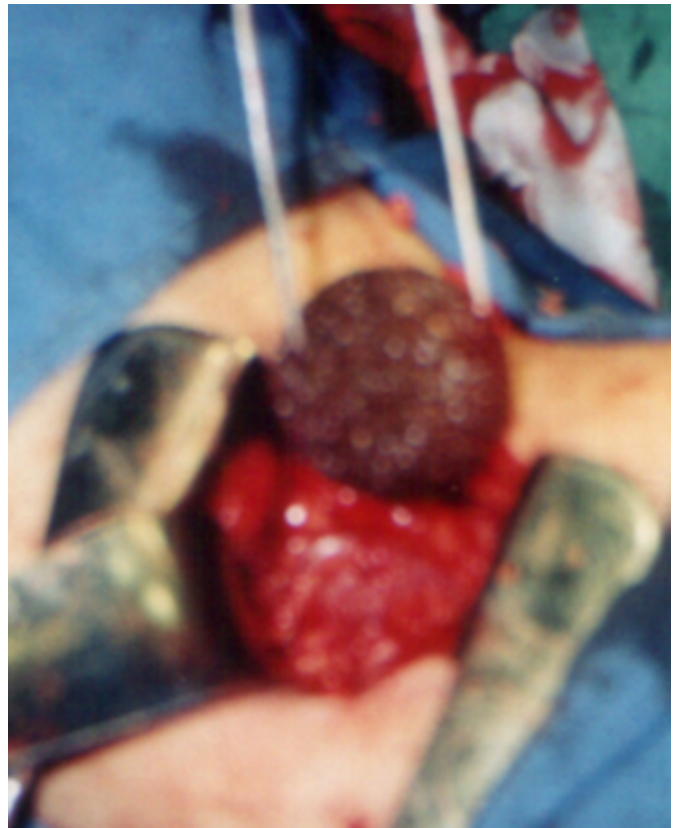
Figure 4

Case (2) left renal stone



CASE TWO

A 54 years old patient presented with a one year history of multiple openings in the perineum that all discharging, perineal pain, dysurea, poor stream and sometime dripping of urine. No previous history of urinary tract problem.

Examination revealed a three discharging perineal openings with a hard mass found between the root of the penis and the scrotum.the mass size about 1.5X3.5 cm tender and of limited mobility.

Investigations including ultrasonography and x-rays revealed an echogenic and calcified mass in the perineum.

Operative exploration done by perineal longitudinal incision through which the urethral stone of 1.5X3.5 cm retrieved and fistulectomy done for urethral fistulas and difficult reconstruction of the eroded penile urethra done by direct suturing over a 24 FR urethral catheter .the patient done well post operatively and discharged from the hospital in 7 th post operative day, 5 days later the urethral catheter was removed and the patient urinated normally with a good stream and the fistulas cured during a follow up period of one year

Figure 5

Case (2) IVU

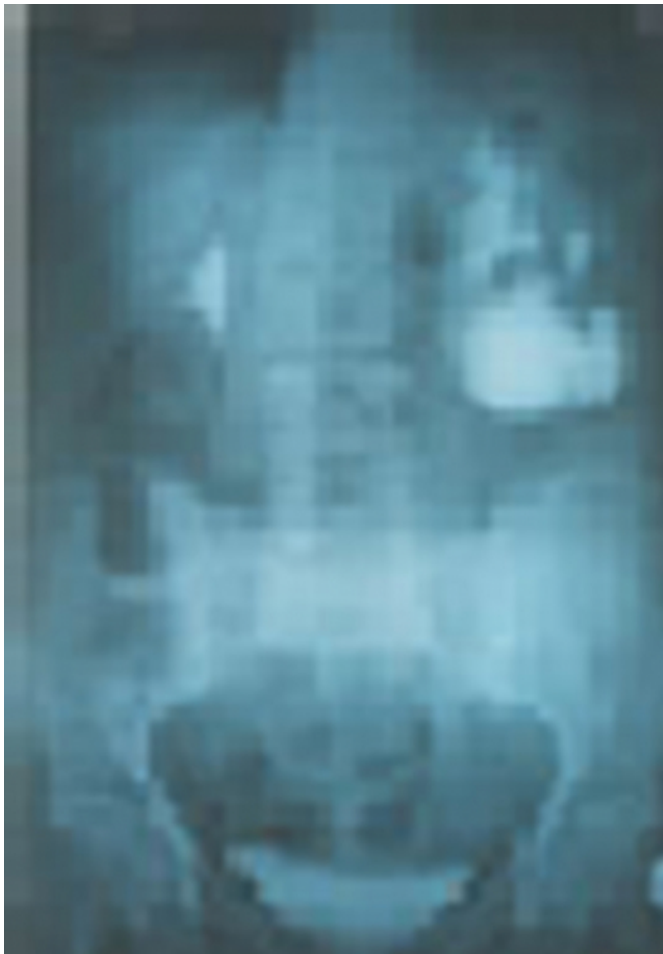
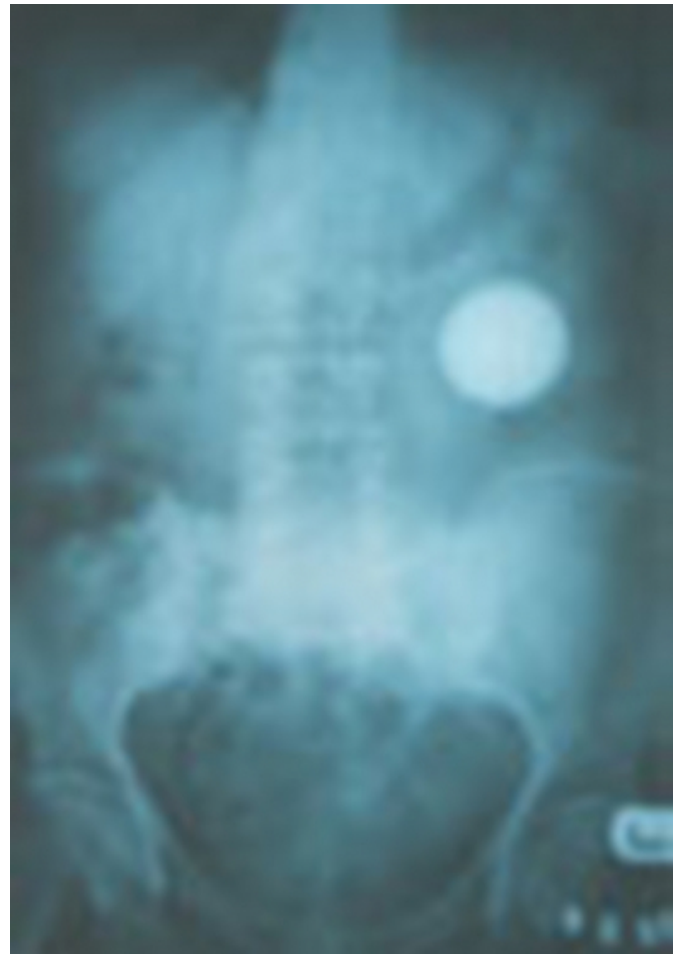
Figure 6

Case (2) Extracted pelvis with radio-opaque stone



CASE THREE

The last case was 80 years old female patient presented with only 14 days history of urinary incontinence, she had previous long history of dysurea frequency and suprapubic pain.

She had suprapubic tenderness, low-grade fever, and hypertension. Investigations revealed, leukocytosis with normal renal function. Ultrasonography showed three big vesical stones each about 3X3 cm. KUB confirmed the presence of three stones.

Cystoscopy done for her under epidural anesthesia also confirm the presence of the stones in the urinary bladder. On the same session immediate suprapubic incision of 4 cm length done and all stones removed, urinary catheter size 20 FR fixed and. the wound closed in layers .The patient discharged in the 3rd postoperative day, and the urinary catheter removed in the 8th postoperative day .The patient incontinence cured completely in 3 days following removal

of the catheter and the patient run a very good postoperative course, and follow up period of 6 months.

Figure 7

KUB showed radio-opaque stones through 4 cm pfeninstiel incision

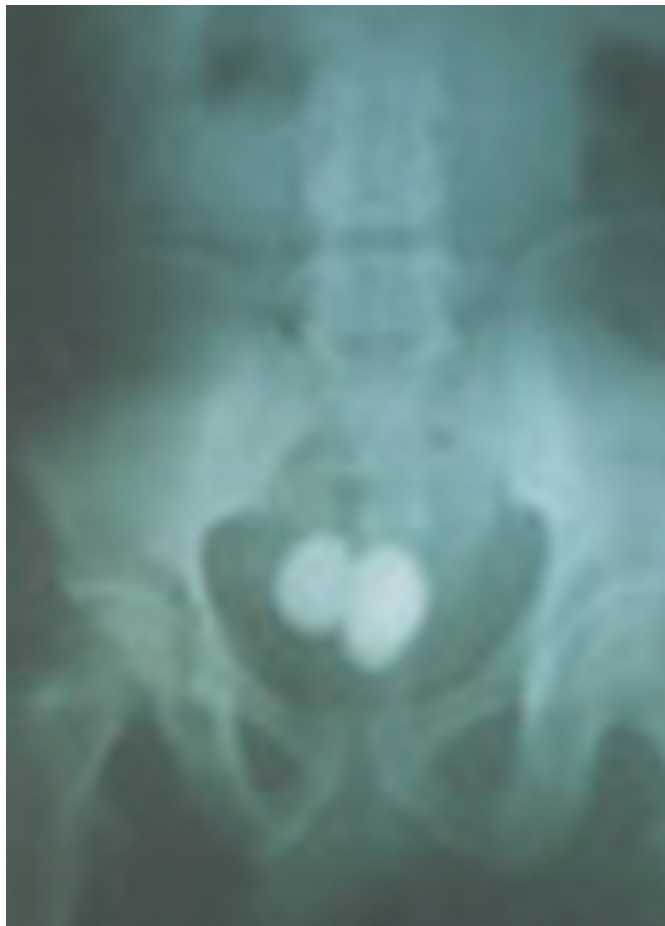
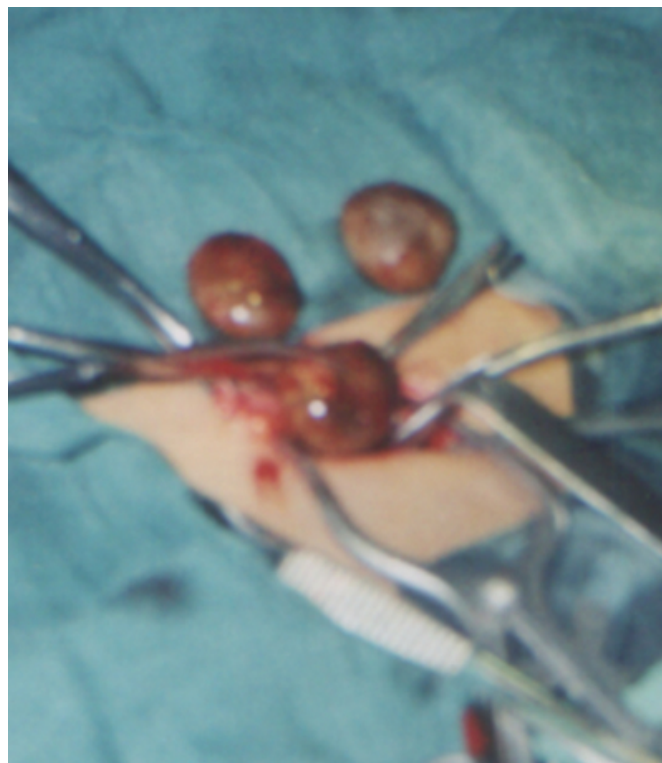

Figure 8

3 stones extracted from urinary bladder through suprapubic incision



DISCUSSION

Stone disease of the urinary tract is a common problem. Stone anywhere in the urinary tract (with the exception of the ureter and urethra) could be primary or secondary depending on the absence or presence of infection respectively. The risk factors for stone formation includes {1}:

1. hypercalciuria
2. hypocitraturia
3. high phosphate excretion
4. high urine PH
5. Low urine volume
6. hyperoxaluria
7. hypomagnesuria

Dietary factors associated with hypercalciuria include excessive animal protein, refined carbohydrate and sodium {8,9,10}

The presentation of these patients usually in form of pain

which is the leading symptom in 75% of people with urinary stone disease {₂}, frequency, haematuria, or could be a silent stone.

The majority of the patients do not need any diagnostic workup or specialist treatment, as most stone patients do not have complicated disease and after the first stone episode, only 25% recur within 10 years {_{3,4}}

The diagnosis is simple and no more than general urine examination KUB x-ray, ultrasonography and IVU were needed in majority of cases.

A plain abdominal film is most commonly used for the detection of calcification in the renal, ureteric, or bladder areas in patients with suspected stone disease. IVU is still remains an important and commonly used imaging examination of the urinary tract. Ultrasonography has become the most commonly performed examination for evaluation of the urinary tract {₅}

Unenhanced helical CT is advancement in the diagnostic ability. In 1995 UHCT was indicated as anew-diagnostic modality in the assessment of acute abdominal and pelvic pain including acute flank pain {₆}. It's of paramount importance in assessment of ureteric stones.

There are different methods used in the treatment of urinary tract stones. Excluding conservative treatment for small stones, these methods includes:

Percutaneous nephrolithotomy, extracorporeal shock wave lithotripsy (ESWL){₁₃}, endoscopic interventional urology {_{11,12}}, and open surgery.

In developed countries open surgery has a very limited indications as a treatment option. These indications includes {₇}:

1. difficult access to the stone because kidney malformation or obstruction and where partial nephrectomy is required.
2. To spare the patient the ordeal of multi-modal and multi-session stone removal, requiring repeated anesthesia.
3. failure of other treatment options.

In poor countries where access to modern equipments is limited, surgeons still used open surgery for treatment in majority of cases.

We present these three cases as a rare cases and the way it's used to treat.

The first case might be labeled as difficult stone disease to deal with by modern approach and can be included in the open surgery indications {₇}.

In the second case, there are three urethral fistulas secondary to the impaction and erosion of urethral stone through the bulbar urethral wall.

The common cause of the urethral fistula is bursting or incising a periurethral abscess.followed by trauma, urethroplasty, and urethral stricture. In our case the urethral fistulas developed secondary to spontaneous rupture of periurethral abscess that possibly formed after stone eroded the urethral wall.

The urine discharged through the fistula opening is clearly suggestive of. Urethrocystography and fistulagraphy will confirm the diagnosis. The treatment of the urethral fistula largely depend upon its etiology, in our case we removed the stone which was very large urethral stone (1.5X3) cm, excised the fistula openings and reconstructed the distorted urethra .We closed the urethral defect primarily after excising the excess fibrotic periurethral tissues that formed secondary to chronic inflammatory stimulus of the urethral stone.

Urinary catheter (24 FR) fixed for 12 days .The patient was very happy to urinate normally after removal of the catheter and 6 months after surgery.

LESSON LEARNED

Although there was rapid development in the treatment of urinary stone disease, open surgery is the safe and time effective method to retrieve such big stones.

CORRESPONDENCE TO

Mr Hussein Almusawy, Clinical Fellow, Urology
Department, London Royal Hospital Tel
0044-2082056678,Mob 0044-7949393892 Address:10
Brancker Road, Kenton,Harrow,NW9 0UE,UK Email
azahrahussain@yahoo.com

References

1. H.G.Tiselius, D.Ackermann, B.Hess, E.Boeve, *curric urol* (1-11) 41:5.2002
2. Charles V.Mann, R.C.G.Russell, N.S.Williams.*renal calculi. Bialy and Loves short practice of surgery, ch57, p925, 22nd Ed, 1995,Champan &Hall, and London*
3. Williams RE, Long term survey of 538patients with upper urinary tract stone disease .*Br J Urol* 1963; 35:416-37.

4. Hofbauer J, Hobarth K, Ludvik G, Marberger M, The stone clinic effect myth or reality? *Eur urolo.*1994; 26:309-13.
5. A.Cuschieri, G.R.Giles, A.R.Moossa, urological surgery in *Essential surgical practice*, 3rd ed 1995, Butterworth Hienemann, London 83:1465-1472,
6. Smith RC, Rosenfield AT, Choe KA, Essenmacher KR, Verga M, Glickman MG, Lange RC: Acute flank pain: Comparison of non-contrast-enhanced CT and intravenous urography, *Radiology*1995; 194:789-794.
7. X.Martin, D.Tolley, M.Galluci, P.Alken, *Curric Urol, Eur Urolo*; 40/1:1-9,2001
8. Houser M, Zemmermann B, Davidmann M, Smith C, Fish A, Idiopathic hypercalciuria associated with hyperreninemia and high urinary prostaglandin E, *Kidney Int*, 1984; 26:176-182
9. Pack CYC, Smith LH, Resnick MI, Weinerth JL, Dietary management of idiopathic calcium urolithiasis. *J Urol* 1984; 131:850-852.
10. Thom JA, Morris JE, Bishop A, and Blacklock NJ: The influence of refined carbohydrate in urinary calcium excretion. *Br J Urol* 1978; 50:459-464.
11. Brannen GE, Busch WH, Lewis GP, Caliceal calculi. *J Urol* 1986; 135:1142-1145
12. Esenberger F, Bub P, Schmidt A: The fate of residual fragments after extra-corporeal shock wave lithotripsy *J Endourol* 1992; 6:217-218
13. Hugh Whitfield, management of urinary stone disease, *surgery international*, 46; 185-89,1999

Author Information

Abdulzahra A. Hussain, FRCSI, FICS

Department Of General Surgery And Urology, Alburaihy Hospital