

# A Postpneumonectomy Patient With Iatrogenic Pneumothorax

B Adams

## Citation

B Adams. *A Postpneumonectomy Patient With Iatrogenic Pneumothorax*. The Internet Journal of Advanced Nursing Practice. 1999 Volume 4 Number 2.

## Abstract

Contralateral pneumothorax after pneumonectomy is a rare but potentially catastrophic complication. Described here is a pneumothorax in the left hemithorax of a postpneumonectomy patient occurring after internal jugular vein catheterization. Chest radiographs before and after chest tube thoracostomy are presented. Ramifications of diagnosis and management of this condition are discussed.

## INTRODUCTION

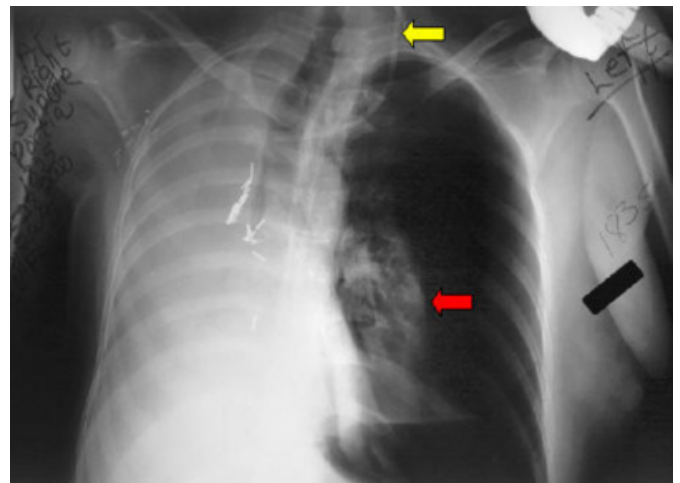
The development of a contralateral pneumothorax after pneumonectomy is a rare but potentially catastrophic complication. Almost all cases occur spontaneously and immediately after pneumonectomy.<sup>1,2</sup> Spontaneous postpneumonectomy contralateral pneumothorax has an incidence ranging from a 0.2 - 2%.<sup>1,3</sup> The mechanism probably results from occult intraoperative damage to the pleura or by rupture of preexisting bullae or blebs.<sup>1,2</sup> Interestingly, iatrogenic pneumothorax in this setting is not well reported in the medical literature. Below is a dramatic presentation of pneumothorax that occurred after left-sided internal jugular vein catheterization.

## CASE REPORT

A 49-year-old white female was 2 months status post right pneumonectomy for lung cancer. She underwent an outpatient left internal jugular vein catheterization in anticipation of chemotherapy. Placement was successfully confirmed by immediate post procedure chest x-ray and the patient was sent home. Approximately 4 hours later she developed sudden onset of dyspnea and chest pain. She arrived in the emergency department in severe respiratory distress and appeared cyanotic, diaphoretic and lethargic. Breath sounds were absent bilaterally. The patient's chest was dull to percussion on the right, and hyperresonant on the left. There was moderate right jugular vein distention (which was later discovered to be chronic since her pneumonectomy). Chest x-ray confirmed a near total left pneumothorax (see Fig 1).

## Figure 1

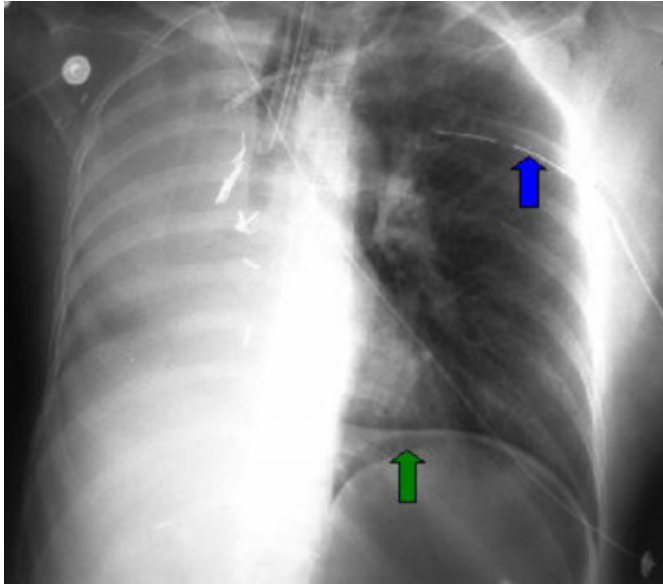
Figure 1: Large left sided iatrogenic pneumothorax (red arrow) and right sided postpneumonectomy space (PPS). Note also the left sided internal jugular catheter (yellow arrow).



Needle thoracostesis was unsuccessful for decompression. The patient was intubated and a 28 French Gauge (FG) chest tube was immediately placed in the left 4th intercostal space (see Fig 2).

### Figure 2

Figure 2: Inflation of the left lung after chest tube thoracostomy (blue arrow). The unusual appearance of the gastric bubble (green arrow) resolved on subsequent images and was not due to free intraperitoneal air



The patient was admitted to the intensive care unit and did well subsequently. She was discharged from the hospital 3 days later without residual deficit or complication.

### DISCUSSION

This appears to be the first reported central venous catheter insertion associated iatrogenic pneumothorax in a postpneumonectomy patient. Interestingly, iatrogenic pneumothorax occurs in approximately 6% of central venous catheterization attempts.<sup>4</sup> Previous contralateral pneumothorax reports described a spontaneous mechanism that was the cause of this complication in postpneumonectomy patients.

When a postpneumonectomy patient presents to the emergency department with sudden respiratory distress,

rapid diagnosis and management is critical. Possible causes include postpneumonectomy pulmonary edema, postpneumonectomy space hemorrhage or chylothorax, empyema, pneumonia, pulmonary embolism, tumor embolism, herniation of lung or heart, cardiac arrhythmias and myocardial infarction. Pneumothorax, either spontaneous or in this case iatrogenic, should also be considered, especially after central vein catheterization. The distorted anatomy of these patients hinders the rapid diagnosis of tension pneumothorax because tracheal deviation and contralateral hemithorax dullness to percussion are common findings on physical examination. When central line catheterization is required in these patients, site selection is problematic. In this case, catheterization ipsilateral to the remaining lung was almost fatal since this patient had little if any pulmonary reserve upon arrival. However, catheterization on the side of the postpneumonectomy space is also hazardous because of the distorted anatomy, and the serious consequences of introducing microorganisms into the PPS. Extended observation of postpneumonectomy patients after catheterization is advised.

### References

1. Kopec SE, Irwin RS, Umali-Torres CB, Balikian JP, Conlan AA. The postpneumonectomy state. *Chest*; 1998 Oct; 114(4): 1158-84
2. Hubbard JG, Nkere UU, Bhatnagar NK. Spontaneous contralateral pneumothorax following pneumonectomy. *Postgrad Med J* 1997; 73:107-08
3. Ikeda M, Uno A, Kamma K, Tanida T, Hagiwara N. [Bilateral simultaneous thoracotomy for unilateral spontaneous pneumothorax, with special reference to the operative indication considered from its contralateral occurrence rate]. [Japanese]. *Nippon Kyobu Geka Gakkai Zasshi - Journal of the Japanese Association for Thoracic Surgery*. 33(3):277-82, 1985 Mar.
4. Dronen SC, Younger JG. Central Venous Catheterization and Central Venous Pressure Monitoring In: Roberts JR, Hedges JR (eds). *Clinical Procedures in Emergency Medicine*, 3rd ed., Philadelphia: W. B. Saunders Company, 1998; pp 375.

**Author Information**

**Bruce Adams, MD**

Department of Emergency Medicine, Medical College of Georgia