

# Case series demonstrating the presence of protozoa in the sputum of a proportion of respiratory patients

H Woerden, C Gregory, R Martinez-Giron, M Burr, A Lansdown, I PMatthews

## Citation

H Woerden, C Gregory, R Martinez-Giron, M Burr, A Lansdown, I PMatthews. *Case series demonstrating the presence of protozoa in the sputum of a proportion of respiratory patients*. The Internet Journal of Laboratory Medicine. 2009 Volume 4 Number 1.

## Abstract

A Spanish study has demonstrated the presence of protozoa in the sputum of respiratory patients admitted to hospital with acute exacerbations of respiratory disease. These findings have not previously been replicated elsewhere in the world. Sputum was obtained from two case series of patients; firstly inpatients with an acute exacerbations of respiratory symptoms, and the other consisting mainly of chronic outpatients; both at Llandough Hospital, Cardiff, South Wales. Sputum, stained using the Papanicolaou method, was examined under a microscope using previously published criteria to determine the presence of protozoa. In the first series of ten inpatients, five patients (50%; 95% CI 24 – 76%) had protozoa in their sputum. In the second series of 17 generally less acute patients, one clearly had protozoa and two possibly had protozoa in their sputum. Protozoa may have an important pathogenic role in asthma which merits further examination.

## INTRODUCTION

The diagnosis of asthma is primarily based on clinical assessment rather than on definitive diagnostic tests [1]. It can be argued that asthmatic patients may include a cluster of aetiologies that produce a similar clinical pattern rather than a single disease process. This pilot study focuses on one factor that may have some relevance in a proportion of respiratory patients that have a diagnosis of asthma or COPD.

There is significant overlap in the symptoms of patients with asthma and COPD. A relevant history of smoking or occupational exposure, and spirometry can help to differentiate between the two conditions. Symptomatic improvement in response to a trial of beta-2 agonists is also a useful indicator of asthma. The aetiological distinction between asthma and COPD is further complicated by the fact that a proportion of patients have both conditions and there may be etiological factors that are common to both conditions.

Asthma appears to involve a complex interaction between environmental and genetic factors. A wide range of allergens have been identified, which can trigger respiratory symptoms in sensitized individuals. Acute viral infections are also recognized triggers in both asthma and COPD, as are exercise, hormonal changes and stress. In addition, in

some individuals, asthma and COPD are related to exposure to allergens or noxious factors that are present in the individual's occupational environment.

Infectious agents have also been proposed as having an etiological role in asthma. One of the most widely recognized hypotheses for the aetiology of asthma is the hygiene hypothesis [2] which was postulated to address the observation that children from larger families, who are presumably exposed to more infectious agents through their siblings, display less allergic symptoms than children from families with only one child. However, it is possible that infectious agents, including protozoa are more directly implicated in etiology of acute exacerbations of asthma and COPD.

This study is based on previous work exploring the role of protozoa in patients with respiratory symptoms. A number of small published studies of Spanish patients have explored the presence of protozoa in the sputum of respiratory patients admitted to hospital with acute exacerbations of disease [3,4] or patients who were immuno-compromised [5,6]. In one study [3], 15/19 patients (79%; 95% CI 35% – 92%) with asthma had protozoa in their sputum, as opposed to 9/78 patients (12%; 95% CI 6% – 21%) with other respiratory diseases, most usually COPD. The observed difference in prevalence (67%; 95% CI 43% - 81%) was

statistically significant.

The aim of this pilot study was to determine whether protozoa could be identified in similar respiratory patients in the UK.

**MATERIALS AND METHODS**

Two case series of patients had sputum collected several months apart. One case series was based mainly on inpatients and the other case series was based mainly on outpatients. The first case series comprised ten patients who were admitted to Llandough Hospital, Cardiff, South Wales, with an acute exacerbation of respiratory symptoms. The second case series comprised 17 patients, many of whom attended a COPD patient self help group, and who were generally less acutely ill than the patients in the first case series.

An information sheet was provided to all the patients involved in the study and written consent was obtained. A sterile sputum container was left with each patient. The sputum collected was transferred to two microscope slides. A small area of true sputum (not saliva), about the size of a large lentil, was taken from the expectoration using tweezers. The sample was placed on a microscope slide (frosted labeling area upwards) and, a second slide (frosted labeling area downwards) was used to make a smooth, uniform smear, gently moving both slides in opposite directions, and exerting slight pressure whilst gently holding the frosted labeled area of the slide between the thumb and forefinger. Both of the slides were immediately fixed using a commercially available hair lacquer, spraying the whole surface of each slide from a distance of approximately 30 cm for a few seconds. The slides were left face up to dry to make certain that none of the material seeped out at the edges. Every effort was made to ensure that the sample observed under the microscope consisted of sputum and not of saliva.

The microscope slides were stained using a modified Papanicolaou method [7] and the slides were scanned under the microscope to identify flagellated protozoa. Protozoa were differentiated from ciliated epithelial cell remnants using the criteria in Table 1, based on previously published work [4,3].

**Figure 1**

Table 1: Morphological basis for distinguishing between protozoal forms and ciliocytophthoria

Characteristic	Protozoal forms	Ciliocytophthoria (Ciliated epithelial cell remnants)
Red granules	Numerous, 3-8 µm, may be extracellular	Few, very small (1-2 µm), intracellular
Nuclei	Occasionally absent; if present, perinuclear clear halo, perinuclear corpuscles and prominent central kariosome	Usually absent; if present no perinuclear halo or perinuclear corpuscles, with tendency to picnosis
Cytoplasm	Friable with certain plasticity. Spindle or oval shape. Occasionally presence of cytoplasmic vacuoles	Round or columnar shape with fine granularity
Cilia or flagella	Wavy, not combed; different lengths	Cilia along 1 edge; straight, combed and same length. Discernible terminal bar
Cellular variability	Marked	Little variability
Papanicolaou stain	Eosinophilic	Amphophilic or basophilic
Ultraviolet light	Positive autofluorescence of all forms	Negative

When in doubt about distinguishing between protozoa and epithelial cell remnants, the following characteristics were particularly relied on during examination under oil immersion:

- Cytoplasmatic plasticity with ameboid-like forms
- Irregular insertion of numerous flagella around all the cellular border and absence of terminal bar
- Size about 12-20 microns
- Background with red granules (1-3 microns in diameter), and a characteristic eosinophylic material as a cloud

Quality assurance of the process involved: clear explanation to patients on how to produce a good-quality sample of sputum; rapid fixing of slides; a robust protocol for labeling of slides with unique patient identifiers; transport using approved containers for such samples; and assessment of sputum quality under the microscope based on the presence of macrophages in the smear.

Ethical approval for the study was obtained from the South East Wales Local Research Ethics Committee Panel C (Ref 05/WSE03/134) and informed consent was obtained in line with the Helsinki declaration.

**RESULTS**

In the first case series, protozoa were observed in the sputum

of five of the ten inpatients (50%; 95% CI 24 – 76%). All the patients in the sample had been admitted with an acute exacerbation of respiratory disease and were over 18 years of age. Other demographic details were not available for this case series.

In the second case series of 17 patients, mainly made up of outpatients, one case had protozoa and two had possible protozoa in their sputum. Some of the characteristics of this case series are given in Table 2.

Taking both case series together six of 27 patients (22%; 95% CI 11% - 41%) with respiratory disease had protozoal forms in their sputum.

**Figure 2**

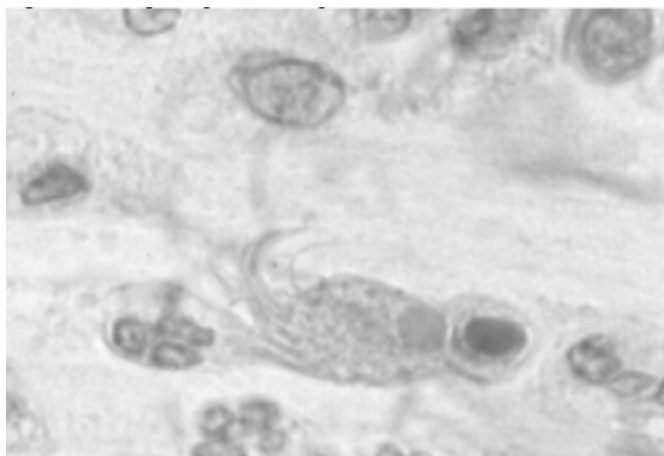
Table 2: Characteristics of the second case series of 17 respiratory patients tested for the presence of protozoa

Diagnosis	Gender	Age	Acute/Chronic	Duration of daily phlegm production	Protozoa seen
Bronchiectasis	F	65	Chronic	60 years	No
COPD/alpha anti-trypsin deficiency	M	55	Chronic	30 years	No
COPD	M	71	Chronic	7 years	No
COPD	M	78	Acute	1 to 2 weeks	No
Bronchiectasis	F	64	Chronic	2 years	No
COPD/asthma	M	78	Acute	1 week	No
COPD	M	69	Acute	5 weeks	No
COPD	M	73	Acute	1 week	No
Emphysema	M	49	Chronic	16 years	No
COPD	M	73	Chronic	12 months	No
Bronchiectasis	F	74	Chronic	2 years	No
Bronchiectasis	M	70	Chronic	40 years	No
Cystic Fibrosis (Bronchiectasis)	F	27	Chronic	5 years	No
Cystic Fibrosis	M	18	Chronic	50 years	No
Asthma	F	25	Chronic	Years	Possibly
COPD	F	83	Chronic	Years	Possibly
COPD	M	75	Chronic	2 years	Yes

An example of a protozoal form in sputum is shown in Figure 1.

**Figure 3**

Figure 1: Example of protozoa in sputum



**DISCUSSION**

This small pilot study provides some evidence that protozoa are present in a proportion of patients in the UK who have acute exacerbations of respiratory disease. This pilot study confirms previous observations regarding the presence of protozoa in the sputum of Spanish patients, but in case series in patients living in a more temperate climate. The higher rate of infection in inpatients than in outpatients may indicate that protozoal infection was in some way associated with acute exacerbations of disease.

It is unclear whether a single species of protozoa is being observed in all patients. It is also unclear whether these organisms are commensals or have any pathogenic significance whatsoever. Although the respiratory tract has historically been considered free from micro-organisms, in the absence of acute infection, there is some emerging evidence that organisms may be present in the respiratory tract without having a clear pathological role.

There is relatively little published literature on protozoa in the sputum of patients with asthma or COPD. A number of studies that have identified protozoa in the sputum of respiratory patients and infections related to protozoa have recently been reviewed [8]. Several studies have demonstrated chlamydia in the sputum of a proportion of patients with asthma [9,10] and a number of case reports from Chinese researchers have also identified protozoal organisms in patients with asthma [11,12].

Protozoa are often difficult to culture and previously reported attempts to culture the protozoa identified in sputum have been unsuccessful [3]. Culture of the protozoa would allow the examination of the effect of the protozoa on respiratory epithelial cell cultures. There is also the potential to undertake PCR amplification of 18S rDNA to determine whether the protozoa present in sputum is a known species, or is similar to a known species. Characterisation of the protozoa would allow us to determine whether the same species of protozoa is appearing in this diverse group of patients with respiratory symptoms. These techniques would allow the development of a rapid diagnostic technique to identify the presence of protozoa in sputum samples.

There is also a need for further work on the natural history of protozoa in the lungs, to determine whether the protozoa are present in patients over a prolonged period of time or only appear transiently. The relationship between acute exacerbations of respiratory illness, recovery from illness, and the presence or absence of protozoa in the respiratory

tract also needs to be determined.

If the protozoa can be cultured, their antibiotic sensitivity could be determined and a randomized control trial could be undertaken to determine whether clearance of the protozoa in symptomatic patients resulted in a more rapid recovery from an acute exacerbation of disease, or alternatively whether treatment of patients with chronic respiratory disease resulted in long term improvement in symptoms. Successful treatment of a very small number of individuals with metronidazole has suggested that this may be an appropriate antibiotic to test in a larger therapeutic trial, in individuals who have an acute exacerbation of asthma/COPD and where protozoa can be demonstrated in the sputum.

### **ACKNOWLEDGEMENTS**

We would like to thank the staff in Llandough Hospital, and Sharon Rolf, Cardiff School of Health Sciences, University of Wales Institute Cardiff, who assisted us with this pilot study.

### **References**

1. British Thoracic Society. British guideline on the management of asthma. *Thorax* 2003;58 (Suppl 1):S1-S92.
2. Strachan DP. Family size, infection and atopy: the first decade. *BMJ* 2000;55:S2-S10.
3. Ribas A, Mosquera JA. Ameboflagellates in bronchial asthma. *Acta cytol* 1998;42:685-690.
4. Ribas A, Jou C, Escobar J. Ciliocytophthoria and Ameboflagellates. *Acta cytol* 2003;47:705-708.
5. Ribas A, Martinez-Giron R, Sanchez-Del-Rio J, Gonzalez-Alonso D. Protozoal forms in the sputum of immunocompromized patients. *Scand J Infect Dis* 2005;37:205-210.
6. Ribas A, Martinez-Giron R, Ponte-Mittelbrum C, Alonso-Cuervo R, Iglesias-Llaca F. Immunosupression, flagellated protozoa in the human airways and metronidazole: observations on the state of the art. *Transpl Int* 2007;20:811-812.
7. Papanicolaou GN. A new procedure for staining vaginal smears. *Science* 1942;95:438-439.
8. Martinez-Giron R, Esteban JG, Ribas A, Doganci L. Protozoa in respiratory pathology: a review. *Eur Respir J* 2008;32:1354-1370.
9. Webley WC, Lay K, Stuart ES, Andrzejewski Jr C, Salva PS. Chronic respiratory disease in children: the prevalence of chlamydia and mycoplasma. *Chest* 2007;132:607b
10. Black PN. Antibiotics for the treatment of asthma. *Curr Opin in Pharmacol* 2007;7:266-271.
11. Zhou YP, Zhu XJ, Li M, Liu H, Chen YS. Clinical analysis of bronchopulmonary infection with hypermastigotes: a report of two cases and review of the Chinese literature. *Zhonghua jie he he hu xi za zhi* [Chinese journal of tuberculosis and respiratory diseases] 2006;29:23-25. (Article in Cinese)
12. Yao GZ, Zeng LQ, Zhang B, Chang ZS. Bronchopulmonary Lophomonas blattarum infection: two cases report and literature review. *Zhonghua nei ke za zhi* [Chinese journal of internal medicine] 2008;47:634-637. (Article in Chinese)

**Author Information**

**Hugo C van Woerden, FFPH**

Department of Primary Care and Public Health, Cardiff University

**Clive Gregory, PhD**

Department of Primary Care and Public Health, Cardiff University

**Rafael Martinez-Giron, PhD**

NCLINICA Foundation for Clinical, Pneumological and Carcinogenic Research

**Michael Burr, DSc**

Department of Primary Care and Public Health, Cardiff University

**Andrew Lansdown, MRCP**

Wrexham Maelor Hospital

**Ian PMatthews, PhD**

Department of Primary Care and Public Health, Cardiff University