

# Perforated Multiple Sigmoid Diverticulitis Presented Within 8 Hours Mimicking Acute Appendicitis

E Ergul, F Parlakyildiz, B Veli Ulger, I Sisman, B Korukluoglu

## Citation

E Ergul, F Parlakyildiz, B Veli Ulger, I Sisman, B Korukluoglu. *Perforated Multiple Sigmoid Diverticulitis Presented Within 8 Hours Mimicking Acute Appendicitis*. The Internet Journal of Surgery. 2006 Volume 11 Number 2.

## Abstract

We report a case of perforated multiple sigmoid diverticulitis presented within 8 hours with symptoms similar to those of acute appendicitis.

## INTRODUCTION

Diverticula arise at the points where the vessels enter the colonic wall between two equidistant longitudinal bands, a weak site where the mucosal layer herniates through the muscularis towards the serosa. Consequently, the diverticular wall does not contain a muscular layer.

Diverticula formation is related to a long-standing low-fiber diet associated with abnormalities in colonic motility and raised intraluminal pressure<sub>1</sub>.

Most frequently colonic diverticula are located distally on the sigmoid colon alone (26%) or involving both the sigmoid and descending colon (30%). However, sometimes they are scattered throughout the colon (16%) or are limited to the caecum and ascending colon (less than 5% of the cases)<sub>1</sub>.

Right-sided diverticulitis presents with symptoms similar to those of acute appendicitis. Thus, right-sided diverticulitis remains a diagnostic dilemma<sub>2</sub>. We report a case of perforated sigmoid diverticulitis mimicking acute appendicitis.

## CASE REPORT

A 63-year-old man presented with an 8 hour history of central abdominal pain which later localized to the right iliac fossa. There was neither significant past medical history nor an abdominal surgery.

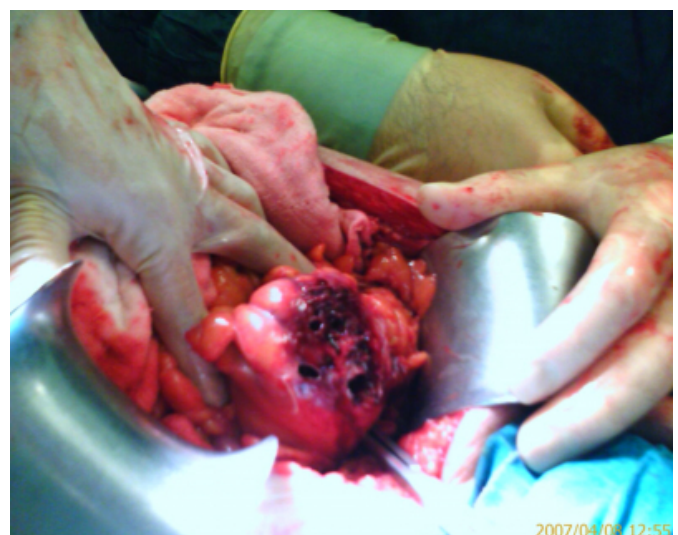
Clinical examination revealed a temperature of 38°C, with local peritonism in the right iliac fossa. The white blood cell count was  $18.3 \times 10^3/\mu\text{l}$  with 92.8% neutrophils. Electrolytes were normal, as were liver functions, lactate dehydrogenase and creatin phosphokinase. The abdominal plain roentgenogram was normal. As detecting free fluid in the

abdominal cavity at the abdominal ultrasonographic examination, an emergency operation planed.

During the operation, no free gas but nearly 100cc of pyoid fluid was found in the abdominal cavity and we observed multiple colonic diverticulas along the whole large bowel and a nearly 15 cm long area of multiple perforated sigmoid diverticulitis at the 50 cm proximal of the rectosigmoidal junction (Fig.1). Then the patient treated by the afflicted bowel segment resection and closure of the rectal stump (Hartmann's procedure).

## Figure 1

Figure 1: Multiple perforated sigmoid diverticulitis at the 50 cm proximal of the rectosigmoidal junction.



Pathology confirmed the diagnosis. The pathologist reported neither ulcerative colitis nor crohn disease. The patient has been discharged healthily at sixth day after the operation.

## **DISCUSSION**

Perforation is the most frequent complication of diverticular disease requiring surgical treatment. Because it is preceded by local inflammation, in most of the cases the perforated contents are walled off by adherent pericolic structures leading to a pericolic abscess. Free perforation occurs rarely and results in diffuse peritonitis, sepsis and shock<sup>3</sup>. At our case the clinical presentation prevented the septic progress.

Nowadays, in patients with complicated sigmoid diverticula the entire sigmoid colon must be removed and the anastomosis constructed between the descending colon and the rectum<sup>4</sup>. Alternatively, a two-stage procedure like Hartmann's resection or primary resection with anastomosis and proximal colostomy may be performed in selected cases, especially in patients with substantial fecal contamination and inflammation<sup>1,4</sup>. For instance, in cases with free diverticular perforation and generalized peritonitis Hartmann's resection is considered to be the procedure of choice<sup>4</sup>.

Right-sided diverticulitis presents with symptoms similar to those of acute appendicitis. However, at our case, perforated multiple sigmoid diverticulitis presented within 8 hours with symptoms similar to those of acute appendicitis.

## **CORRESPONDENCE TO**

Dr.Emre Ergul, M.D. dreergul@gmail.com Ankara Ataturk Teaching and Research Hospital, General Surgery Department Bilkent, 06800, Ankara / Turkey tel: +903122912525 fax: +903122123414 gsm:+905056821500

## **References**

1. Floch MH, Bina I. The natural history of diverticulitis: fact and theory. *J Clin Gastroenterol* 2004;38(5 Suppl);S2-7
2. Hildebrand P, Kropp M, Stellmacher F, et al. Surgery for right-sided colonic diverticulitis: results of a 10-year-observation period. *Langenbecks Arch Surg* 2007;392:143-7
3. Funari G, Bintintan V, Seicean R. Urgent surgery for complicated colonic diverticula. *J Gastrointest Liver Dis* 2006;15(1):37-40
4. Wong DW, Wexner SD, Lowry A, et al. Practice parameters for the treatment of sigmoid diverticulitis-supporting documentation. The Standards Task Force. The American Society of Colon and Rectal Surgeons. *Dis Colon Rectum* 2000;43:290-7

**Author Information**

**Emre Ergul, M.D.**

General Surgery Department, Ankara Ataturk Teaching and Research Hospital

**Funda Parlakyildiz, M.D.**

General Surgery Department, Ankara Ataturk Teaching and Research Hospital

**Burak Veli Ulger, M.D.**

General Surgery Department, Ankara Ataturk Teaching and Research Hospital

**Ibrahim Cagatay Sisman, M.D.**

General Surgery Department, Ankara Ataturk Teaching and Research Hospital

**Birol Korukluoglu, M.D.**

General Surgery Department, Ankara Ataturk Teaching and Research Hospital