

# Chronic Heart Failure As A Major Clinical Presentation Of Cardiac Non-Hodgkin's Lymphoma: A Case Report

C Zeng, C Liu, T Wei

## Citation

C Zeng, C Liu, T Wei. *Chronic Heart Failure As A Major Clinical Presentation Of Cardiac Non-Hodgkin's Lymphoma: A Case Report*. The Internet Journal of Cardiovascular Research. 2005 Volume 3 Number 2.

## Abstract

Cardiac lymphoma has various presentations and therefore it is likely to be misdiagnosed. Echocardiography remains a highly reliable imaging diagnostic tool, which allows excellent spatial imaging of cardiac structures. We report a case of cardiac non-Hodgkin's lymphoma with chronic heart failure as a major clinical presentation, which was misdiagnosed as atrial mural thrombus.

## INTRODUCTION

With an incidence of approximately 0.02 percent in autopsy series, primary tumors of the heart are far less common than metastatic tumors to the heart [1]. Often, cardiac tumors are misdiagnosed as other cardiac conditions due to the deficiency of specific clinical symptoms and signs. 2-dimensional echocardiography remains a highly reliable imaging diagnostic tool, and other measures remain complementary. We reported a case of cardiac non-Hodgkin's lymphoma with chronic heart failure as a major clinical presentation, which was misdiagnosed as atrial mural thrombus.

## CASE REPORT

A 24-year-old female who had a 2-year history of progressive dyspnea on exertion and fatigue was hospitalized. She described excessive fatigue and dyspnea with any activity greater than the activities of daily living; 2 month ago she experienced lower extremity edema. She denied paroxysmal nocturnal dyspnea, orthopnea, angina, and syncope.

Complete physical examination demonstrated a resting HR of 90 beats/min and a BP of 110/68 mm Hg, distention of jugular vein, pitting edema in both lower extremities, hepatomegaly, a soft mitral diastolic murmur and a loud tricuspid diastolic murmur. No lymphadenopathy was presented on palpitation.

An ECG showed normal sinus rhythm at a rate of 90 beats/min, normal axis. Laboratory data revealed that the

white blood cells count was  $7.2 \times 10^9/L$ , hemoglobin 122g/L, platelets  $273 \times 10^9/L$  and the differential count of white blood cells was neutrophils 63.5%, lymphocytes 28.8% and monocytes 8.3%. On serum biochemical analysis, blood urea nitrogen, creatinine, electrolyte levels, liver function, thyroid function and prothrombin time were normal.

A transthoracic echocardiogram revealed a 19x14mm low echo-level mass in left atrium and a 35x59mm low echo-level mass in right atrium protruding into inflow tract with a blur demarcation with interventricular septum and right ventricular free wall, normal biventricular function and no pericardial effusion. X-ray revealed a small quantity pleural fluid; abdominal ultrasonic inspection disclosed small amount of peritoneal fluid and wideness of inferior vena cava and hepatic vein. Thorax and abdomen computed tomography (CT) scan showed no lymphadenectasis and the size of spleen was normal. Bone marrow examination was with negative findings.

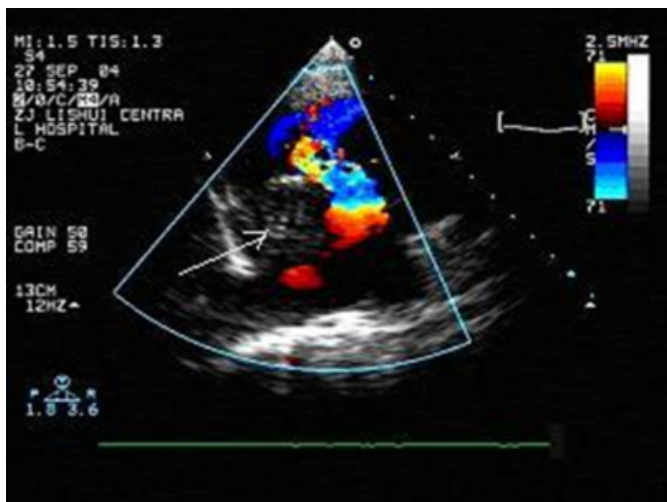
Diagnosis was made as atrial mural thrombus resulting in inflow tract obstruction. The patient was administered warfarin 3mg/d first and then adjusted dosage to maintain INR between 2.0-3.0. Hydrochlorothiazide was administered 25mg/d daily, and lower extremity edema was diminished but dyspnea was not attenuated.

Two months later, a 1x1.2cm tumor with slightly hardness, favorable mobility and slight haphalgesia was detected in the upper quadrant of left breast during physical examination. The tumor was removed and the histopathologic examination revealed non-Hodgkin lymphoma with B cell

type. After the CHOP (cyclophosphamide, doxorubicin, vincristin, prednisone) regimen plus Methotrexate as initial therapeutic modality for one course and then CHOP for another two course, her dyspnea and other signs of congestive heart failure were improved. Three months later, cardiac auscultation showed that the soft mitral diastolic murmur had disappeared and the tricuspid diastolic murmur softened. Another ultrasonic cardiogram showed the left atrial lump disappeared and the right atrial lump lessened to a size of 30x40mm, while still protruding to right ventricular inflow tract.

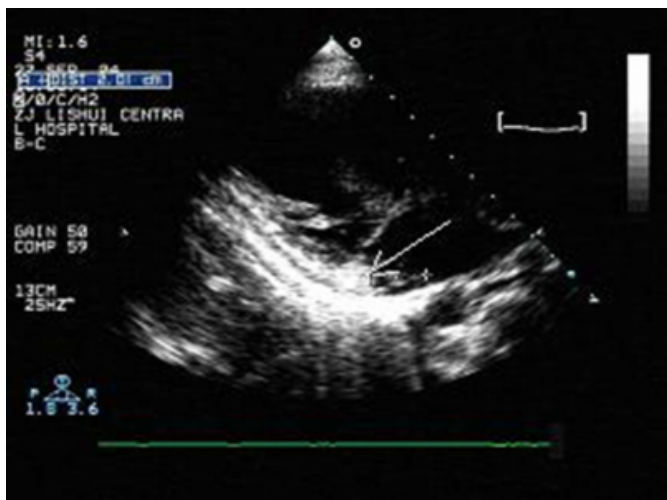
**Figure 1**

Figure 1: Echocardiography reveals a mass lesion over the right atrium, as indicated by the arrow.



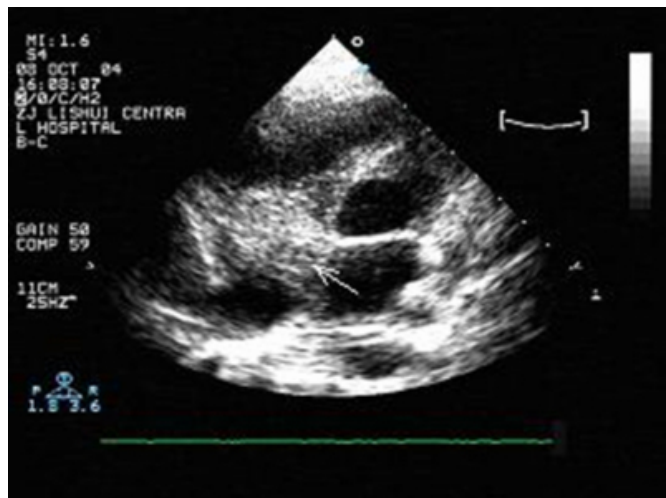
**Figure 2**

Figure 2: Echocardiography reveals a mass lesion over the left atrium, as indicated by the arrow.



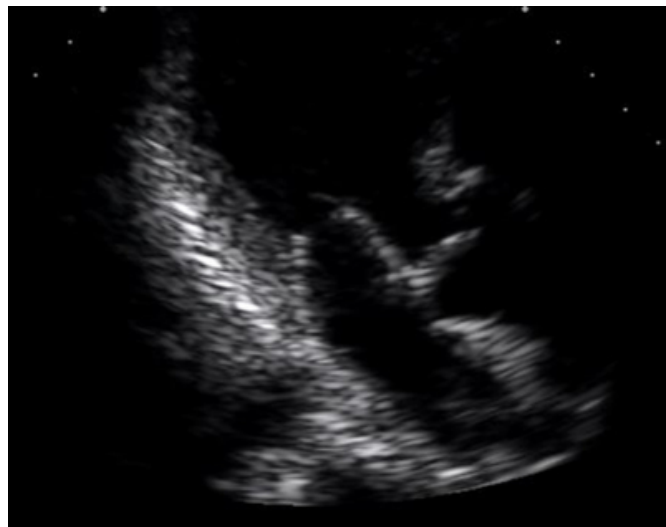
**Figure 3**

Figure 3: Echocardiography showing mass lesion lessened over the right atrium after completing chemotherapy.



**Figure 4**

Figure 4: Echocardiography showing no residual mass lesion over the left atrium after completing chemotherapy.



## DISCUSSION

Lymphoma occurs in all types of tissues and organs except nail and hair. Non-Hodgkin lymphoma often originated from multi-center and metastases to all over the body in the earlier period mostly by transvenous extension. Secondary lymphomatous involvement of the heart is much more common and has been reported as between 16% and 28% of extracardiac lymphomas. [2]

Primary cardiac lymphomas (PCL) compose a small fraction of primary cardiac malignancies. The definition of PCL has varied among studies. Some excluded cases with any

involvement outside the heart or pericardium whereas others have allowed variable amounts of tumor outside the heart to be classified as PCL [3]. In the present case, the patient had a comparable long history of heart failure without any findings of lymphoma except atrial mass. Left breast mass was detected in the later period of the disease, and atrial mass disappeared after chemotherapy, so we come to the conclusion that the patient had PCL. The patient's symptoms of heart failure and cardiac murmurs were very likely resulted from obstruction of ventricular inflowing tract.

The most common presenting symptoms of PCL are right-sided heart failure, precordial chest pain, pericardial effusion, superior vena cava syndrome, and arrhythmia. Pericardial effusion may be present in patients with or without pericardial tumor. Establishing the diagnosis of PCL is challenging since these symptoms are not specific and the time from onset of symptoms to diagnosis can be months or even years. Echocardiography, a widely used, safe, noninvasive test, remains as a highly reliable imaging diagnostic tool. Cardiac lymphoma displays a low-level echo lesion on echocardiography. CT and MRI imaging modalities provide a large field of view, which allows evaluation of disease throughout the thorax. Cytological analysis of pericardial fluid and transvenous endomyocardial biopsy sometimes is helpful [4]. On biopsy, cardiac lymphoma appears as a firm, white, infiltrative process, occasionally with nodular foci that range from 3 to 12 cm in diameter. These tumors are almost universally aggressive diffuse, large B-cell lymphomas [3].

The most effective therapy of PCL at present is chemotherapy and/or radiation with median survivals on the order of one year. The CHOP regimen is still considered the gold standard in first-line therapy [3].

## CONCLUSION

PCL has various presentations and therefore it can be misdiagnosed. Today, 2-dimensional echocardiography is a highly reliable imaging diagnostic tool, which can be used to document the progress of the tumor and assess the response to chemotherapy.

## CORRESPONDENCE TO

Chunlai Zeng, MD Department of Cardiology Lishui City Central Hospital Zhejiang PR China (310003) Email: zengchunlai@tom.com

## References

1. Reynen K. Frequency of primary tumors of the heart. *Am J Cardiol* 1996; 77:107.
2. Curtsinger CR, Wilson MJ, Yoneda K. Primary cardiac lymphoma. *Cancer* 1989; 64:521-525.
3. Ceresoli GL, Ferreri AJ, Eraldo B, Ripa C, Ponzoni M, Villa E. Primary cardiac lymphoma in immunocompetent patients: diagnostic and therapeutic management. *Cancer* 1997; 80:1497-1506
4. Chalabreysse L, Berger F, Loire R, et al: Primary cardiac lymphoma in immunocompetent patients: A report of three cases and review of the literature. *Virchows Arch* 2002; 441:456-461.
5. Messori A, Vaiani M, Trippoli S. Survival in patients with intermediate or high-grade non-Hodgkin's lymphoma: meta-analysis of randomized studies comparing third generation regimens with CHOP. *Br J Cancer* 2001; 84: 303-307.

**Author Information**

**Chunlai Zeng, M.D.**

Department of Cardiology, Lishui City Central Hospital

**Chong Liu, M.D.**

Department of Cardiology, Lishui City Central Hospital

**Tiemin Wei, M.D.**

Department of Cardiology, Lishui City Central Hospital