

# Radiological Quiz

G Bathla

## Citation

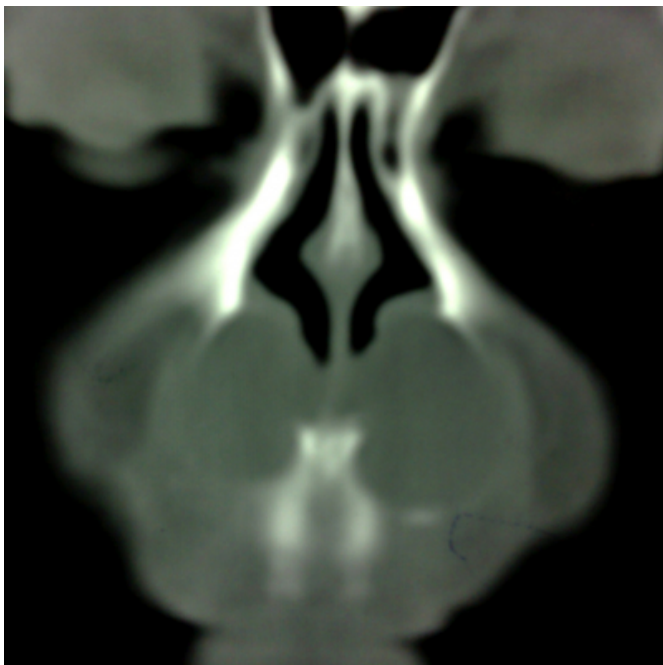
G Bathla. *Radiological Quiz*. The Internet Journal of Radiology. 2008 Volume 9 Number 2.

## Abstract

These are coronal (Fig 1) and axial (Fig 2) CT images. Give the diagnosis?

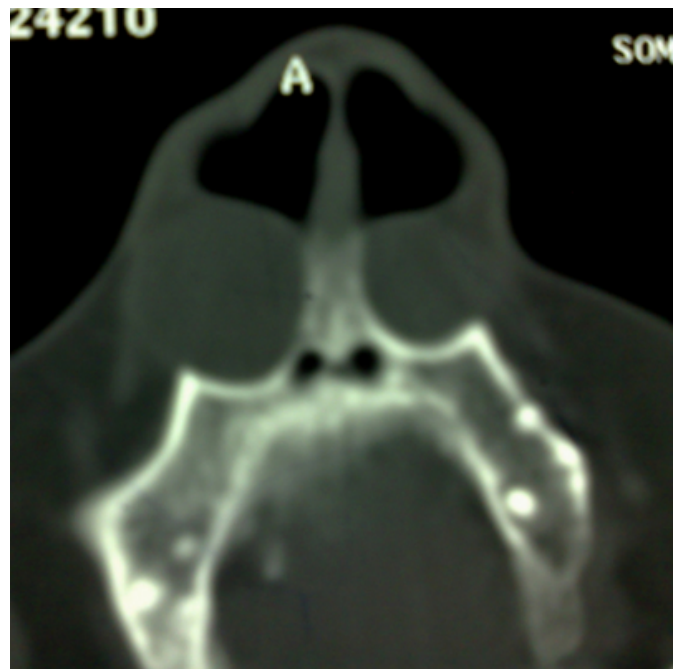## Figure 1

Figure 1



## Figure 2

Figure 2



## DISCUSSION

Nasolabial cysts are non odontogenic masses that arise in maxillofacial soft tissues.

A nasolabial cyst is the result of an ectodermal developmental swelling that manifests as a mass on the lateral half of the floor of the nasal vestibule at the base of the nasal ala. They are thought to arise from the remnants of the nasolacrimal ducts. Histologically, a nasolabial cyst is made up of an epithelium-lined cavity surrounded by a connective tissue wall. Pseudostratified columnar epithelium is the most common type of lining. Cysts lined with stratified squamous epithelium and simple cuboidal epitheliums have also been observed. Nasolabial cysts are rare with the reported incidence varying between 0.7% to less than 0.01%. Bilaterality has been reported in about 10% of patients. Computed tomography (CT) generally shows a

well-demarcated, low-density cystic lesion lateral to the pyriform aperture embedded beneath the soft tissue of the nasal ala. Invasion of the adjacent bone is not observed.

**References**

1. Choi JH, Cho JH, Kang HJ, Chae SW, Lee SH, Hwang SJ, et al. Nasolabial Cyst: A Retrospective Analysis of 18 Cases. *Ear Nose Throat J* 2002; 81: 94-96

**Author Information**

**Girish Bathla, MD**

MAM College and associated LN hospitals