

Easy Laryngoscopy “ Moustache blocking the view”

P Kumar, L Jayaraman, J Sood, G Kumar

Citation

P Kumar, L Jayaraman, J Sood, G Kumar. *Easy Laryngoscopy “ Moustache blocking the view”*. The Internet Journal of Anesthesiology. 2007 Volume 18 Number 1.

Abstract

A sixty year male patient presented to us for a laparoscopic hernia repair. Preanesthetic check up revealed that the patient had a moustache which was rolled up neatly above the lip and therefore no difficulty in securing the airway was anticipated .

A sixty year male patient presented to us for a laparoscopic hernia repair. Preanesthetic check up revealed that the patient had a moustache which was rolled up neatly above the lip and therefore no difficulty in securing the airway was anticipated .

After intravenous induction and successful mask ventilation, when the laryngoscope was inserted ,the laryngeal view was totally masked by the moustache which had accidentally opened up.(fig1)

An assistant was called, who retracted the moustache with his hand and then a repeat laryngoscopy revealed an easy glottic view.(fig2)

Figure 1

Figure 1

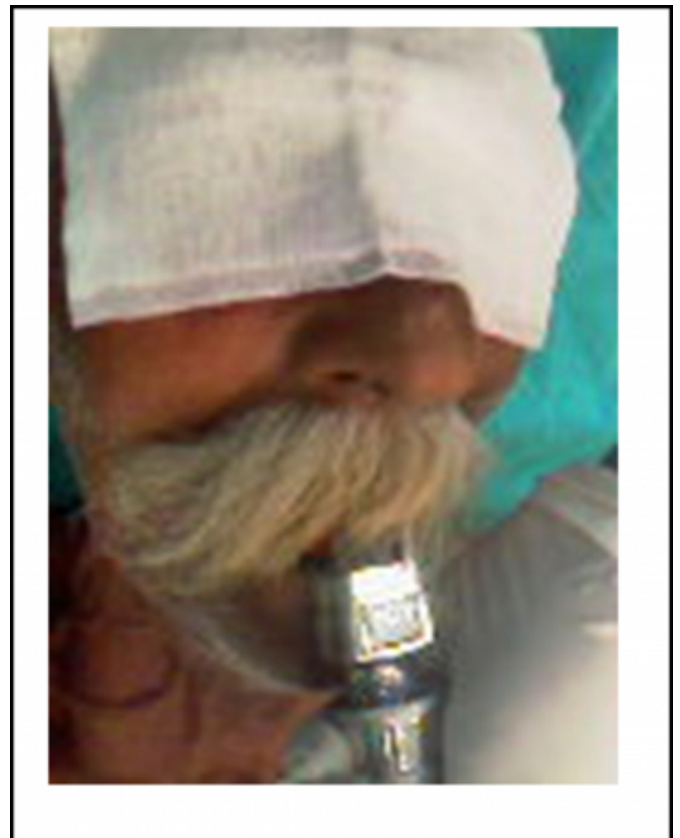
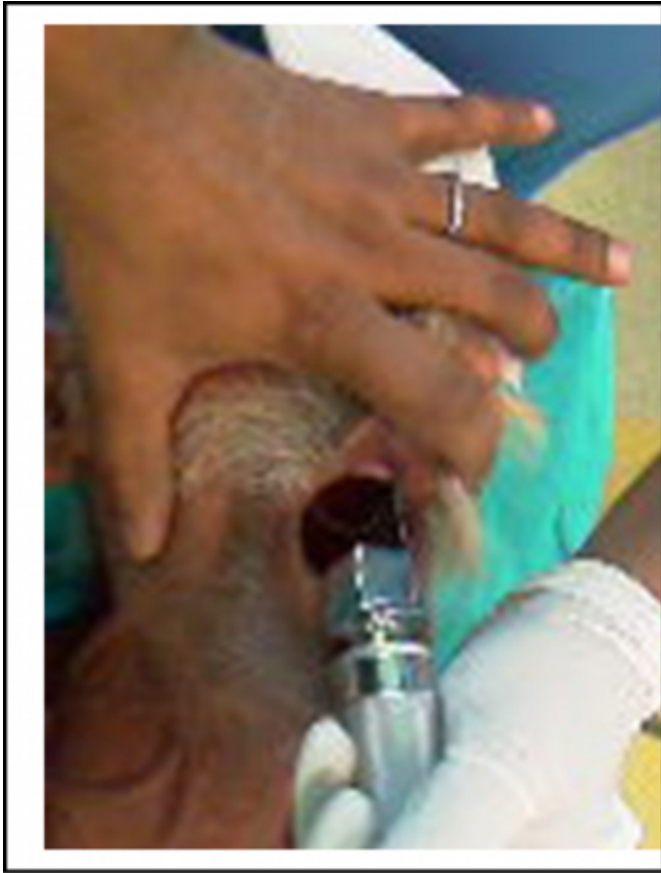

Figure 2

Figure 2



Greenberg₁ et al have suggested the use of a tape to secure the facial hair which however may cause waxing of the hair which cannot be done in our case due to religious sentiments in our country.

According to the LEMON classification of assessment of airway, L stands for look for beard/moustache. Although LEMON classification of airway was followed a difficult access to the airway was still encountered.

References

1. A patient with a large moustache complicating laryngoscopy: a simple solution Greenberg M., Benumof J.L, Walker L Journal of clinical anesthesia, Volume 14, Number 7, November 2002 , pp. 559-560(2)
2. Airway assessment- Predictors of difficult airway Sunanda gupta, Rajesh kumar KR Dimpel jain Indian journal of anesthesia 2005; 49(4) 257-262

Author Information

Prem Kumar, M.D.

Associate consultant

Lakshmi Jayaraman, D.A,D.N.B

Associate consultant

Jayashree Sood, M.D FFARCA, PGDHHM

Chairperson and Head of the Dept

Girish Kumar, MSc

OT Technician