

# Dysphagia following tablet ingestion: A Case Report Of Unusual Foreign Body

Rijuneeta, G Grover

## Citation

Rijuneeta, G Grover. *Dysphagia following tablet ingestion: A Case Report Of Unusual Foreign Body*. The Internet Journal of Otorhinolaryngology. 2007 Volume 7 Number 2.

## Abstract

A foreign body in the cricopharynx causes severe discomfort to the patient and is a potential threat to the airway. There have been case reports of some unusual foreign bodies like press through package which is commonly used as a package for drugs, fork, drug filled packets, medicine bottle cap and blister wrapped tablet. This is a unique case report because of the fact that the foreign body tablet was not wrapped; even then it got impacted and led to dysphagia and odynophagia.

## INTRODUCTION

Foreign body obstruction at the level of the cricopharynx is not an uncommon presentation in the accident and emergency department. A foreign body in the cricopharynx causes severe discomfort to the patient and is a potential threat to the airway. Its removal should be carried out as soon as possible since the pooled saliva can obstruct the airway <sup>1</sup>. Whether accidentally or intentionally, almost everyone living on this planet would have swallowed at least one foreign body in his lifetime <sup>2</sup>. Depending on their nature, foreign bodies may either have uneventful gastrointestinal transitions or be impacted in a particular segment of the gut <sup>2</sup>. The type of ingested foreign bodies commonly encountered varies from one society to another, each with their peculiar range of oral intruders determined by a host of cultural factors – psychosocial and dietary being the most important <sup>2</sup>. Esophageal foreign bodies are common in children and some specific groups of adults, such as prisoners or those with underlying esophageal disease, mental retardation and psychiatric illnesses <sup>3</sup>. We present here a rare foreign body lodged in cricopharynx. This was an ayurvedic tablet. which is commonly used in India for day to day health problems. Ayurveda or Ayurvedic medicine is an ancient system of health care that is native to the Indian subcontinent. It is presently in daily use by millions of people in India, Nepal, Sri Lanka. The word “Ayurveda” is a compound of the word ?yus meaning “life”, and the word veda, which refers to a system of “knowledge”. Thus “Ayurveda” roughly translates as the “knowledge of life”. In an extensive review of literature we did not come across any

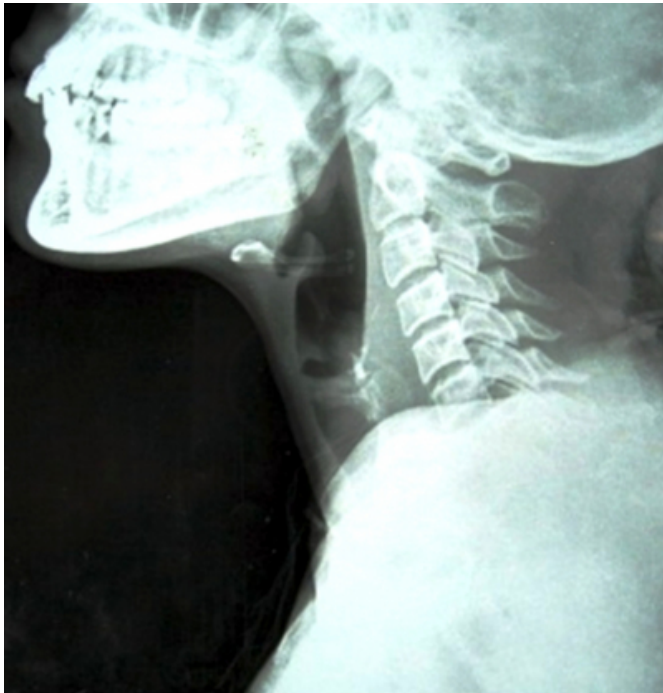such foreign body being reported in English literature. This is an effort to further our knowledge of the possibility of this rare foreign body and the specific problems in its management.

## CASE REPORT

A 20 year old female patient presented to our emergency with complaints of absolute dysphagia following ingestion of an ayurvedic tablet given by her mother in law for pain in abdomen. Just after ingestion of tablet the patient felt that the tablet had got stuck into her throat. The feeling of obstruction gradually increased so much so that she developed difficulty in deglutition followed by absolute dysphagia, and was unable to swallow even her saliva. Patient was immediately rushed to a local hospital, where flexible endoscopy was done and unsuccessful foreign body removal was attempted. The patient was then referred to our centre. By the time the patient came to us 8 hours had already passed and the patient had not taken anything per oral since then. The patient was in a state of distress and was having repeated feeling of vomiting out the foreign body but it did not come out. Indirect laryngoscopic examination revealed pooling of saliva in both pyriform sinuses. X ray lateral view neck revealed prevertebral widening in region of fifth and sixth cervical vertebrae ( figure 1).

**Figure 1**

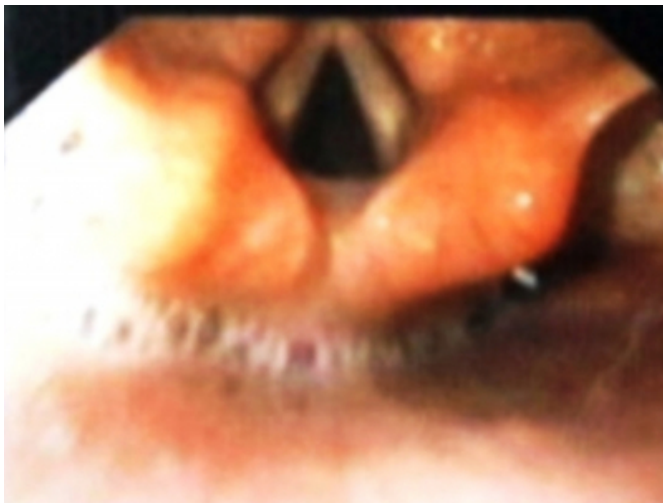Figure 1: X ray soft tissue neck lateral view showing widening of prevertebral space in front of 5 and 6 cervical vertebra.



Flexible endoscopy photographs revealed pooling of saliva in pyriform sinus ( figure 2).

**Figure 2**

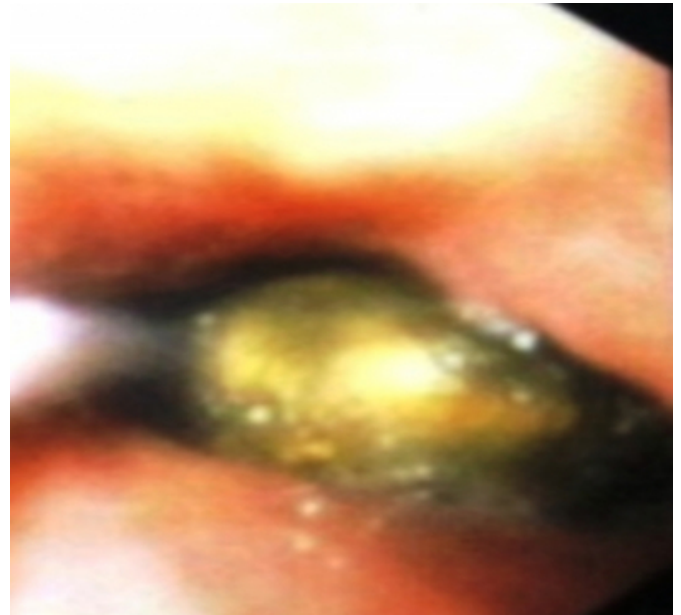
Figure 2 : Endoscopy photograph showing pooling in pyriform



Another picture revealed foreign body impacted in cricopharynx Figure 3.

**Figure 3**

Figure 3: Endoscopy photograph showing foreign body tablet impacted in cricopharynx causing complete obstruction of cricopharynx



Rigid hypopharyngoscopy was then done under general anesthesia and with the help of foreign body holding forcep, foreign body was removed. When initial attempts were made to take grip of foreign body the tablet broke and came out in pieces, finally as the size of tablet decreased it got disimpacted from the wall of cricopharynx and came out as one large piece approximately 2 cm in size (figure 4)

### Figure 4

Figure 4: Foreign body after removal measuring 2 cm in size.



The foreign body was swollen, due probably to hygroscopic action of some chemicals in the ayurvedic tablet. Post operative the patient had immediate relief of symptoms and the patient was able to take well orally.

### DISCUSSION

Foreign body ingestions or insertions are seen in four broad categories of patients: (a) children, (b) mentally handicapped or mentally retarded persons, (c) adults with unusual sexual behavior, and (d) "normal" adults or children with predisposing factors or injurious situational problems. Foreign body ingestions are common in children and mentally handicapped adults. Typical examples include children swallowing coins and mentally handicapped adults swallowing razor blades and silverware. Fortunately, the vast majority of all swallowed objects pass through the gastrointestinal tract without a problem<sup>4</sup>. Most upper GI foreign bodies are related to food impaction, with meat most often found. Underlying pathology is the rule and should be dealt with immediately<sup>5</sup>. Foreign body ingestion occurs most commonly in children; coins are the most frequently ingested item. Although college students playing the popular game, "quarters," may suffer a similar fate, most foreign body ingestions in adults are related to eating, leading to either bone or meat bolus impaction. Poor dentition, inadequate chewing, and eating while sedated can precipitate this problem<sup>5</sup>. If the FB lodges in the cricopharyngeal sphincter or esophagus, early endoscopic removal under

general anesthesia is performed. Patients treated in this manner had no morbidity and a short hospital stay<sup>6</sup>. There have been case reports of some unusual foreign bodies like press through package which is commonly used as a package for drugs<sup>7</sup>, fork<sup>3</sup>, drug filled packets<sup>4</sup>, medicine bottle cap<sup>2</sup> and blister wrapped tablet<sup>8</sup>. Our case was unique in having got a tablet getting stuck in cricopharynx, without any wrapper which led to absolute dysphagia. Although we commonly see people who after tablet ingestion complain of the tablet being stuck in throat, but so far we haven't come across any tablet getting impacted in cricopharynx. The most common presenting symptom is foreign body sensation in throat and dysphagia. The peculiar problem that we faced with this foreign body was that since it was tightly impacted in cricopharynx and was soft in texture it initially came out in pieces. Finally when it got disimpacted from the pharyngeal walls, it seemed that it might just slip from the forcep into the esophagus and then the stomach and could have served its original purpose, for which it was ingested; but we were successful in holding it with forcep and the foreign body was removed.

We conclude that rarely foreign bodies like tablet, can get impacted in cricopharynx especially ayurvedic tablets which are commonly used in Asian countries especially India. These tablets probably contain some hygroscopic substances which can make them swell and lead to impaction at cricopharynx and obstruction. This is an attempt to further our experience in managing such an unusual foreign body.

### CORRESPONDENCE TO

Dr Rijuneeta, Assistant Professor, Department Of Otorhinolaryngology and Head and Neck Surgery, PGIMER, Chandigarh – 160012 India. Phone no.: 91-172-2756760. Mobile no.: 09855157508. Email ID: rijuneeta@yahoo.com Fax no.: 91-172-2744401.

### References

1. Kumar A, Singh S, Low C, Shahab R: A safe and cost-effective method of removal of obstructed pharyngeal foreign body in the accident and emergency department. *Eur Arch Otorhinolaryngol* 262: 192-193, 2005.
2. Goh YN, Tan NG: Radiological features of unusual ingested foreign bodies. *Singapore Med J* 42 (3): 129-130, 2001.
3. Cangir AK, Tug T, Okten I: An unusual foreign body in the esophagus: report of a case. *Surg Today* 32: 523-524, 2002.
4. Hunter TB, Taljanovic MS: Foreign bodies. *Radiographics* 23: 731-757, 2003.
5. Conway WC, Sugawa C, Ono H, Lucas CE: Upper GI foreign body-
6. *Surg Endosc* 21: 455-460, 2007.
7. Selivanov V, Sheldon GF, Cello JP, Crass RA:

## ***Dysphagia following tablet ingestion: A Case Report Of Unusual Foreign Body***

---

Management of foreign body ingestion. *Ann Surg* 199 (2): 187-191, 1984.

8. Hou SK, Chern CH, How CK, Wang LM, Huang CI, Lee CH: Press through package misswallowing. *Int J Clin Pract*

60: 234-237, 2006.

9. Yip LW, Goh FS, Sim RS: I've got a UFO stuck in my throat--an interesting case of foreign body impaction in the oesophagus. *Singapore Med J* 39(3):121-3, 1998.

**Author Information**

**Rijuneeta, M.S (ENT)**

Assistant Professor, Department Of Otorhinolaryngology and Head and Neck Surgery, PGIMER

**Gogia Grover, M.S (ENT)**

Senior Resident, Department Of Otorhinolaryngology and Head and Neck Surgery, PGIMER