

Using Of The GIA 80 Reloadable Stapler In Tram Flaps

A Bogdanov-Berezovsky, D Orgill, Y Shoham, Y Krieger, E Silberstein

Citation

A Bogdanov-Berezovsky, D Orgill, Y Shoham, Y Krieger, E Silberstein. *Using Of The GIA 80 Reloadable Stapler In Tram Flaps*. The Internet Journal of Plastic Surgery. 2008 Volume 6 Number 2.

Abstract

Sir:

Breast reconstruction using the transverse rectus abdominis myocutaneous flap (TRAM) has been a popular option since its introduction in 1982 [1]. This flap is commonly performed as a pedicled flap based on the superior epigastric system or as a free flap based on the inferior epigastric system.

During the dissection of the rectus abdominis muscle, either the upper and/or lower portion of the muscle needs to be divided.

Often, the rectus muscle is divided by cautery or knife with suture. This can either result in bleeding or significant movement by the muscle during division.

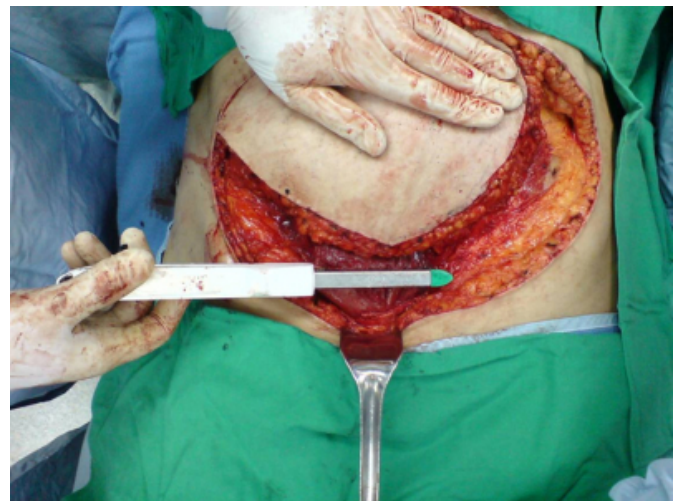We apply a simple technique to prevent such a complication by using a stapler device for cutting and controlling bleeding in the rectus muscle. We have found only two publications about dividing of the rectus abdominis muscle by stapler device [2, 3].

This technique has not been reported for use in breast reconstruction.

Since 2004 we use Reloadable Stapler GIA 80 (Auto Suture™, United States Surgical, Tyco Health Care Group) with 4.8 mm staples for cutting and suturing of the caudal part of the rectus abdominis muscle. After incision of anterior rectal sheath from both sites above the rectus abdominis muscle we separate the muscle from the posterior rectal sheath in its inferior portion. We apply an anvil fork of the GIA 80 under the muscle; apply a cartridge fork of the device and cut the muscle (fig. 1).

Figure 1

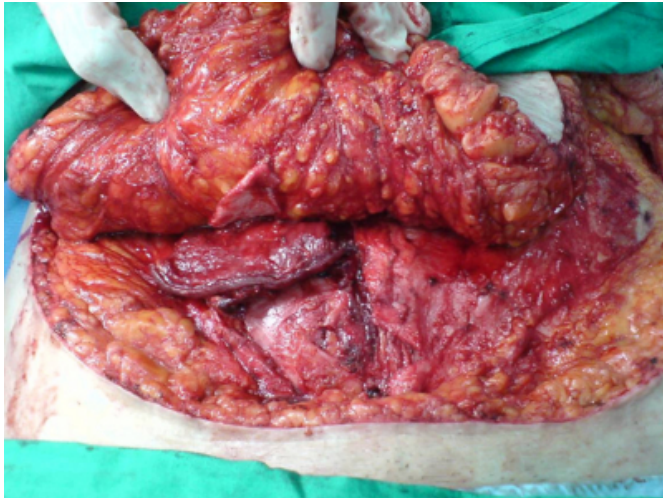Figure 1. The stapler device GIA 80 has been applied on the caudal portion of transverse rectus abdominis muscle



Additional staple cartridges can be used in case of athletic subjects with muscle wider than cartridge and anvil forks. As a result we get an even edge of the muscle sutured by metallic staples without bleeding (fig. 2).

Figure 2

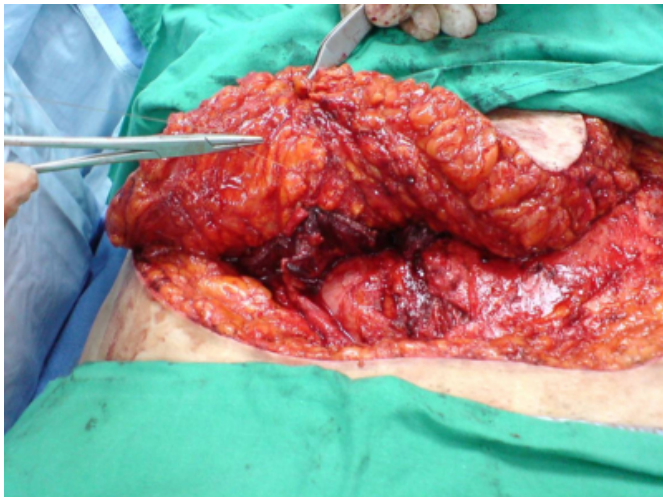
Figure 2. The transverse rectus abdominis muscle has been cut and sutured by metallic staples with no bleeding.



Later on, monofilament monocryl 3/0 stitches (Ethicon Inc, a Johnson-Johnson company) are applied between the caudal and lateral borders of the muscle, anterior rectal sheath and subcutaneous tissue to secure the flap (fig. 3).

Figure 3

Figure 3. The caudal portion of the rectus abdominis muscle has been sutured to the anterior rectal sheath and subcutis for flap securing.



After division with the stapler, the TRAM flap is raised by standard manner and transferred through the subcutaneous tunnel to the mastectomy site for inseting.

This technique has several advantages:

The using of the stapler device is fast and simple.

Perfect hemostasis is really achieved with no thermal damage to the muscle caused by electrocautery.

Monofilament stitches securing the flap, do not cut the muscle edge due to their passage behind the metallic staples line.

The TRAM flap upper rotation and transfer through the narrow subcutaneous tunnel is more secure than traditional techniques.

We have used this technique for 45 consecutive breast reconstructions and found this maneuver has been very useful and secure.

We recommend surgeons consider using GIA 80 stapler device for dividing the rectus abdominis muscle in TRAM flap breast reconstruction. This technique also has been used for raising vertical rectus abdominis muscle flap (VRAM flap) and can be applied for other types of muscle flaps.

References

1. Hartrampf CR, Schefflan M, Black PW. Breast reconstruction with a transverse abdominal island flap. *Plast Reconstr Surg.* 1982; 69:216-225.
2. Moss G. Transection of rectus abdominis: rapid hemostasis with automatic stapler. *Surgery* 1972; 71(2): 246.
3. Pu LLQ, O'Connell JB, Takei T et al. Closure of infected sternal wounds with a unilateral rectus abdominis muscle flap in addition to bilateral pectoralis major myocutaneous advancement flaps. *Eur J Plast Surg.* 1999, 22: 313-317.

Author Information

Alexander Bogdanov-Berezovsky, MD, PhD

Department of Plastic and Reconstructive Surgery and Burn Unit, Soroka University Medical Center, Beer-Sheba, Israel

Dennis Orgill, MD, PhD

Division of Plastic Surgery, Brigham and Women's Hospital, Harvard Medical School, USA

Yaron Shoham, MD

Department of Plastic and Reconstructive Surgery and Burn Unit, Soroka University Medical Center, Beer-Sheba, Israel

Yuval Krieger, MD

Department of Plastic and Reconstructive Surgery and Burn Unit, Soroka University Medical Center, Beer-Sheba, Israel

Eldad Silberstein, MD

Department of Plastic and Reconstructive Surgery and Burn Unit, Soroka University Medical Center, Beer-Sheba, Israel