

# Giant Abdominal Liposarcoma: A Case Report

A Ciraldo, D Thomas, S Schmidt

## Citation

A Ciraldo, D Thomas, S Schmidt. *Giant Abdominal Liposarcoma: A Case Report*. The Internet Journal of Urology. 2000 Volume 1 Number 1.

## Abstract

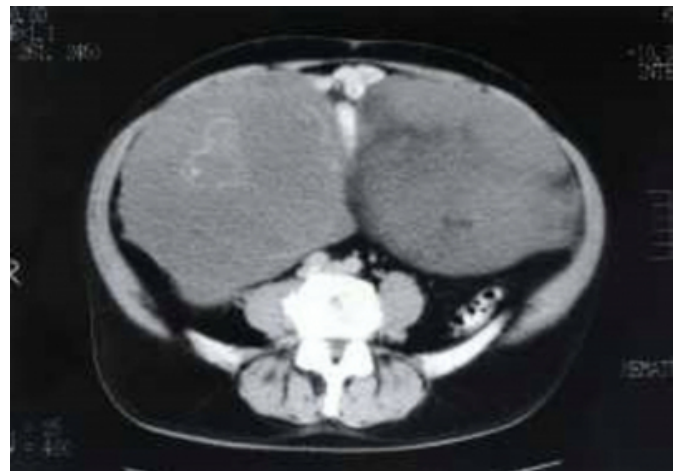Primary mesenteric liposarcoma is a rare malignant tumor of mesenchymal origin (1,2,3,4). These tumors are often found to be of substantial size upon diagnosis. We report a case of primary mesenteric liposarcoma that weighed approximately 8.5 kilograms. To our knowledge, this is only the seventeenth case of mesenteric liposarcoma reported in the English literature to date (2,3,5,6,7) as well as the largest ever reported in the mesentery. Takagi et al (4) has previously reported a case of a 40 kilogram liposarcoma, however this tumor was located in the retroperitoneum.

## CASE REPORT

The patient was a 69 year old white male who noticed blood present in his urine approximately six weeks before presentation to the surgeon. He also reported feeling bloated and complained of increasing abdominal distention over the past year. He denied any abdominal pain, constipation, diarrhea, nausea, vomiting, fever, chills, nightsweats, hematochezia, or melena. He reported a five-pound weight loss over the past year, despite his increasing abdominal girth. During the investigation of his hematuria by urology a CT scan was ordered which showed multiple large masses filling the pelvis and abdomen with sizes ranging from 15 to 20 centimeters in size [figure 1]. The lesions were of relatively low density and suggested collections of mucin or complex fluid. Multiple calcific areas were also present within the lesions. No pancreatic mass was noted, nor did the lesions appear connected to the pancreas. Lucencies of undetermined etiology were also reported in both the liver and kidneys. Finally, the CT scan also showed the presence of a large hiatal hernia. Upon evaluation of the CT scan, the patient was referred to the surgeon for treatment.

## Figure 1

Figure 1. CT scan of the abdomen and pelvis revealing the presence of multiple large masses filling the abdomen and pelvis



Past surgical history included two inguinal herniorrhaphies approximately three years prior, nasal polypectomy, and right carpal tunnel surgery. Past medical history included BPH, hypercholesterolemia, hypothyroidism, and vitiligo. The patient had no known allergies. Home medications were prevacid, synthroid, and oxybutrin. The patient did not use tobacco or drugs and socially consumed ETOH. Physical exam was benign with the exception of a markedly distended abdomen that was soft, non-tender, without peritoneal signs, and bowel sounds were hypoactive. The patient's stool was hemocult negative. Initial laboratory values were: WBC 10.8; HgB 12.6; HCT 40.6; PLT 295; MCV 77.3; MCH 24.0; MCHC 31.0; RDW 16.1. The patient's coagulation studies and chemistry profile were within normal limits.

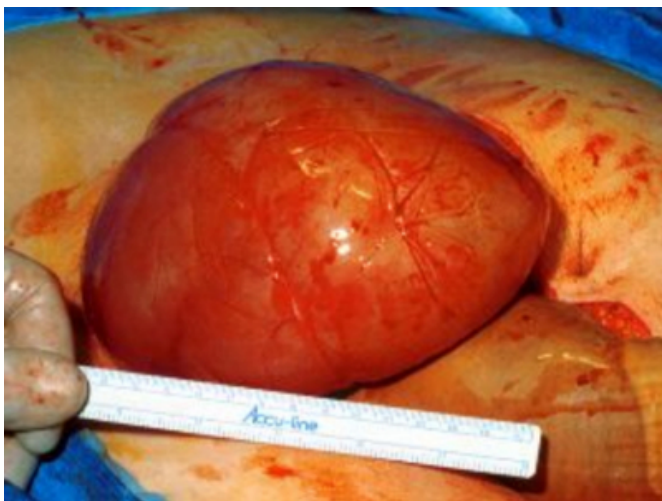Preoperatively, a barium enema was obtained which showed no colonic masses or deformities related to the abdominal masses and the presence of multiple diverticulae.

Upon laparotomy, three large volleyball sized masses were discovered, oblong in shape with multiple projections. The tumors originated from the root of the small bowel mesentery in the mid-jejunal area. Some of the tumors were effacing portions of the small bowel and as a result almost two feet of the small intestine was resected. The abdomen was further explored for additional tumor and evidence of metastatic disease, however none was found.

Pathological sections of the massive multicentric tumor revealed a liposarcoma with a mixed histological pattern. The tumor was a predominately myxoid liposarcoma with areas of pleomorphic liposarcoma, inflammatory liposarcoma, and lipoma-like liposarcoma. Focal areas of osseous metaplasia were also identified. The largest of the three masses was 30.0 x 20.0 x 15.0 cm in size [figure 2]. Together, the three largest masses weighed 8,540 grams. The masses did not invade the mucosa of the resected segment of small bowel.

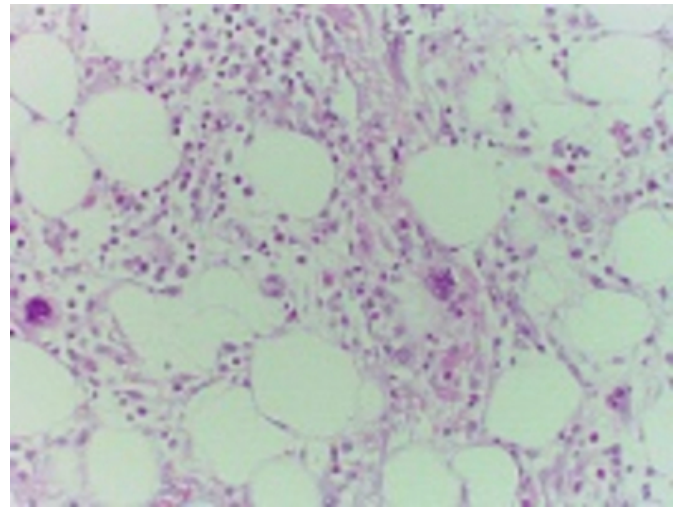
### Figure 2

Figure 2. Gross photograph of one of the masses at the time of laparotomy



### Figure 3

Figure 3: Histological slide



## DISCUSSION

The lower extremity is the most common location for liposarcoma to occur [3,4,8], accounting for 56% of all liposarcomas [4]. The retroperitoneum is the next most frequent location [3,6] with 15% to 20% of all liposarcomas [6]. Liposarcoma arising from the mesentery of the bowel is a rare lesion [2,3,4,6].

Primary mesenteric liposarcomas typically occur during the fifth to seventh decades of life [3,8]. The incidence is slightly higher in males than females [3,8]. Some of the most common presenting symptoms of primary mesenteric liposarcoma include: increasing abdominal girth, weight loss, abdominal pain, abdominal discomfort with meals, and the presence of a freely movable abdominal mass or masses [3].

Histopathologically, liposarcomas are grouped into four major categories: myxoid, well-differentiated, pleomorphic, and round-cell [2,5,7,9]. Well-differentiated liposarcomas are further divided into four types: inflammatory, lipoma-like, sclerosing, and dedifferentiated [2]. Recently, Argani et al [5] has proposed the addition of the lymphocyte-rich liposarcoma classification in lesions with a predominant T-lymphocyte component. Myxoid and well-differentiated types of liposarcoma are by far the most common histological type of tumor [3,10]. However some liposarcomas may be classified as mixed, containing multiple histologic subtypes [2,9] as seen in our patient. Mixed tumors are rare and only found in 5% to 10% of all cases of liposarcoma [9].

Prognosis is based upon the most aggressive histological

subtype in the lesion [1,11]. Well-differentiated lesions are considered low-grade malignancies, myxoid lesions are considered intermediate-grade, and pleomorphic and round-cell lesions are considered high-grade [2]. Spillane et al [10] observed the association of any round-cell component with myxoid liposarcomas to have a substantially higher risk for metastatic disease. Recently Sato et al [7] concluded that tumor size greater than 20 cm predicted a significantly poorer prognosis.

The treatment of choice for primary mesenteric liposarcoma is surgical resection with clear margins [3,7,8]. Neither radiotherapy nor systemic chemotherapy has been proven to be of benefit in increasing long-term survival [3,8]. Our patient is currently alive and well with no evidence of tumor recurrence 2 years after resection of his primary mesenteric liposarcoma, which is quite remarkable based on the size and unfavorable histology of his multiple lesions.

### References

1. Evans HL. Liposarcomas and atypical lipomatous tumors: a study of 66 cases followed for a minimum of 10 years. *Surg Pathol* 1988;1:41-54.
2. Kim T, Murakami T, Oi H, Tsuda K, Matsushita M, Tomoda K, Fukuda H, Nakamura H. CT and MR imaging of abdominal liposarcoma. *Am J Roentgenol* 1996;166:829-33.
3. Moyana TN. Primary mesenteric liposarcoma. *Am J Gastroenterol* 1988;83:89-91.
4. Takagi H, Kato K, Yamada E, Suchi T. Six recent liposarcomas including the largest to date. *J Surg Oncol* 1984;26:260-7.
5. Argani P, Facchetti F, Inghirami G, Rosai J. Lymphocyte-rich well-differentiated liposarcomas: report of nine cases. *Am J Surg Pathol* 1997;21:884-95.
6. Pawel BR, de Chadarevian JP, Inniss S, Kalwinski P, Paul SR, Weintraub WH. Mesenteric pleomorphic liposarcoma in an adolescent. *Arch Pathol Lab Med* 1997;121:173-6.
7. Sato T, Nishimura G, Nonomura A, Miwa K. Intra-abdominal and retroperitoneal liposarcomas. *Int Surg* 1999;84:163-7.
8. Fernandez-Trigo V, Sugarbaker PH. Sarcomas involving the abdominal and pelvic cavity. *Tumori* 1993;79:77-91.
9. Kato T, Motohara T, Kaneko Y, Shikishima H, Takahashi T, Okishiba S, Kondo S, Kato H. Case of retroperitoneal dedifferentiated mixed-type liposarcoma: comparison of proliferative activity in specimens from four operations. *J Surg Oncol* 1999;72:32-6.
10. Spillane AJ, Fisher C, Thomas JM. Myxoid liposarcoma—the frequency and the natural history of nonpulmonary soft tissue metastases. *Ann Surg Oncol* 1999;6:389-94.
11. Reitan JB, Kaalhus O, Brennhovd IO, Sager EM, Stenwig AE, Talle K. Prognosis factors in liposarcoma. *Cancer* 1985;55:2482-2490.

**Author Information**

**Alfred Ciraldo, M.D.**

Attending Surgeon, Department of Surgery, Summa Health System

**David Thomas, D.O.**

Medical Student, Department of Surgery, Summa Health System

**Steven Schmidt, PhD**

Director, Department of Surgery, Division of Surgical Research, Summa Health System