

## Image of the Month: Ball In The Belly

F Cuculi, T Ehmann

### Citation

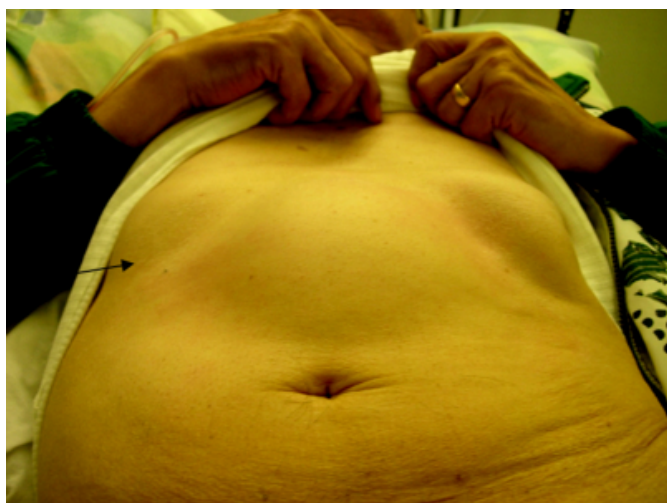
F Cuculi, T Ehmann. *Image of the Month: Ball In The Belly*. The Internet Journal of Gastroenterology. 2006 Volume 5 Number 1.

### Abstract

A 69 year old patient with a history of diabetes mellitus and chronic obstructive lung disease was referred by his general practitioner for the evaluation of acute upper gastrointestinal bleeding. He complained of epigastric discomfort with the feeling of a "football" in the belly 2-3 hours after food intake, followed by emesis and weight loss of 6 kg over the last 6 weeks. During the physical examination a wandering, slightly tender mass was palpable in the upper abdomen (arrow Fig 1).

### Figure 1

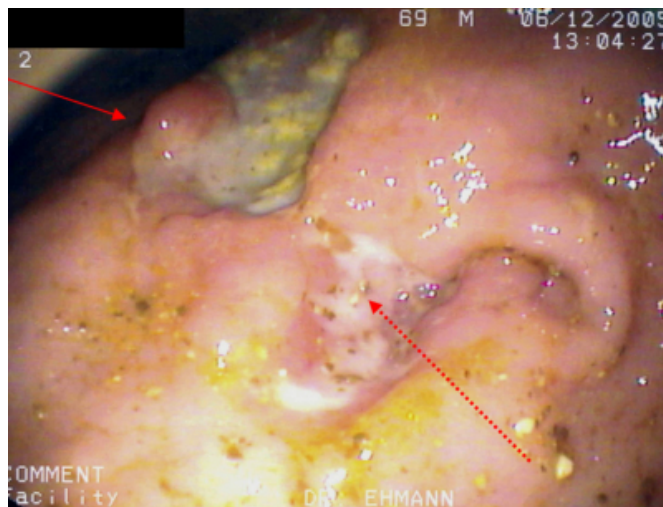
Figure 1: Palpable mass in the upper abdomen



An upper endoscopy was performed which showed a massively distended stomach with food retention. Additionally a large ulcer (arrow Fig 2) was seen in the antrum along the minor curvature. There was an inflammatory stenosis of the pylorus (dashed arrow Fig 2) which could hardly be passed with the endoscope. The biopsies revealed the diagnosis of moderately differentiated tubular adenocarcinoma of the stomach.

### Figure 2

Figure 2: Antral ulcer (arrow) and pyloric stenosis (dashed arrow)



### References

**Author Information**

**Florim Cuculi**

Kantonsspital Luzern

**Tobias Ehmann**

Kantonales Spital Sursee-Wolhusen