

Strongyloides-induced Respiratory Failure

N Jones, J Tran, S Naito, P Taylor, B Tran

Citation

N Jones, J Tran, S Naito, P Taylor, B Tran. *Strongyloides-induced Respiratory Failure*. The Internet Journal of Pulmonary Medicine. 1999 Volume 1 Number 2.

Abstract

Strongyloides stercoralis is a parasitic nematode particularly prevalent in certain areas such as Southeast Asia. Due to its unique capacity for autoinfection, humans can harbor the parasite for the majority of their lives. The pulmonary migration phase of the parasite's life cycle can imitate asthma and can easily be misdiagnosed. In the immunocompromised patient, a *Strongyloides* infection can progress to systemic infection and respiratory failure. Systemic steroids, while useful for many clinical conditions, can serve as the immunosuppressive spark for overwhelming *Strongyloides* dissemination in the undiagnosed patient. Two case histories illustrate this point to two different degrees. The first case involves a seemingly chronic asthmatic whose respiratory ailments resolve when underlying Strongyloidiasis is revealed. The second case involves a steroid dependent woman with SLE whose undiagnosed *Strongyloides* infection progresses to respiratory failure and death. While difficult to diagnose, subclinical infection should always be suspected in immigrants and visitors from endemic foci. Since early intervention can be life saving, evidence of *Strongyloides* infection should always be watched for in such high-risk patients undergoing immunosuppressive therapy, particularly those with respiratory complications.

INTRODUCTION

Although the intestinal nematode *Strongyloides stercoralis* is essentially ubiquitous, it is known to be particularly prevalent in certain parts of the world, such as Southeast Asia, the southeast region of the United States, and the Caribbean. As reported in previous literature, the pulmonary migration phase of *Strongyloides* infection can present to the physician as an acute asthma attack. Previously asymptomatic strongyloidiasis can also be exacerbated in patients with comorbid pulmonary or autoimmune diseases who are treated with systemic steroids, leading to hyperinfection and respiratory compromise. When missed, treatment aimed at reducing an acute inflammatory condition can be either counterproductive or can allow the infection to build to critical levels. With this in mind, patients exposed to endemic areas with a history of immunosuppression and respiratory complications should be considered for Strongyloidiasis, and here we present two such cases.

REPORT OF A CASE

The first case was a 75 year old Vietnamese male with a five year history of asthma with chronic steroid management for which he has been hospitalized multiple times. In June of 1998, the patient presented to the Pomona Valley Hospital Emergency Department for respiratory distress two days after a ten-day hospital stay for asthmatic bronchitis. He had

experienced a sudden onset of dyspnea not relieved by beta-agonist. He denied fever, but did complain of a pruritic rash on his abdomen. Medications at time of admission included prednisone (40 mg daily), theophylline, zafirlukast, albuterol, and ipratropium/triamcinolone acetonide metered dose inhalers. The patient had a fifty-pack*year smoking history, but had not smoked for several years.

On physical exam, the patient was in acute respiratory distress, with a blood pressure of 190/94, bilateral expiratory wheezes, and serpiginous erythematous rash over the lower abdomen and proximal thighs. After intubation in the ICU, arterial blood gases revealed a pH of 7.17, pCO₂ of 102, and pO₂ of 131 on 100% O₂ non-rebreather mask. Chest x-ray showed hyperinflation with interstitial infiltration bilaterally (figures 1,2). Laboratory values showed a WBC count of 24,000 with 5% eosinophils, blood glucose of 216, and a theophylline level of 0.5 ug/ml. Sputum Gram's stain was positive for WBCs and nematode larvae consistent with *Strongyloides stercoralis* (figure 3). Stool examinations were negative for *Strongyloides* larvae, but did detect hookworm, either *Necator americanus* or *Ancylostoma duodenale*.

Figure 1

Figure 1: Hyperinflation with interstitial infiltration bilaterally

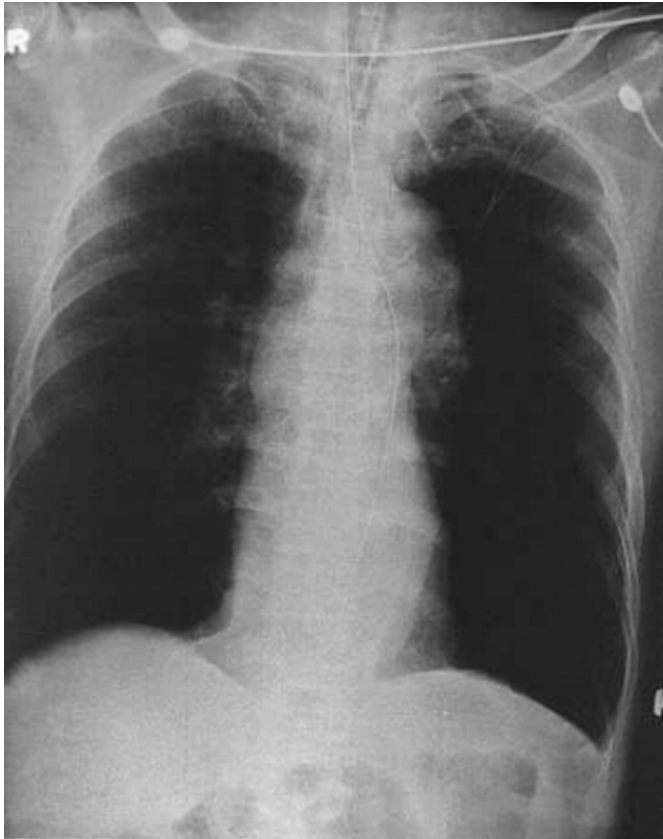


Figure 2

Figure 2: Hyperinflation with interstitial infiltration bilaterally

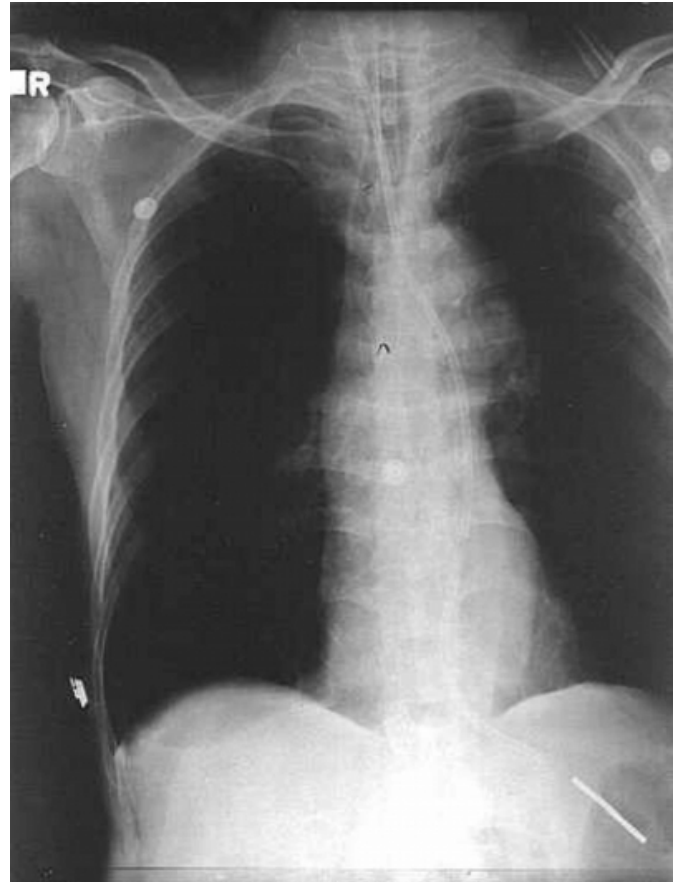
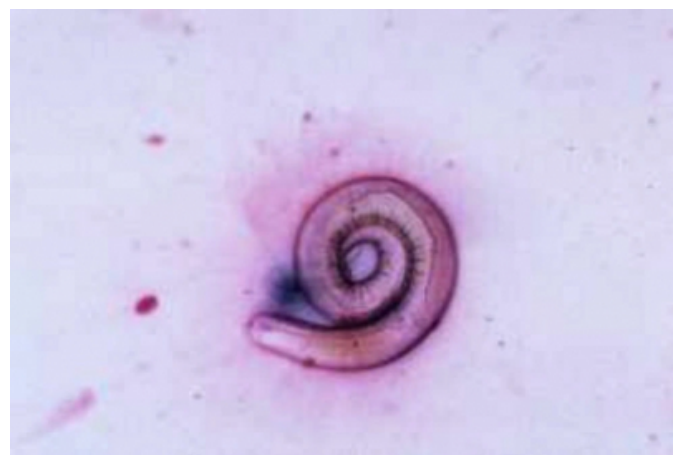

Figure 3

Figure 3: Sputum Gram's stain positive for WBCs and nematode larvae consistent with *Strongyloides stercoralis*



The patient was given intravenous methylprednisolone, aminophylline, and piperacillin/tazobactam for coverage of possible aspiration pneumonia. A three-day course of albendazole (400 mg daily) was given for treatment of both *Strongyloides* and hookworm, after which time stool

examinations were negative for the parasites. Unfortunately, sputum Gram's stain remained positive for the larvae. Following an additional two-day regimen of ivermectin (200 ug/kg daily), the patient's respiratory symptoms improved to the point where he could be extubated. Despite the improvement, the patient continued to demonstrate *Strongyloides* larvae in the sputum. Ivermectin therapy was continued for nine more days and methylprednisolone was tapered over this time, until the sputum was negative for larvae. The patient was transferred to the transitional care unit for rehabilitation before discharge on low dose oral prednisone (10 mg daily).

REPORT OF A CASE

The other case concerns a forty-year-old Cambodian female with a four-year history of Systemic Lupus Erythematosis (SLE) with secondary nephritis, nephrosis, and vasculitis, and many exacerbations requiring hospital admission and chronic steroid therapy. This patient presented to the same emergency room following a two-day episode of nausea and vomiting with recent onset of abdominal pain and fever. Current medications included prednisone (50 mg daily), and plaquenil (200 mg twice daily).

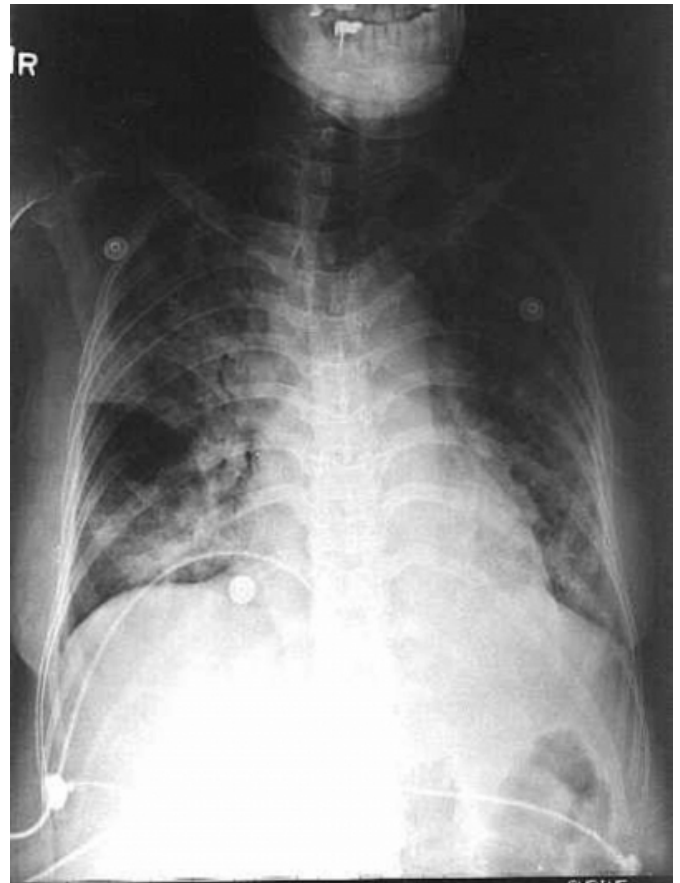
On physical exam, the patient appeared in some distress, with a temperature of 102.2 and pulse of 104. The abdomen was soft, tender to palpation with positive tympany on percussion. Abdominal plain films were negative for free air. Ultrasound demonstrated ascitic fluid with possible ruptured appendix or ruptured ovarian cyst. An acute abdomen was assumed, but exploratory laparotomy showed mild non-purulent ascites with no evidence of acute appendicitis. Peritoneal Gram's stain was negative, but cultures were positive for coagulase-negative staphylococcus. The patient tolerated appendectomy without complication and was placed on antibiotics post-operatively. Pathology reported the appendix to have mild eosinophilic infiltration.

Four days post-operatively, the patient developed a fever and tachypnea. Pulmonary auscultation revealed crackles bilaterally in all lung fields. Chest X-ray demonstrated diffuse alveolar infiltration (figure 4). CBC showed a WBC count of 15,000, with a hemoglobin of 8.2 and hematocrit of 24.1. Sputum culture showed few Gram-positive cocci, and blood cultures were negative. The patient progressed to acute respiratory failure and was subsequently intubated. Arterial blood gas showed a pH of 7.28, pCO₂ of 40, pO₂ of 105 on 70% FIO₂ assist control ventilation. Antibiotic regimen was expanded to cover anaerobic bacteria, as well

as atypical and opportunistic respiratory pathogens. Sputum specimens were sent for staining and culture to evaluate for possible *Pneumocystis*, *Strongyloides*, *Cryptococcus*, or *Mycobacterium* infections. Serological analysis for cryptococcal antigens and coccidioidal antibodies was performed along with a urinary screen for *Legionella* species antigen.

Figure 4

Figure 4: Diffuse alveolar infiltration



Despite repeatedly negative sputum and serologic stains and cultures over the next three days, the patient progressed to respiratory failure, requiring sedation and an FIO₂ level of 100% (figure 5). Bilateral lung fields showed increasing alveolar infiltration. As her condition deteriorated, the patient spontaneously developed hemorrhagic pulmonary secretions and an acute rash of the abdomen. Although she had a normal sedimentation rate, progression to lupus pneumonitis with cutaneous vasculitis seemed the only possibility. At this point, a sputum sample was positive for *Strongyloides stercoralis* larvae and the etiologic factor was finally revealed (figure 6). Unfortunately, it was too late and despite initiation of ivermectin (200 ug/kg daily) and thiabendazole (25 mg/kg daily) therapy, the patient

developed cardiopulmonary arrest unresponsive to resuscitation. The terminal diagnosis was “Strongyloides hyperinfection syndrome” leading to peritonitis, respiratory failure, and death.

Figure 5

Figure 5: Bilateral lung fields with increasing alveolar infiltration

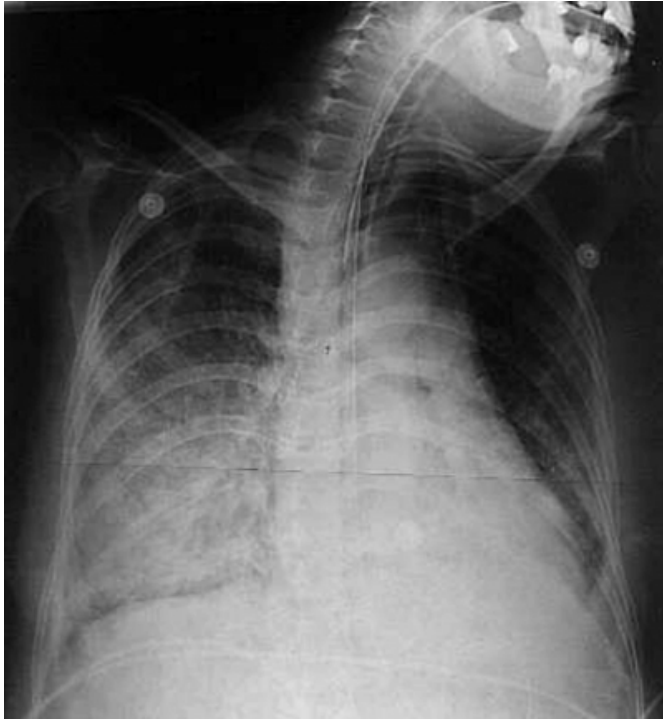
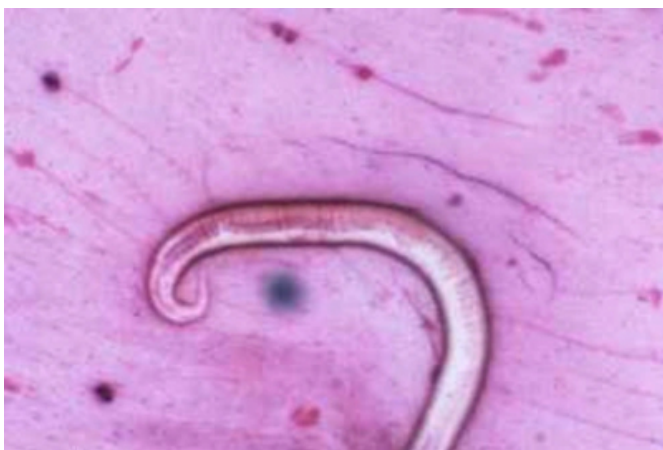
Figure 6

Figure 6: Sputum sample positive for Strongyloides stercoralis



PATHOGENESIS

In order to appreciate the challenge of diagnosing and treating strongyloidiasis, it is first necessary to review the life cycle of this unusual intestinal nematode. Filariform, or

infective Strongyloides larvae, from fecally contaminated soil penetrate the skin or mucous membranes of humans to enter the venous circulation. The larvae then travel to the lungs, where they rupture into the alveoli and ascend the bronchi to the trachea. Tracheal irritation causes the host to cough and then swallow, allowing the tiny larvae access to the duodenum and proximal jejunum where they mature. The adult worms are female and reproduce via parthenogenesis, producing eggs that immediately hatch into rhabditiform larvae.

Most of the rhabditiform larvae produced in the small intestine exit the host with the evacuation of feces. These non-infective larvae become filariform larvae in the soil, able to infect a new host. However, Strongyloides larvae also have the unique ability to re-infect the host. In this process called “autoinfection”, some of the rhabditiform larvae transform directly into filariform larvae within the small bowel. These larvae can then penetrate either the intestinal mucosa or the perianal skin to enter the venous blood and follow the path of the original exogenous parasite. Strongyloides stercoralis is the only intestinal nematode found in North America with the capacity to proliferate within the human host without further exogenous exposure.²

PRESENTATION AND DIAGNOSIS

Strongyloides stercoralis can persist within a person decades after the original exposure, and it is estimated that 90% of infected individuals have low-level infections which are not clinically apparent.² Those who are symptomatic may have vague complaints, such as intermittent loose stools, bloating, abdominal pain, or a transient pruritic skin rash called “larva currens” caused by filariform larvae migrating in the skin. Hyperinfection, where the worm burden within the host has increased to the point of potential dissemination, occurs in roughly ten percent of those infected, and primarily in children of endemic areas with repeated exogenous exposure.²

Since even symptomatic strongyloidiasis is usually transient and non-specific, clinical diagnosis of this parasitosis can be very difficult and diagnosis must usually be drawn from the laboratory evidence. As with parasitic infections in general, eosinophilia serves as a sensitive but non-specific marker of Strongyloides infection. While 75% percent of uncomplicated strongyloidiasis cases present with a mean eosinophil count of 13-18% of the WBC count, in hyperinfection syndromes only 20% of patients show any degree of eosinophilia, with eosinopenia serving as a poor

prognostic indicator.¹ Because eggs produced in the intestine immediately hatch into rhabditiform larvae, it is extremely difficult to detect ova in the stool. Similarly, as the parasitic worms live within the bowel tissue rather than in the intestinal lumen, it is also rare to find worms in the stool. In order to approach one hundred percent sensitivity in detecting intestinal infection, seven serial stool specimens have to be examined for *Strongyloides* larvae.² Where available, the optimal diagnostic test for *Strongyloides stercoralis* infection is the ELISA, in which parasite specific IgG is detected with sensitivity and specificity exceeding ninety percent.²

TREATMENT

Although there are several drugs proven effective against Strongyloidiasis, treatment of this parasitosis remains suboptimal. Like the infective larvae of all nematodes, the filariform *Strongyloides* larva is resistant to most chemical agents. Unlike other intestinal nematode infections, treatment of strongyloidiasis depends on the complete elimination of the organism, rather than a simple decrease in the worm burden on the host.² Although thiabendazole, albendazole, and ivermectin have all proven effective, albendazole and ivermectin have a lower incidence of side effects.^{2,7} The treatment regimens for uncomplicated Strongyloidiasis usually require a two or three-day course of treatment, with follow-up stool examinations to ensure eradication of the larvae. For hyperinfection syndrome or disseminated infection, drug therapy must be extended to at least one week, or until parasites are no longer detectable. When larvae are present in the sputum, however, as in our two cases of pulmonary strongyloidiasis, treatment guidelines are not well defined. In one case of hyperinfection involving a lung abscess in an asthmatic patient, strongyloidiasis was successfully treated with a five-day course of thiabendazole.⁴

Another uncertainty in the approach to pulmonary strongyloidiasis is the role of corticosteroids for treatment of coexisting pulmonary disease. The immune suppression of steroid therapy for asthma-like symptoms may lead to hyperinfection syndrome in patients with subclinical strongyloidiasis. By reducing the inflammatory response to the parasite in the lung, however, minimal doses of steroids may actually be an effective ancillary treatment for pulmonary strongyloidiasis, with or without pre-existing pulmonary disease.

DISCUSSION

As of the mid 1990's, over 300 cases of disseminated strongyloidiasis had been reported in the United States, the majority of which were attributed to corticosteroids and other immunosuppressive agents.² It is postulated that corticosteroids enhance the normal life cycle of *Strongyloides stercoralis*, enabling an asymptomatic infection to progress unchecked through internal autoinfection. Doses of prednisone as low as 20 milligrams daily for a period of five weeks may be sufficient to cause hyperinfection.³ Steroids also tend to mask eosinophilia, making the diagnosis difficult.

Patients with uncomplicated infections may experience a mild pneumonitis during the pulmonary migration phase of the life cycle, usually with occasional cough and wheezing as the only clinical symptoms. The filariform larvae cause alveolar hemorrhage, edema, and an inflammatory reaction within the lung parenchyma, often seen as interstitial infiltrates on chest x-ray.^{5,2} As the larvae have the ability to mature in the respiratory tract as well as in the intestine, adult worms can also cause pulmonary infection. It has also been postulated that immune-mediated pulmonary vascular damage may occur in response to the parasite antigen(s).⁴ These inflammatory changes resulting from pulmonary strongyloidiasis may eventually result in a condition similar to chronic bronchitis or asthma. This is the likely scenario with our first patient.

In the immune-compromised patient, a previously subclinical infection can evolve into hyperinfection, with much more serious consequences. Certain diseases with cell-mediated immune deficiency, such as hematologic malignancies and autoimmune disorders, have been associated with hyperinfection syndrome independent of steroid use. Non-malignant conditions including malnutrition, uremia, and nephrotic syndrome also predispose to hyperinfection.⁵ In pulmonary strongyloidiasis secondary to hyperinfection syndrome, patients can present with asthmatic bronchospasm, dyspnea, and hemoptysis, leading to adult respiratory distress syndrome, with the potential for terminal respiratory failure. Unfortunately, this was borne out in the second case.

The first patient discussed was a former farmer who left Vietnam 23 years ago. As is the common practice in many poorer nations, he confirmed that stool collected from humans, pigs, and buffaloes served as fertilizer for his crops. During his twenty years of farming, he never wore shoes

while working the fields. Since coming to California, he had never returned to an endemic area and therefore harbored the *Strongyloides* parasite for at least 23 years. The presentation of pulmonary strongyloidiasis in this patient is complicated by his comorbid asthma and chronic obstructive pulmonary disorder. Although this was the first occasion where *Strongyloides* larvae were discovered, it is likely that the parasite played a role in previous exacerbations of asthma and respiratory failure. It is even possible that an exacerbation of subclinical strongyloidiasis may have been misdiagnosed as asthma five years ago.

As an opportunistic infection in the immunocompromised patient, *Strongyloides stercoralis* frequently involves the lung. It is therefore reasonable to include this parasitic infection in the differential diagnosis of patients from endemic areas who present with respiratory symptoms, ranging from a mild intrinsic asthma to overt respiratory failure. In these patients, who will most likely lack a significant degree of eosinophilia, induced sputum sample or broncho-alveolar lavage may demonstrate *Strongyloides* larvae. The most reliable diagnostic test for any form of strongyloidiasis, however, remains the ELISA for detection of specific *Strongyloides* antigens. Once the diagnosis is made, prompt initiation of treatment with ivermectin,

albendazole, or thiabendazole is essential for elimination of the parasite and resolution of pulmonary symptoms. Unfortunately, in cases of respiratory failure in the severely immunocompromised patient, as demonstrated in the case of our SLE patient, even aggressive treatment may fail to cure an already overwhelming infection.

References

1. Sim TC, Alam R, Grant JA. Refractory wheezing and septicemia in a 57-year-old man with asthma. *Annals of Allergy* 1990; 65: 180-184
2. Liu LX, Weller PF. Strongyloidiasis and other intestinal nematode infections. *Infectious Disease Clinics of North America* 1993; 7: 655-682
3. Kaslow JE, Novey HS, Zuch RH, Spear GS. Disseminated strongyloidiasis: An unheralded risk of corticosteroid therapy. *J Allergy Clin Immunol* 1990; July: 138
4. Davidson, RA. Infection due to *Strongyloides stercoralis* in patients with pulmonary disease. *Southern Medical Journal* 1992; 85: 28-31
5. Sen P, Gil C, Estrellas B, Middleton JR. Corticosteroid-Induced Asthma: A manifestation of limited hyperinfection syndrome due to *Strongyloides stercoralis*. *Southern Medical Journal* 1995; 88: 923-927
6. Wehner JH, Kirsch CM, Kagawa FT, Jensen WA, Campagna AC, Wilson M: The prevalence and response to therapy of *Strongyloides stercoralis* in patients with asthma from endemic areas. *Chest* 1994; 106: 762-766
7. Mahmoud AAF. Strongyloidiasis. *Clinical Infectious Diseases* 1996; 23: 949-953 **Strongyloides-Induced Respiratory Failure**

Author Information

Nicole L Jones, DO

First-Year Resident , Internal Medicine, California Pacific Medical Center

Joseph D Tran

MSIII, College of Osteopathic Medicine, Western University of Health Sciences

Stacey K Naito

MSIV, College of Osteopathic Medicine, Western University of Health Sciences

Peter A Taylor

MSIII, College of Osteopathic Medicine, Western University of Health Sciences

Bao C Tran, MD, FACP

Clinical Assistant Professor , USC School of Medicine, Western University of Health Sciences