

Foxing A Retained Intraabdominal Foreign Body After Surgery: A Nightmare For The Surgeon

S Singla, Y Kadian, R Godara, P Kajal

Citation

S Singla, Y Kadian, R Godara, P Kajal. *Foxing A Retained Intraabdominal Foreign Body After Surgery: A Nightmare For The Surgeon*. The Internet Journal of Surgery. 2007 Volume 15 Number 1.

Abstract

Mere suspicion of a retained intraabdominal foreign body after surgery upsets the patient and the surgeon particularly in this consumer act era. We report a case history of a 4½-year-old male child in whom clinical and radiological parameters lead to a high index of suspicion for a retained foreign body in the right hypochondrium following surgery for liver injury. But on reexploration, it was found to be a collection of pus, air and necrotic liver tissue between superior surface of the right lobe of the liver and right hemidiaphragm which was mimicking a retained foreign body.

INTRODUCTION

Foreign bodies retained in the peritoneal cavity after surgery are rarely documented owing to medical, legal and other reasons. Each such incidence acquires major importance nowadays because of excessive media types which can jeopardize the reputation of a surgeon amongst his professional colleagues and in the public at large – what happens as in the present case when there is reversal of events, i.e. all clinical and radiological features point toward the suspicion of a retained intraabdominal foreign body but on reoperation, no foreign body is found. This case is being reported to emphasize that even when there is a high index of suspicion for a retained intraabdominal foreign body, the reoperation may be carried out by explaining the indication of resurgery differently rather than by retained foreign body – as incisional hernia in the present case – to avoid unnecessary embarrassment.

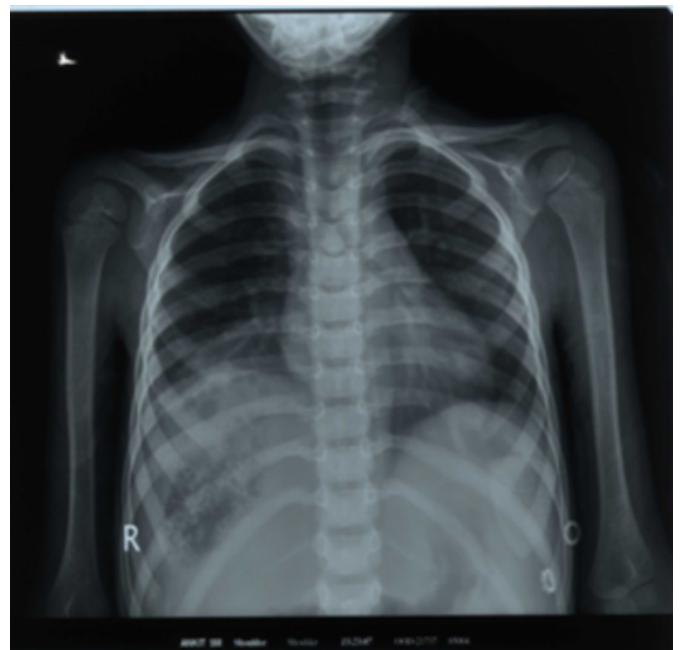CASE REPORT

A 4½-year-old male child was operated one month back for blunt abdominal trauma. On exploration, multiple deep lacerations were found in right lobe of the liver. His immediate post-operative period was uneventful but two months after surgery the child started having fever, abdominal pain and nonbilious vomiting. On examination, the child was anicteric and febrile with an incisional hernia on the medial half of the supraumbilical transverse incision. Further investigations revealed: hemoglobin 9.5g%, total leucocyte count 10500/mm³, polymorphs comprising 65% and ESR 15mm by Wintrobe's method. His peripheral blood

film for malarial parasites was negative and toxic granules were absent. His liver profile was normal. X-rays of chest and abdomen showed an ill-defined focus measuring approximately 5x4cm consisting of patchy hypodensity similar to that of lung in the right hypochondrium with a raised dome of the right hemidiaphragm (fig.1).

Figure 1

Figure 1: X-ray showing a hypodense lesion in the right upper abdomen

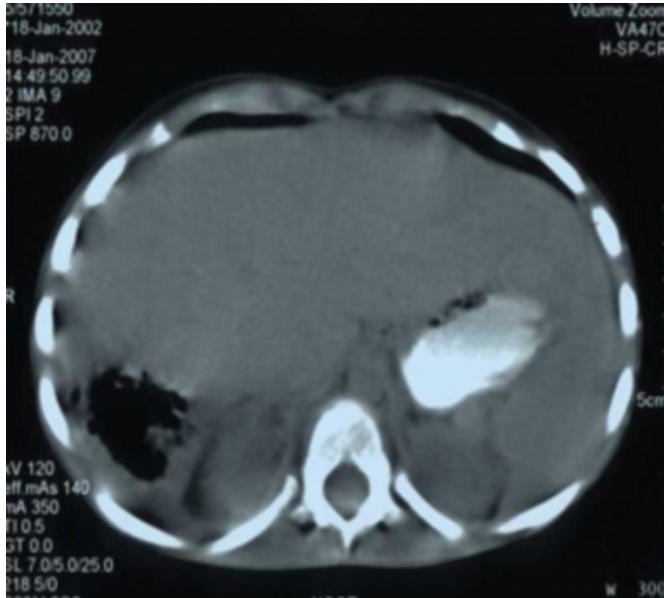


Sonography of the abdomen revealed a collection of varying echogenicity below the right dome of the diaphragm and

suggested presence of a fabric foreign body (gauze piece). CT scan of the abdomen revealed a poorly enhancing well-defined and ill-margined mass lesion of soft tissue density measuring approximately 4.5x5x7.3cm in the right hypochondrium with scattered foci of significant air within it (Fig II).

Figure 2

Figure 2: CT scan of the abdomen showing a lesion of soft tissue density with scattered foci of air within it.



On CT and US findings, the possibility of a foreign body granuloma was kept up. This child was also having incisional hernia and the parents were informed about reoperation for repair of hernia. On reexploration by the same transverse supraumbilical incision there was loculated necrotic liver tissue (confirmed by histopathological examination) surrounded by air, pus and the superior surface of the liver attached to the dome of the diaphragm to form a rounded pocket. Anatomical repair of the incisional hernia was also done. The child remained well in the postoperative period and was discharged on the tenth postoperative day.

DISCUSSION

Clinicians frequently encounter patients with a wide spectrum of complications in the post-operative period following intra-abdominal operations. These include

recurrent abdominal pain, vomiting, fever, abdominal distension and even incisional hernia. These problems are attributed to intra-abdominal fluid collections, abscesses, adhesions and rarely to retained intra-abdominal foreign bodies. Among retained foreign bodies, a surgical gauze or sponge constitutes the most frequently encountered object because of its common usage, small size and amorphous structure.² The usual manifestations of a foreign body left accidentally are abscess, chronic fistula, obstruction, fever, vomiting etc. in the early postoperative period.³

Various reports in the literature describe the radiologic findings of a retained gauze or sponge.^{4,5} Although a typical spongiform pattern with gas bubbles is the most characteristic CT sign for retained surgical sponges, another sign associated with the condition is an inhomogeneously dense mass with a capsule that shows marked enhancement after administration of contrast material. In the present case, the CT picture resembled that of a retained gauze because of loculated air between the right hemidiaphragm and the superior surface of the liver with necrotic material within it. In conclusion, a retained foreign body can be ascribed to various postoperative complications; however, in rare cases like in the present one, when clinical and radiological parameters lead to the presence of a retained foreign body it may not turn out to be one on reoperation.

CORRESPONDENCE TO

Dr. Rajesh Godara 58/9J, Medical Enclave Rohtak Haryana (India) - 124001. Email: drrajeshgodara@yahoo.co.uk

References

1. Buy JN, Hubert C, Ghossain MA. CT of retained abdominal sponges and towels. *Gastrointest Radiol* 1989; 14: 41-5.
2. Sturdy JH, Baird RM, Gerein AN. Surgical sponges: a case of granuloma and adhesion formation. *Am Surg* 1967;165: 128-34.
3. Kokubo T, Itai Y, Ohtomo K, Yoshikawa K, Lio M, Atomi Y. Retained Surgical sponge: CT and US appearance. *Radiology* 1987; 165: 415-8.
4. Nakajo M, Jinnouchi S, Tateno R, Nakajo M. F-FDG PET/CT findings of a right subphrenic foreign body granuloma. *Ann Nuclear Med* 2006; 8; 553-6.
5. Sheward JE, Williams AG, Mettler FA. CT appearance of a surgically retained towel (Gossypiboma). *J Comput Assisted Tomogr* 1986; 10: 343-5.

Author Information

Sham L. Singla, M.S., FICS

Professor, Department of Surgery, Post Graduate Institute of Medical Sciences

Yoginder Singh Kadian, M.S., MCh

Associate Professor, Department of Surgery, Post Graduate Institute of Medical Sciences

Rajesh Godara, M.S., DNB, MNAMS, FAIS, FICS,

Associate Professor, Department of Surgery, Post Graduate Institute of Medical Sciences

Pradeep Kajal, M.S.

Senior Resident, Department of Surgery, Post Graduate Institute of Medical Sciences