
Photopsia post flu: A case of MEWDS

S Baisakhiya, S Dulani, S Lele

Citation

S Baisakhiya, S Dulani, S Lele. *Photopsia post flu: A case of MEWDS*. The Internet Journal of Ophthalmology and Visual Science. 2009 Volume 8 Number 1.

Abstract

Multiple evanescent white dot syndrome (MEWDS) was originally described in 1984 by Jampol et al.^[1] is a rare, acute, unilateral, multifocal retinitis. We describe a case of a young female presented to us with complaints of photopsia and decreased vision after a prodrome of flu like illness. Patient was diagnosed as a case of MEWDS based on typical fundus picture and confirmed by FFA and automated perimetry. The patient as expected regained normal vision in 6 weeks without any treatment except reassurance.

INTRODUCTION

Multiple evanescent white dot syndrome (MEWDS) is a rare, acute, unilateral, multifocal retinitis. The disease affects otherwise healthy young females in second to third decade. Patients with MEWDS complaint of decreased vision associated with photopsia or central scotoma. Prodromal flu like illness may be associated with this syndrome in about 50% of the patients.^[1] The fundus presentation typically includes numerous perifoveal white dots scattered primarily in the posterior pole and just beyond the major arcades associated with orange granular appearance of the fovea. The condition is self limiting within 7 to 10 weeks with a favorable prognosis for vision. Rarely recurrent and bilateral cases have been reported with good visual prognosis even in these cases. The typical fundus appearance and accurate history are mainstay for the diagnosis of the condition. The ancillary tests like FFA, Automated perimetry and ERG help in confirming the diagnosis and ruling out other differential diagnosis. Our patient was of typical age and gender and also the vision improved to normal in 6 weeks period without any treatment. Making the correct diagnosis of MEWDS is difficult due to the subtle and evanescent retinal findings and vision changes.^[8,9] Once the diagnosis is made patient reassurance is the mainstay of management. Fortunately, the disease is self limiting, and the prognosis is good for complete recovery within several weeks.

black spot in front of right eye while reading associated with photopsia. The patient also gave history of flu like illness one week prior to the onset of visual symptoms. On examination the visual acuity in right eye was 20/60 and left eye was 20/20. On external examination the eyes were orthophoric with complete extraocular movements. The anterior segment was unremarkable on slit lamp examination of both eyes. Fundus examination of the right eye revealed a hyperemic optic disc although the margins were clear. There was a granular orange colour appearance of the fovea and foveal reflex was absent (figure 1). There were multiple yellow white dots scattered around the posterior pole the dots were of varying sizes not extending beyond the major vascular arcade (figure 2). The fundus of left eye was within normal limits.

CASE HISTORY

A 20 year old girl presented with complaint of blurring of vision in the right eye since 4 days. She complaint of seeing

Figure 1

Figure1: orange granular appearance of fovea (OD)

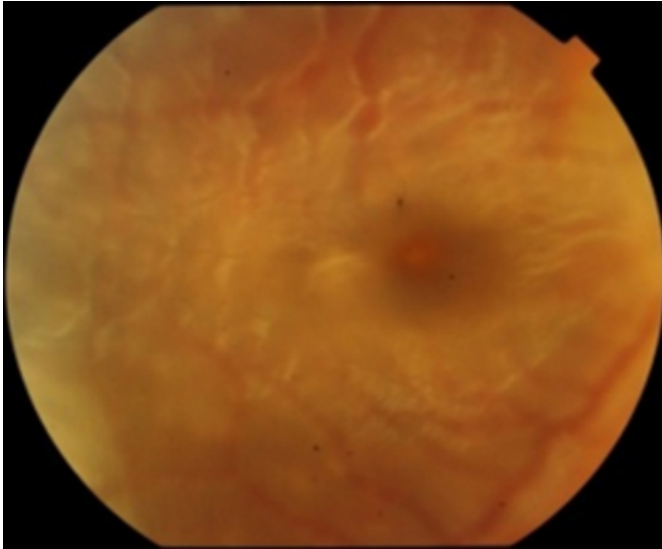
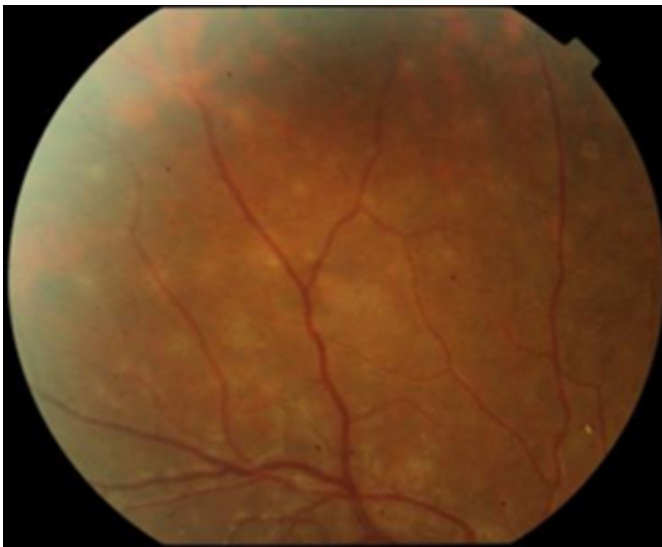


Figure 2

Figure2: Multiple yellow white dots (OD)



The visual field testing revealed an enlarged blind spot of right eye along with temporal scotoma (figure3) and normal field of left eye (figure4).

Figure 3

Figure3: Enlarged blind spot(OD)





Figure 4

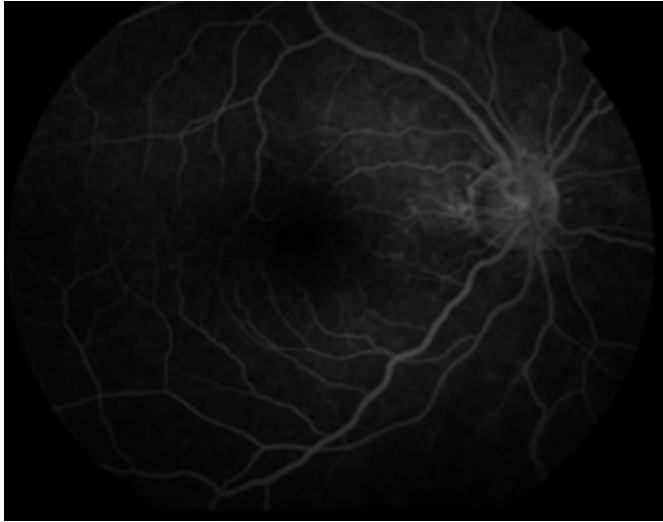
Figure4: Normal field (OS)



The fundus fluorescein angiography of right eye was normal in early phase while there was wreath pattern hyper fluorescence in the late phase (figure5).

Figure 5

Figure5: wreath pattern hyper fluorescence (OD)



We suspected the diagnosis of MEWDS based on clinical features and history and our diagnosis was confirmed by findings of automated perimetry and fundus fluorescein angiography. The patient was reassured and explained regarding the course and prognosis of the disease. The patient follow up was done weekly for 6 weeks. On each subsequent visit there was gradual disappearance of yellow white dots and improvement in visual acuity was noted (figure6). At 6 week follow up the patient's visual acuity improved to 20/20 and dots completely disappeared although the granular appearance of fovea persisted (figure7).

Figure 6

Figure6: Yellow white dots reduced (4 week)

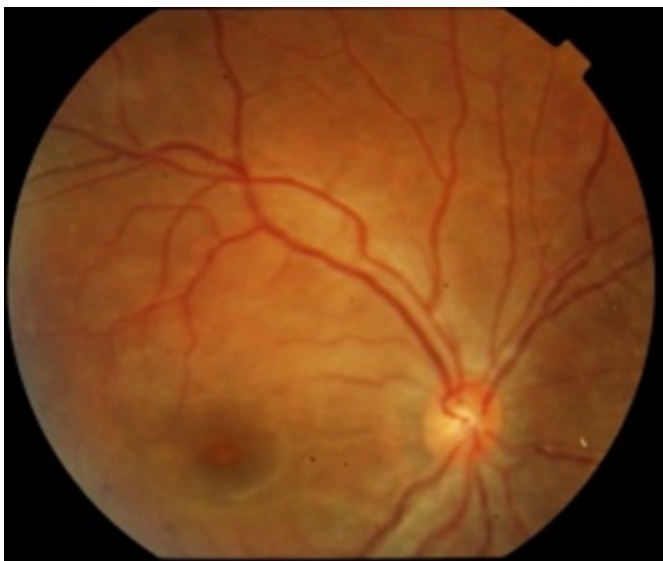
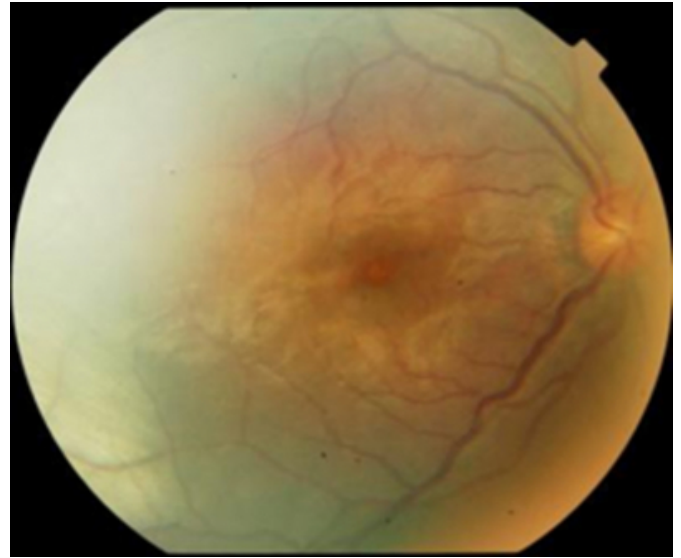
Figure 7

Figure7: Yellow white dots completely disappeared foveal granularity persisted (6 week)



DISCUSSION

Multiple evanescent white dot syndrome (MEWDS) is a rare, acute, unilateral, multifocal retinitis. The syndrome was originally described in 1984 by Jampol et al.^[1] MEWDS cases have been reported worldwide.^[10] Young females are primarily affected in the age group of 17 to 38 year.^[1] Although MEWDS is typically unilateral and non-recurrent, bilateral and recurrent cases have been reported in literature.^[5, 13] The cause of MEWDS is unknown, although the condition is preceded by a flu-like illness in about 50% of the patients. Review of literature reveals individual cases reports of MEWDS with recent hepatitis A and hepatitis B vaccination.^[3, 4] Elevated total serum IgG and IgM and association with the HLA-B51 haplotype have also been reported.^[2] MEWDS patients complaint of reduced visual acuity in the range of 20/20 to 20/300 Scotoma, photopsia, and dyschromatopsia are other associated complaints.^[1, 10] The fundus consists of numerous small ill defined gray-white dots located at the posterior pole approximately 100 to 200 μm in size.^[10] also orange or yellow granular macula is visible. Occasionally a transient afferent pupil defect, venous sheathing, vitreous cells and optic nerve edema are noted.^[12] Choroidal neovascularization has been described in recurrent or consecutive cases of MEWDS.^[6] The principal visual field defect in MEWDS is enlarged blind.^[8, 10] Visual field defects in MEWDS could be due to optic nerve disorder, retinal lesions or choroidopathy. Fluorescein angiography demonstrates early normal and late wreath pattern hyperfluorescence of the gray-white lesions.^[14] On ERG

there is decreased amplitude of a wave and irregular early receptor potential.^[11] Early receptor potential regeneration times are prolonged. These findings suggest photoreceptor involvement. The differential diagnosis of MEWDS includes acute retinal pigment epitheliitis, acute posterior multifocal placoid pigment epitheliopathy, diffuse unilateral subacute neuroretinitis, acute macular neuroretinopathy, multifocal choroiditis variants, and punctate inner choroidopathy, acute idiopathic blind spot enlargement syndrome, and acute zonal occult outer retinopathy.^[1,8,10] The typical fundus appearance and accurate history are mainstay for the diagnosis of the condition. The ancillary tests like FFA, Automated perimetry and ERG help in confirming the diagnosis and ruling out other differential diagnosis.. Making the correct diagnosis of MEWDS is difficult due to the subtle and evanescent retinal findings and vision changes^[8,9] Currently there is no formal protocol of medical therapy for MEWDS However isolate case reports of MEWDS responsive to cyclosporine and steroid pulse therapy have been reported in the literature . Once the diagnosis has been established, the mainstay of management is patient reassurance and follow-up. Fortunately, the disease is self limiting, and the prognosis is good for complete recovery of vision within several weeks. The accurate diagnoses of MEWDS can prevent the burden unnecessary treatment and battery of investigations over the patient.

References

1. Jampol LM, Sieving PA, Pugh D, Fishman GA, Gilbert H. Multiple evanescent white dot syndrome: I. Clinical findings. *Arch Ophthalmol* 1984; 102: 671-4.
2. Chung YM, Yeh TS, Liu JH. Increased serum IgM and IgG in the multiple evanescent white-dot syndrome. *Am J Ophthalmol* 1987; 104: 187-8.
3. Fine L, Fine A, Cunningham ET Jr. Multiple evanescent white dot syndrome following hepatitis A vaccination. *Arch Ophthalmol* 2001; 119: 1856-8.
4. Baglivo E, Safran AB, Borruat FX. Multiple evanescent white dot syndrome after hepatitis B vaccine. *Am J Ophthalmol* 1996; 122: 431-2.
5. Laatikainen L, Immonen I. Multiple evanescent white dot syndrome. *Graefes Arch Clin Exp Ophthalmol* 1988; 226: 37-40.
6. McCollum CJ, Kimble JA. Peripapillary subretinal neovascularization associated with multiple evanescent white-dot syndrome. *Arch Ophthalmol* 1992; 110: 13-4.
7. Borruat FX, Herbort CP, Spertini F, Desarnaulds AB. HLA typing in patients with multiple evanescent white dot syndrome (MEWDS). *Ocul Immunol Inflamm* 1998; 6: 39-41.
8. Arbet TP. Multiple evanescent white dot syndrome. *J Am Optom Assoc* 1997; 68: 769-74
9. Dunbar M. Is grainy picture a diagnostic clue? *Rev Opt* 2001: 98-9.
10. Jampol LM, Tsai L. Multiple evanescent white dot syndrome. In: Ryan SJ, ed. *Retina*, Vol 2. St. Louis: Mosby, 1989: 1699-703.
11. Sieving PA, Fishman GA, Jampol LM, Pugh D. Multiple evanescent white dot syndrome: II. Electrophysiology of the photoreceptors during retinal pigment epithelial disease. *Arch Ophthalmol* 1984; 102: 675-9.
12. Gass JD, Hamed LM. Acute macular neuroretinopathy and multiple evanescent white dot syndrome occurring in the same patients. *Arch Ophthalmol* 1989; 107: 189-93
13. Gass JDM. *Stereoscopic Atlas of Macular Diseases: Diagnosis and Treatment*, 3rd ed, Vol 2. St. Louis: Mosby, 1987: 510-1
14. Tsai L, Jampol LM, Pollock SC, Olk J. Chronic recurrent multiple evanescent white dot syndrome. *Retina* 1994; 14: 160-3.

Author Information

Shikha Baisakhiya, D.O.M.S

Assistant Lecturer, Department of Ophthalmology, Datta Meghe Institute of Medical Sciences

Somya Dulani, M.S

Associate Professor, Department of Ophthalmology, Datta Meghe Institute of Medical Sciences

Seema Lele, D.O

Assistant Lecturer, Department of Ophthalmology, Datta Meghe Institute of Medical Sciences