

Warfarin Induced Spontaneous Cranial Epidural Hematoma: A Case Report And Review Of The Literature

M Ustundag, M Sayhan, S Gokhan, M Orak, M Gokdemir

Citation

M Ustundag, M Sayhan, S Gokhan, M Orak, M Gokdemir. *Warfarin Induced Spontaneous Cranial Epidural Hematoma: A Case Report And Review Of The Literature*. The Internet Journal of Emergency Medicine. 2008 Volume 6 Number 1.

Abstract

Introduction: Epidural haematomas are almost always traumatic in origin. The occurrence of spontaneous cranial epidural hematoma (SCEH) is rare and its incidence is not known. In literature scanning; two cases of non-traumatic SCEH has been reported, but no case of warfarin induced SCEH has been reported. We want to attract attention to a case which cannot be seen in literature scanning: SCEH caused by warfarin. **Case:** A 76-year-old woman applied to our emergency room with suddenly depressed consciousness level. There were no external signs of any trauma to the scalp or face and there was no previous history of any trauma. She had undergone cardio embolic stroke ten years before. She had been taking warfarin. Computed tomography of the brain revealed bilateral chronic subdural effusions with a large left temporal epidural haematoma but no evidence of skull fracture or cephalohaematoma. **Conclusion:** Long-term anticoagulant drug therapy may cause spontaneous epidural haematoma. Many clinicians continue to perceive that older persons who are at increased risk of falling have an unacceptably high risk of antithrombotic-related major hemorrhage.

INTRODUCTION

The occurrence of spontaneous cranial epidural haematoma (SCEH) is rare and its incidence is not known. Typically, there is no history of any head trauma. It is associated with coagulation disorders such as hypofibrinogenemia or thrombocytopenia and in such situations can manifest in a catastrophic fashion (1). In our case; we wanted to draw attention on SCEH caused by warfarin and its case and treatment. We described one patient with atrial fibrillation and cardio embolic stroke who suffered intracranial epidural haematoma during long-term anticoagulant drug therapy.

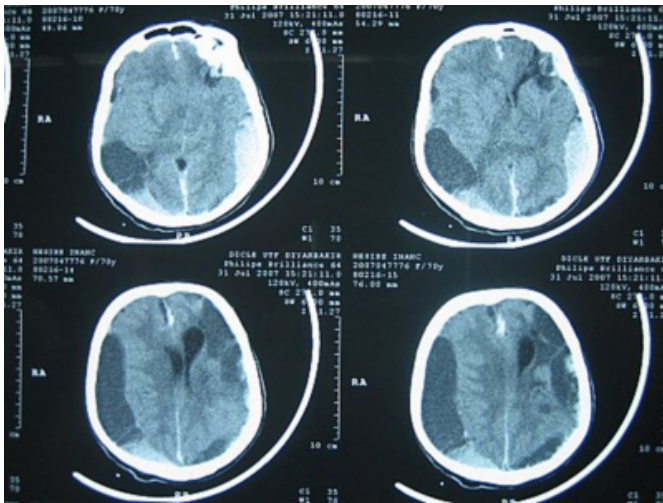
CASE

A 76-year-old woman applied to our emergency room with suddenly depressed consciousness level. She was admitted with haematuria and widespread ecchymosis bruise on her body which developed 2 days earlier. In the first examination of the patient, she was comatose, bilateral babinski's signs were negative, arterial blood pressure was 160/90 mm Hg, pulse was 104/min, respirations 19/min, and the axillary body temperature was 36.7° C. Pupils were 5 mm in diameter and were reactive to light bilaterally. Glasgow coma scale was E2M3V3. There were no external signs of any trauma to the scalp or face and there was no previous history of any trauma. She had been suffering from

chronic heart disease and chronic atrial fibrillation. She had no other co-morbid conditions (diabetes mellitus, hypertension, systemic lupus erythematosus, chronic renal failure, sickle cell disease, malignancies and history of open heart surgery, hemodialysis). She had undergone cardio embolic stroke ten years before. She had been taking warfarin (5 mg/day). A urethral catheter administered for monitoring patient's urine output. Urine was haematuric. A nasogastric catheter was administered to help aspiration which might not be maintained due to unconsciousness. We performed electrocardiogram, and detected atrial fibrillation. The patient's radiographic evaluation including plain x-ray films were normal. Computed tomography (CT) of the brain revealed bilateral chronic subdural effusions with a large left temporal epidural haematoma (about 2 cm in diameter) with no evidence of skull fracture or cephalohaematoma (Fig. 1).

Figure 1

Figure 1: Computed tomography of the brain revealed bilateral chronic subdural effusions with a large left temporal epidural haematoma



Complete blood cell count (leukocyte, platelet, hematocrit, and hemoglobin count), blood glucose level, electrolytes, liver functions, arterial blood gas determinations, antithrombin 3, protein C, protein S levels were in normal range. The patient's prothrombin time/international normalized ratio (PT/INR) level was 4.4 and activated partial thromboplastin time (APTT) level was 30 sec. Fresh frozen plasma (15mL/kg) and vitamin K were administered intravenously after anticoagulant administration was ceased. The patient was transferred to the intensive care unit. Respiratory support and intravenous fluid resuscitation were performed; however, despite all measures, the patient died in the intensive care unit three days after admission.

DISCUSSION

Epidural hematoma commonly results from a blow to the side of the head and is frequently caused by a fracture that passes through an arterial channel in the bone, most commonly a break in temporal bone interrupting middle meningeal artery, a branch of the external carotid. The bleeding arises from lacerated meningeal vessels, the fracture edges, torn venous sinuses or diploes veins. Skull fractures are estimated to be associated in 65–90% of patients (2).

Spontaneous or 'non-traumatic' epidural haematomas are unusual. Ng WH et al defined review of cases of spontaneous epidural haematomas (3). Our patient did not have coagulopathy secondary to chronic liver disease. In addition to the fact that aetiological agents include infectious diseases of the skull, vascular malformations of the dura-

mater and metastasis to the skull were not detected.

Warfarin is used for the prevention of systemic thromboembolism in patients with prosthetic heart valves or atrial fibrillation of myocardial infarction or stroke, and for the treatment of deep vein thrombosis. Warfarin directly inhibits the production of factors II, VII, IX, and X (4). A significant disadvantage of the use of this therapy is an increased incidence of major hemorrhagic episodes (5). The reported incidence of bleeding complications in patients taking warfarin varies. The incidence of major haemorrhage has been reported at 1.0–3.0% per year. Minor haemorrhage complications are said to occur at a rate of 4.8–9.5% per year (6). Brigden reported an overview of 25 studies where the average annual frequency of fatal bleedings was 0.6%; major bleedings 3%; and minor bleedings 9.6% (7). Intracranial hemorrhage (ICH) can be divided into three general categories: intraparenchymal (intracerebral), subdural/epidural, and subarachnoid hemorrhage. Of these, intracerebral hemorrhage is the most common, comprising about 70 percent of anticoagulant-related bleedings. Subdural hematoma is the least common category of ICH resulted from warfarin, comprising about 30 percent of cases (8). Diamond et al reviewed 22 patients with subdural haematoma associated with long-term oral anticoagulation (9). In literature, no case of warfarin induced spontaneous epidural hematoma has been reported. Compared to younger persons, those over the age of 65 years are at higher risk of these antithrombotic-related complications (10). The major predictors of ICH with warfarin therapy include ages over 70, uncontrolled hypertension (especially systolic hypertension), prior cerebrovascular attack, and INR greater than 3 (8). Our patient was 76 years old. She had had a cardio embolic stroke ten years prior to admission. In her first examination, arterial systolic blood pressure was 160 mmHg. Laboratory measures showed that PTR INR was greater than 3. Vitamin K and fresh frozen plasma are standard therapies to reverse warfarin anticoagulation, but neither agent is ideal for emergency anticoagulation reversal. Both vitamin K and fresh frozen plasma take several hours to reduce the INR and have a potential for adverse reactions (7).

CONCLUSION

Long-term anticoagulant drug therapy may cause spontaneous epidural haematoma. We consider careful monitoring and control of the blood coagulation status in order to prevent fatal complication. Many clinicians continue to perceive that older persons who are at increased risk of

falling have an unacceptably high risk of antithrombotic-related major hemorrhage.

References

1. Crooks DA. Pathogenesis and biomechanics of traumatic intracranial hemorrhages. *Virchows Archiv. A, Pathological anatomy and histopathology* 1991; 418: 479–83.
2. Kuwayama N, Sugita K, Sonobe M, Takahashi S. Spontaneous bilateral extradural hematomas: a case report. *No shinkei geka. Neurological surgery* 1984; 12(13): 1535–8.
3. Ng WH, Yeo TT, Seow WT. Non-traumatic spontaneous acute epidural haematoma. *Journal of Clinical Neuroscience* 2004; 11(7): 791–3.
4. Hirsh J, Dalen JE, Anderson DR, Poller L, Bussey H, Ansell J, Deykin D. Oral anticoagulants: mechanism of action, clinical effectiveness, and optimal therapeutic range. *Chest* 2001; 119(8): 21.
5. Levine MN, Raskob G, Landefeld S, Kearon C. Hemorrhagic complications of anticoagulant therapy. *Chest* 2001; 119:108–21.
6. Triplett D. Current recommendation for warfarin therapy. Use and monitoring. *The Medical clinics of North America* 1998; 83: 601–11.
7. Brigden ML. When bleeding complicates anticoagulant therapy. How to anticipate, investigate and treat. *Postgraduate medicine* 1995; 98: 153–65.
8. Garcia DA, Regan S, Crowther M, Hylek EM. The Risk of Hemorrhage among Patients with Warfarin- Associated Coagulopathy. *Journal of the American College of Cardiology* 2006; 47(4):804.
9. Diamond T, Gray WJ, Chee CP, Fannin TF. Subdural haematoma associated with long term oral anticoagulation. *British journal of neurosurgery* 1988; 2: 351–6.
10. Fihn S, Callahan CM, Martin DC, McDonell MB, Henikoff JG, White RH. The risk for and severity of bleeding complications in elderly people treated with warfarin. *Annals of internal medicine* 1996; 124: 970–9.

Author Information

M Ustundag

Dicle University Faculty of Medicine, Emergency Department, Diyarbakır/Turkey

MB Sayhan

Dicle University Faculty of Medicine, Emergency Department, Diyarbakır/Turkey

S Gokhan

Dicle University Faculty of Medicine, Emergency Department, Diyarbakır/Turkey

M Orak

Dicle University Faculty of Medicine, Emergency Department, Diyarbakır/Turkey

MT Gokdemir

Dicle University Faculty of Medicine, Emergency Department, Diyarbakır/Turkey