

# Papillary carcinoma of thyroid: Rare first presentation as a salivary cyst

A Bhatia, Y Kumar, R Nada

## Citation

A Bhatia, Y Kumar, R Nada. *Papillary carcinoma of thyroid: Rare first presentation as a salivary cyst*. The Internet Journal of Pathology. 2007 Volume 7 Number 1.

## Abstract

The differential diagnosis of cystic lesions in the upper part of neck and salivary region includes multiple benign and malignant conditions. Rarely, this may be the first manifestation of a malignancy like papillary carcinoma of thyroid. Here we are presenting the case report of a female patient with a cystic upper neck mass which was diagnosed as a benign salivary cyst clinically and on fine needle aspiration cytology. Histopathology however revealed it to be a malignant lesion harboring papillary carcinoma of thyroid. Subsequent examination of thyroid followed by a thyroidectomy also showed a tiny focus of papillary carcinoma in the right lobe. Therefore, while evaluating a cystic upper neck lesion a possibility of metastatic papillary carcinoma with extensive cystic change should be kept in mind, otherwise a misdiagnosis of benign cyst may result leading to an additional second surgery as was seen in the present case.

## INTRODUCTION

Lateral upper neck masses with cystic degeneration may represent a variety of benign & malignant conditions.<sup>1</sup> Papillary carcinoma of thyroid presenting as a lateral neck cyst is known<sup>1,2</sup> and usually it represents the metastasis to a cervical lymph node which has undergone extensive cystic degeneration due to liquefactive necrosis.<sup>3</sup> However its presentation as a salivary cyst is extremely rare. Here we present the case report of one such patient who presented first with a cystic upper neck mass.

## REPORT OF A CASE

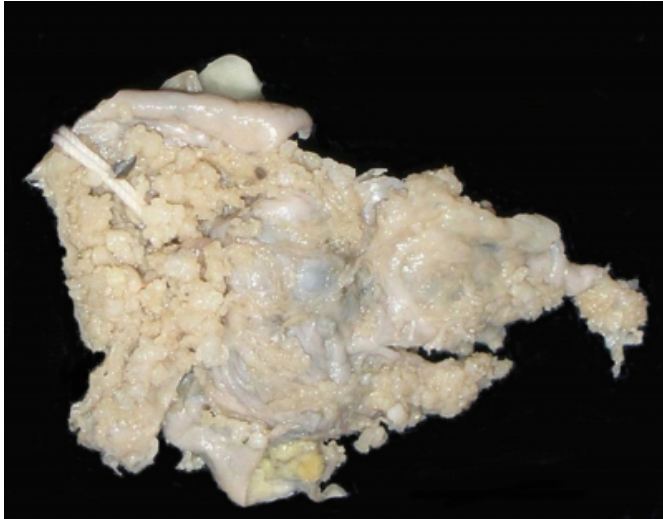
The patient was a 45-year old female who first presented to surgical out patient department for evaluation of chronic cholecystitis. During the routine preoperative check up an upper lateral neck mass measuring 5x4 cm was detected on the right side. The mass was present there for five years. There was no history of increase in size or any pain. The CT scan showed it to be a homogenous mass with cystic degeneration, free from carotid artery & surrounding structures. The thyroid gland was normal clinically. Fine needle aspiration cytology (FNAC) of the mass was performed and possibilities suggested were (i) Infected salivary gland cyst secondary to duct obstruction (ii) Low grade mucoepidermoid tumour. Surgical excision of the mass was done and intra-operatively it was found to be oval in shape and well encapsulated.

Gross examination of the mass showed a cystic structure measuring 4 cm in diameter. Outer surface was smooth & grey white. Cut surface revealed some papillary excrescences (Figure1). The wall thickness ranged from 0.3-0.4 cm. No areas of hemorrhage or necrosis were identified. Microscopically, the cyst was lined by cuboidal to columnar epithelium with focal squamous metaplasia. An occasional papilla was noted which raised the suspicion of a papillary carcinoma. Additional sections were taken which revealed papillary structures, some with hyalinized cores and few follicular structures filled with eosinophilic material resembling the thyroid follicles (Figure2). The cells lining the papillae were also cuboidal to columnar with optically clear nuclei. Few nuclear grooves and nuclear overlapping was also seen (Figure3). The wall of the cyst was composed of lymphoid & fibrocollagenous tissue. No salivary tissue was found. Immunohistochemical staining using monoclonal antithyroglobulin antibody (DAKO) showed positivity in cells as well as in the secretions thereby confirming their origin from thyroid. Hence a diagnosis of cystic papillary carcinoma thyroid metastatic to cervical lymph node was given and the surgeons were requested to search for the primary. On ultrasonography the thyroid gland showed nodular goiter with a separate 0.8cm sized nodule in the right lobe. No other cervical lymph nodes were detected. On histopathologic examination the thyroid nodule was found to contain a focus of microinvasive papillary carcinoma. So a

final report of micro invasive papillary carcinoma thyroid with cystic metastasis to lateral neck lymph node was given.

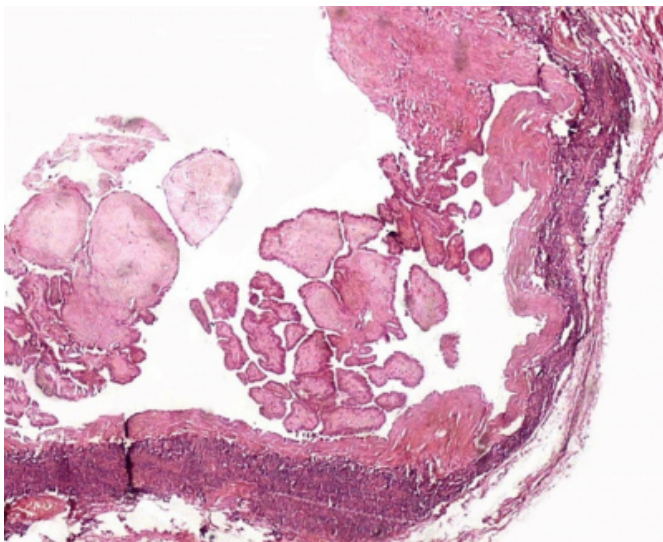
**Figure 1**

Figure 1: Gross photograph of the cut surface of the lesion on upper lateral side of neck. Note the cystic nature and papillary excrescences on the luminal aspect.



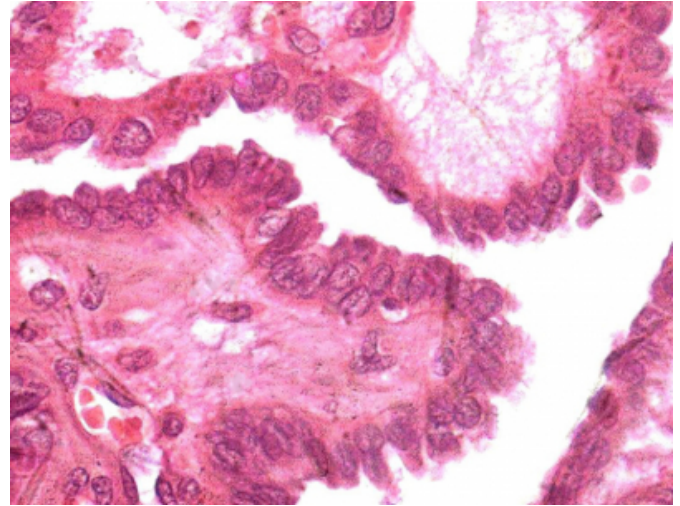
**Figure 2**

Figure 2: Low power microphotograph revealing a cystic lesion with luminal aspect showing papillae. Few follicles filled with colloid material are also present.



**Figure 3**

Figure 3: High power view of the lesion showing cellular and nuclear details. Note the nuclear clearing and overlapping. Few intranuclear grooves can also be appreciated.



**DISCUSSION**

The differential diagnosis of upper lateral cervical cysts includes benign lesions like branchial cleft cysts, cystic hygroma, dermoid cyst, tuberculous lymphadenitis, benign detached goitrous thyroid cyst and malignant lesions like cavitating epidermoid carcinoma. Papillary carcinoma of the thyroid gland diagnosed clinically as a salivary cyst is rare. Sometimes this may be the first and sole manifestation of the disease.<sup>2,3</sup> So evaluation of cystic masses in the upper neck should be carried out with the realization that the mass may represent a malignant process. The size of mass is said to correlate with the risk of malignancy in a cyst. Lesions <3 cm in diameter are reported to have 2% incidence of malignancy whereas those >4cm have a higher incidence.<sup>4</sup> In our case it was 4 cm in diameter. The imaging methods like ultrasonography are helpful as they not only identify the cystic nature of the lesion, but may also reveal any solid area within the cyst. The irregular contour if seen on sonography points towards the malignancy.<sup>5</sup> FNAC has been found to offer a potentially accurate method of diagnosis in previous studies,<sup>6</sup> however in our study it was not very conclusive. This may be due to extensive cystic degeneration seen in the lesion. Some of the previous studies have also quoted a false negative rate of 2- 11% on FNAC.<sup>6</sup> Hammer et al, suggested that the raised thyroid hormone content of the cyst fluid can suggest the possibility of origin from thyroid gland. Ultimately, surgical excision becomes necessary. Even on histopathology the diagnosis can be made only by a thorough examination of the gross and microscopic sections.

In our case first few sections did not reveal many papillae or tumour cells. Re examination of the specimen and additional sections however showed foci characteristic of papillary carcinoma thyroid. Therefore, in case of cystic upper neck masses a possibility of malignant lesion should always be kept in mind, the most common being cystic degeneration of epidermoid carcinoma. Other malignancies which can present in a similar manner include malignant change in previous benign cysts or cystic papillary carcinoma metastasizing to a lymph node.<sup>2</sup> It is well known that cystic degeneration in the lymph node involved by papillary carcinoma can be to such an extent that virtually no native lymphoid tissue is left. The cystic change may be due to liquefactive necrosis of the subcortical region.<sup>3</sup> In our case lymphoid tissue was identified only focally in the cyst wall.

In conclusion, awareness of the possibility of a malignancy in upper neck cysts by the pathologists and surgeons is crucial because if a diagnosis of malignancy is obtained preoperatively on frozen section or FNAC, a definitive surgery can be performed in the same sitting. Otherwise the excision of the cyst & closure of the wound may be followed by additional surgery pending histopathologic examination

as was seen in our case.

## **CORRESPONDENCE TO**

Yashwant Kumar Senior Resident The Pines, Near Ashiana Regency, Chhota Shimla (HP), India – 171002 E-mail: yashwantk74@yahoo.com Phone: +91-9996006515 Fax: 0091-172-2744401

## **References**

1. Cinberg JZ, Silver CE, Molnar JJ, Vogl SE. Cervical cysts: Cancer unless proven otherwise? *Laryngoscope* 1982; 92: 27-30.
2. Wallace MP, Betsill WL. Papillary carcinoma of the thyroid gland seen as lateral neck cyst. *Arch Otolaryngol* 1984; 110: 408-11.
3. Verge J, Guixa J, Alejo M, Basas C, Quer X, De Castro J, Autonell J, Serra J. Cervical cystic lymph node metastasis as first manifestation of occult papillary thyroid carcinoma: report of seven cases. *Head and Neck* 1999; 21:370-4.
4. Baim J, Walfish PG. Assessment of thyroid structure and function. *Otolaryngol Clin North Am* 1978; 11: 419-45.
5. Noyek AM, Greyson NG, Steinhardt MI, et al. Thyroid tumour imaging. *Acta Otolaryngol* 1983; 109: 205-24.
6. Miller JM, Hamburger JI, Kini S. Diagnosis of thyroid nodules: Use of fine needle aspiration and needle biopsy. *JAMA* 1979; 241: 481-4.
7. Hammer M, Wortsman J, Folse R. Cancer in cystic lesions of thyroid. *Arch Surg* 1982; 117: 1020-3.

**Author Information**

**Alka Bhatia, MD**

Senior Resident, Department of Histopathology, Postgraduate Institute of Medical Education and Research

**Yashwant Kumar, MD. DNB**

Senior Resident, Department of Histopathology, Postgraduate Institute of Medical Education and Research

**Ritambra Nada, MD**

Associate Professor, Department of Histopathology, Postgraduate Institute of Medical Education and Research