

# Operative Picture Of A Case Of Korner's Septum In Left Mastoid Cavity

S Vaidya

---

## Citation

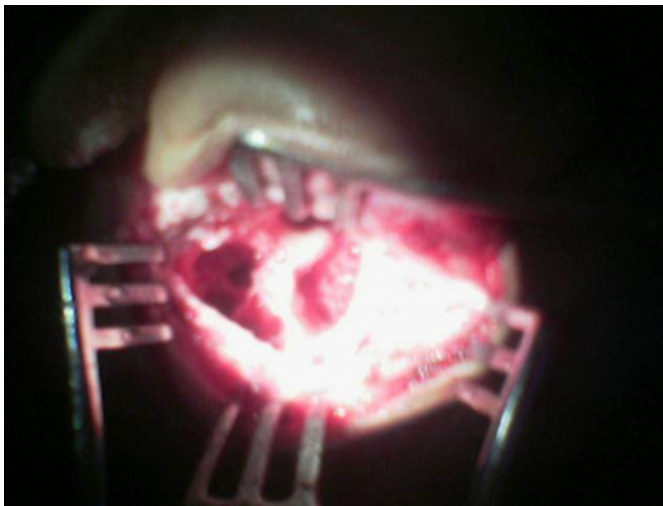
S Vaidya. *Operative Picture Of A Case Of Korner's Septum In Left Mastoid Cavity*. The Internet Journal of Otorhinolaryngology. 2006 Volume 6 Number 1.

## Abstract

## Figure 1

Figure 1: Operative Picture of a case of Korner 's Septum in Left Mastoid Cavity

## References



**Author Information**

**Sudhakar Vaidya, D. N. B.(ENT), D.L.O.**

Associate Professor, Dept. of Otorhinolaryngology, R D Gardi Medical college & Ujjain Charitable Hospital