

# Spontaneous Parapharyngeal Haemorrhage As A Complication Of Anticoagulation Therapy

S Basavaraj, J Sharp

## Citation

S Basavaraj, J Sharp. *Spontaneous Parapharyngeal Haemorrhage As A Complication Of Anticoagulation Therapy*. The Internet Journal of Otorhinolaryngology. 2001 Volume 1 Number 2.

## Abstract

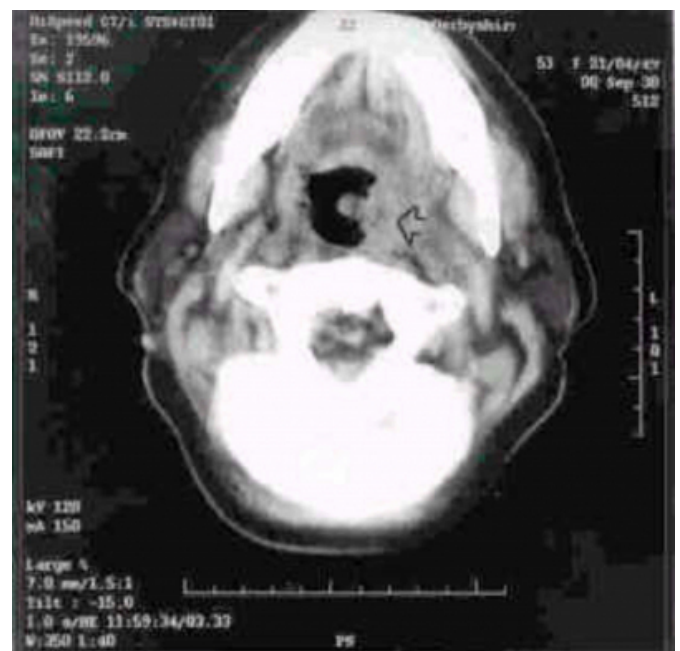Spontaneous haemorrhage into the parapharyngeal space is a rare complication of anticoagulant therapy. Two such cases, one with spontaneous resolution managed conservatively another with massive haemorrhage causing airway obstruction massive haemothorax requiring surgical intervention, are presented.

## CASE 1

A 51-year lady presented with sore throat and a left neck swelling. She was on warfarin (4 mg) following an aortic valve replacement. On admission clotting studies showed INR 4.7 KCCT >120s (control 28s). On examination there was a submucosal haematoma on the left lateral wall of the oropharynx, which precluded flexible laryngoscopy. A CT scan of the neck, demonstrated a haematoma extending from C-1 down to the level of the lower border of thyroid cartilage, in the parapharyngeal space (fig.1).

## Figure 1

Fig 1: Axial CT of the neck showing homogenous opacity in the left parapharyngeal space secondary to haemorrhage with mild displacement of the medial wall of the left parapharyngeal space.



After conservative management with vitamin K and fresh frozen plasma, the swelling gradually resolved. The patient was discharged 4 days post admission.

## CASE 2

A 72-year-old lady presented with a left-sided neck swelling and mild stridor after an episode of vomiting. A past history of hypertension, ischaemic heart disease, chronic renal failure and atrial fibrillation was noted. Current medication

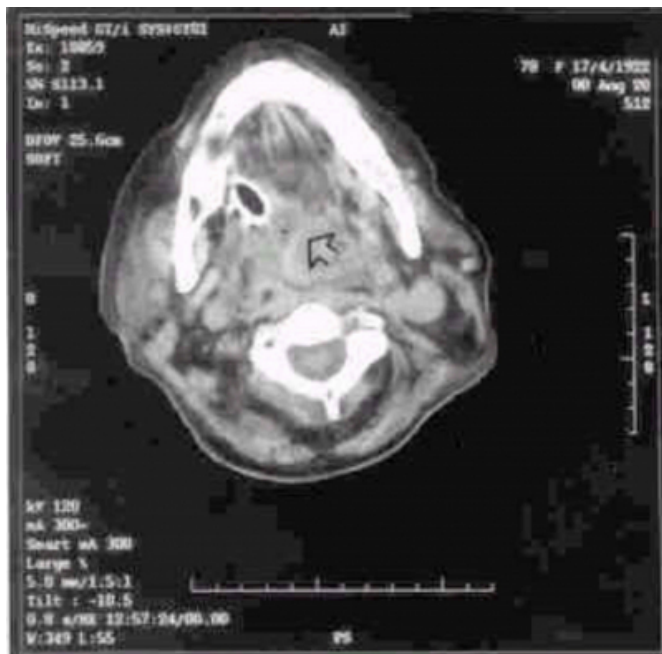
included warfarin (3.5mg).

Examination revealed a brownish coloured mass in the left lateral wall of the pharynx extending almost to midline, with diffuse swelling in the left side of the neck on external palpation. A diagnosis of parapharyngeal haemorrhage was made. Clotting studies on admission showed INR 2.8 and KCCT 27s (control 28s).

She was given vitamin K (10 mg) intramuscularly and two units of fresh frozen plasma to correct her coagulopathy. However she continued to bleed and as her airway was becoming severely compromised, her trachea was intubated under general anaesthesia. Upper aero-digestive endoscopy demonstrated submucosal haematoma involving the vallecula, left hemilarynx, posterior pharyngeal wall and both pyriform fosse. The right hemilarynx and the oesophagus were normal. CT scan of the neck and chest demonstrated haemorrhage into the left side of the neck tracking down into the posterior mediastinum and extending to the right side of the pleural cavity causing a massive right haemothorax (fig.2 and 3).

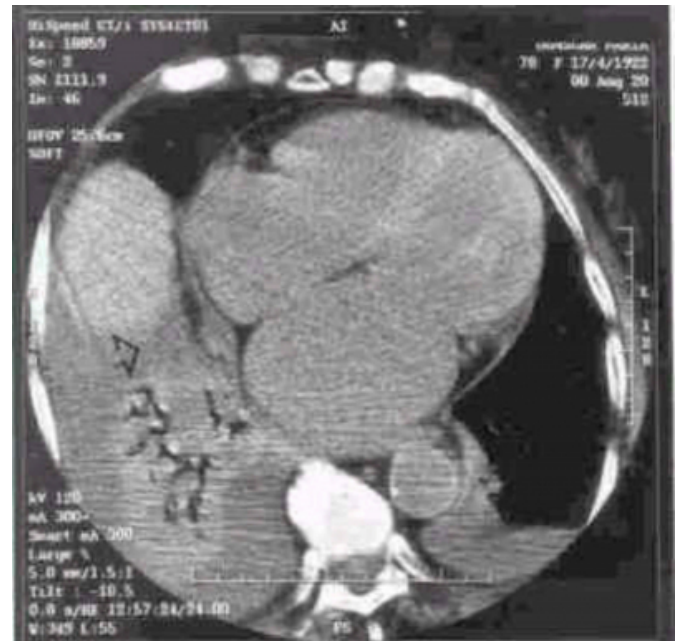
**Figure 2**

Fig 2: Axial CT scan of the neck showing left parapharyngeal haemorrhage extending into retropharyngeal space displacing the endotracheal tube to right and causing upper airway compromise.



**Figure 3**

Fig 3: Axial CT of the mid-chest showing homogenous opacity in the right pleural cavity secondary to massive haemothorax.



She subsequently underwent a formal tracheostomy and drainage of 1.5 litres of blood from the right haemothorax, recovery from this episode was slow, complicated by a chest infection. She died of a myocardial infarction 25 days post presentation.

**DISCUSSION**

Although rare, spontaneous parapharyngeal haemorrhage in patients on anticoagulant therapy of varying severity, has been reported <sup>1,2,3</sup>. In most of the cases when diagnosed early and managed promptly the prognosis is good, with or without surgical intervention, and the haematomas resolve completely. The commonest presentation is sore throat, hoarse voice and swelling in the oral cavity or neck following an episode of straining (coughing or vomiting). An examination may confirm the parapharyngeal swelling. Once diagnosed these patients need, not only prompt airway management and the reversal of anticoagulation with fresh frozen plasma or and with Vitamin K, but also close monitoring for further bleeding into the neck.

The anatomy of the neck potential spaces is well documented<sup>4</sup>. The continuation between these spaces and the mediastinum is well-recognised <sup>4</sup>, more commonly in connection with the spread of infections. Infections and haematomas anterior to the pre-tracheal fascia can spread to the superior and anterior mediastinum and infection

posterior to the pre-tracheal fascia and anterior to the pre-vertebral fascia can spread to the posterior mediastinum.

By presenting these two cases of parapharyngeal space haemorrhage complicating anticoagulation therapy, we wish to highlight the fact that significant bleeding can occur in patients with therapeutic INR levels and ensure that the diagnosis of haemorrhage is considered, when patients with oropharyngeal swelling are investigated. As illustrated by the second case, securing the airway and correction of the coagulopathy, may not be all that is required in the management of extreme cases.

### **CORRESPONDENCE TO**

S. Basavaraj 31 Remburn Gardens Lakin Road Warwick CV34 5BW United Kingdom. Phone: +44 (0)1926 495321

Ext: 6876 E-mail: sbbki@yahoo.com

### **References**

1. Boster SR, Bergin JJ. Upper airway obstruction complicating warfarin therapy - with a note on reversal of warfarin toxicity. *Annals Emergency Medicine*. 1983 Nov; 12(11): 711-5.
2. O'Leary TG, Kotecha B, Rothera M.P: Upper airway obstruction secondary to anticoagulant induced haemorrhage necessitating a tracheostomy. *Irish Medical Journal*. 1990, Dec' vol-83(4): 151.
3. Rosenbaum L, Thurman P, Krantz SB. Upper airway obstruction as a complication of oral anticoagulation therapy. *Archives Internal Medicine*. 1979 Oct; 139(10): 1151-3.
4. Last RJ., *Anatomy: Regional and Applied*. 09 Ed; 423-4 Edinburgh Churchill Livingstone.
5. Lepore ML. Upper airway obstruction induced by warfarin sodium. *Archives Otolaryngol*. 1976 Aug; 102(8): 505-6.

**Author Information**

**S. Basavaraj, MRCSEd**

Specialist Registrar in ENT, Crosshouse Hospital

**J. F. Sharp, FRCSEd**

Consultant ENT and Head and Neck Surgeon, Derbyshire Royal Infirmary