

Simple maneuver to place the skin incision for inguinal hernia

N Naguib

Citation

N Naguib. *Simple maneuver to place the skin incision for inguinal hernia*. The Internet Journal of Surgery. 2008 Volume 21 Number 2.

Abstract

I describe a simple maneuver to place the skin incision for the inguinal hernia repair. All the open operative techniques for inguinal hernia repair use a transversely oriented slight curvilinear skin incision of 6-8cm positioned one to two fingerbreadths above the inguinal ligament¹. Classically the incision is made between the anterior superior iliac spine and the pubic tubercle². Technically it may be difficult to identify these two landmarks. Hence, the exposure can be very difficult especially in obese patients³.

TECHNIQUE

Simply, the external inguinal ring can be identified through the skin by the external ring test which was previously used to differentiate between the diagnosis of the direct and indirect hernia, Fig. 1. The examining finger is introduced in the inguinal canal to delineate it and the incision is placed directly on the inguinal canal starting from the site of the external inguinal ring, Fig. 2. Dissecting the subcutaneous tissues directly goes down to the external oblique fibers, Fig. 3.

Figure 1

Fig. 1: Identification of the external ring through the skin.

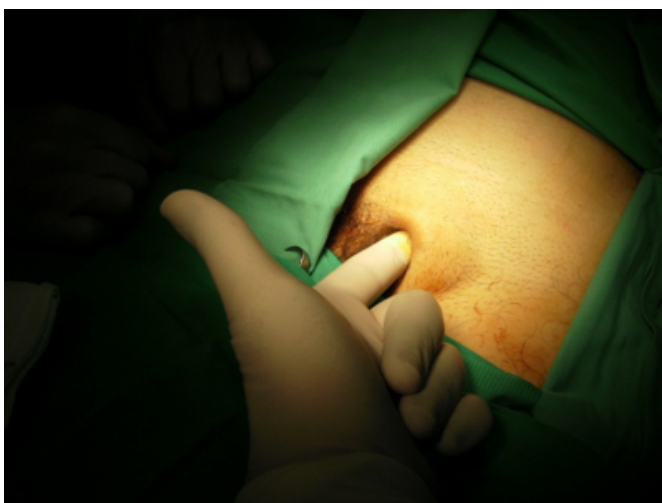


Figure 2

Fig. 2: The incision is placed directly over the inguinal canal.

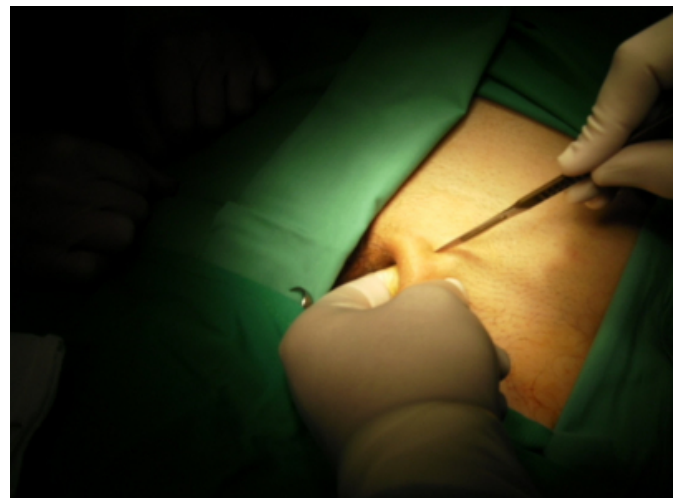
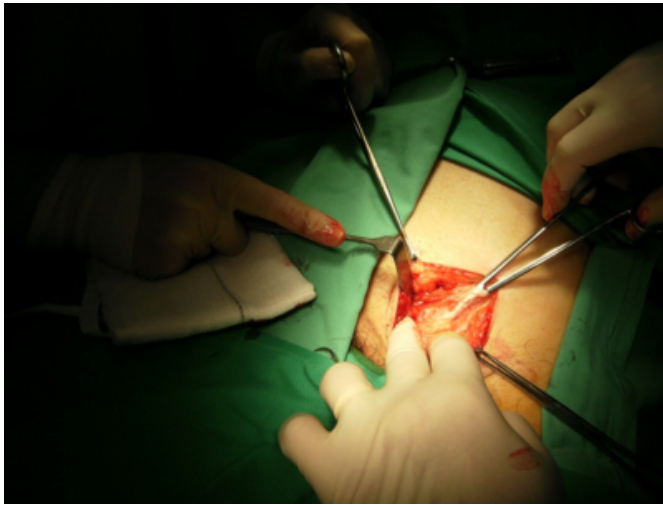


Figure 3

Fig. 3: The dissection deepened leading directly to the external oblique fibers (opened) at the level of the external ring.



References

1. Maingot R, Zinner MJ and Ashley SW. Maingot's abdominal operations, 11th Edition. Published by McGraw-Hill Professional, 2007; 108.
2. Schwartz SI, Brunickardi FC and Andersen DK. Schwartz's Manual of Surgery, 8th edition. Published by McGraw-Hill Professional, 2006; 930.
3. Morrey MC, Relevant Surgical Exposures: Relevant Surgical Exposures, illustrated edition. Published by Lippincott Williams & Wilkins, 2007; 129.

Author Information

NN Naguib

Department of Surgery, Prince Charles Hospital